



Expression of p53 is associated with microbial acetaldehyde production in oralsquamous cell carcinoma

Emilia Marttila, PhD, MD, DDS,^a Peter Rusanen, DDS,^b Johanna Uittamo, PhD, MD, DDS,^{a,c}
Mikko Salaspuro, PhD, MD,^c Riina Rautemaa-Richardson, PhD, DDS,^{d,e} and Tuula Salo, PhD, DDS^{a,f,g}

Objectives. The objective of this study was to investigate the association between p53 expression and microbial acetaldehyde production in patients with oral squamous cell carcinoma (OSCC).

Study Design. Oral mucosal biopsies from 22 patients with OSCC and 24 healthy controls (HCs) were collected. p53 expression was analyzed by immunohistochemistry. Microbial samples were collected from the mucosa and microbial acetaldehyde production from ethanol was measured by gas chromatography.

Results. The majority of all OSCC (77%) and HC samples (67%) produced mutagenic levels of acetaldehyde ($>100 \mu\text{M}$). A significant positive correlation between microbial acetaldehyde production and p53 expression levels in OSCC samples was seen in the intermediate and superficial layers of the epithelium of the infiltrative zone ($P = .0005$ and $P = .0004$, respectively) and in the superficial layer of the healthy appearing mucosa next to the tumor ($P = .0391$). There was no significant correlation between acetaldehyde levels and p53 expression in HC samples.

Conclusions. Our results show an association between microbial acetaldehyde production and immunostaining of p53 in OSCC samples. (Oral Surg Oral Med Oral Pathol Oral Radiol 2021;131:527–533)

Several studies have linked microbial production of acetaldehyde (ACH) to cancers of the digestive tract, including oral squamous cell carcinoma (OSCC).^{1,14,25} Although alcohol consumption is a known risk factor for OSCC, ethanol in itself is not carcinogenic. ACH is produced by the oxidation of ethanol by microbes in the gastrointestinal tract. Several studies have confirmed that oral microbes are able to produce mutagenic levels of ACH in vitro.^{10,11,22} Increased salivary microbial ACH production is associated with smoking and alcohol consumption, and significant amounts of ACH can be detected in the saliva after alcohol ingestion and after smoking.^{16,20} The International Agency for Research on Cancer (IARC) classified ACH as carcinogenic in humans and carcinogenic concentrations have been shown to be as low

as $100 \mu\text{M}$.^{6,25} ACH is a direct chemical carcinogen that binds to DNA and has been shown to produce DNA adducts and cross-linking while interfering with the synthesis and repair of DNA.^{26,27}

The tumor suppressor protein p53 is a transcription factor that is associated with cell cycle control and apoptosis and has a crucial role in the preservation of genetic stability and prevention of cancer.^{12,21} In response to various cellular stresses, such as DNA damage or the presence of oncogenes, virus infection, and hypoxia, p53 translocates into the nucleus where it binds to specific DNA sequences. In the nucleus, p53 regulates transcription of genes involved in many functions, such as DNA repair. When damage is beyond repair, p53 triggers programmed cell death, or apoptosis.^{5,13,19,24} It is thought that wild-type p53-mediated apoptosis is the primary cause of tumor suppression.

In the absence of stress signals, wild-type p53 protein can be difficult to detect in tissue by immunohistochemistry because of its short half-life.⁵ p53 is tightly regulated between its transcription and degradation.¹ To remain in the tissue for a longer time and to be detectable by immunohistochemistry, p53 must be stabilized by mutation.^{5,23} p53 staining is more intense

^aDepartment of Oral and Maxillofacial Surgery, Helsinki University Hospital and University of Helsinki, Helsinki, Finland.

^bDepartment of Bacteriology and Immunology, Haartman Institute, University of Helsinki, Helsinki, Finland.

^cResearch Unit on Acetaldehyde and Cancer, University of Helsinki, Helsinki, Finland.

^dDivision of Infection, Immunity and Respiratory Medicine, School of Biological Sciences, NIHR Manchester Biomedical Research Centre (BRC) at the Manchester Academic Health Science Centre, The University of Manchester, Manchester, UK.

^eManchester University NHS Foundation Trust, Wythenshawe Hospital, Manchester, UK.

^fHUSLAB, Department of Pathology, Helsinki University Central Hospital, University of Helsinki, Helsinki, Finland.

^gDepartment of Diagnostics and Oral Medicine, Institute of Dentistry, University of Oulu, Oulu, and University of Helsinki, Helsinki, Finland.

Received for publication Jan 20, 2020; returned for revision Sep 9, 2020; accepted for publication Nov 25, 2020.

© 2020 Elsevier Inc. All rights reserved.

2212-4403/\$-see front matter

<https://doi.org/10.1016/j.oooo.2020.11.015>

Statement of Clinical Relevance

The oral microbiome is capable of producing carcinogenic amounts of acetaldehyde. Patients with oral carcinoma with high acetaldehyde production show significantly stronger staining of tumor suppressor protein p53 indicating a mutation in *TP53* encoding p53. This highlights the importance of good oral hygiene.

in oral lichenoid disease compared to healthy oral mucosa, especially in the basal layer of the epithelium.¹⁸ Detection of p53 protein by immunohistochemistry indicates the presence of mutations in *TP53*. ACH has been shown to cause mutations in the *TP53* gene.⁸

The aim of this study was to explore p53 expression in different epithelial layers in OSCC and to investigate the association of p53 expression and ACH production from ethanol by microbes isolated from the tumor site.

MATERIALS AND METHODS

Patients

A total of 46 patients were enrolled in this study; 22 were patients newly diagnosed with OSCC and 24 were healthy controls (HCs) treated at the Department of Oral and Maxillofacial Surgery, Helsinki University Hospital during 2007 to 2011. HCs were patients referred to the same department for operative wisdom tooth extraction and who had no evident mucosal lesions in the oral cavity. All participating patients signed an informed consent before inclusion in the study. Patients completed a modified World Health Organization Alcohol Use Disorders Identification Test including open- and closed-ended questions about their drinking and smoking habits. Patients who had received antimicrobial therapy (i.e., antibiotics, antifungals, or antiviral agents) within the past 7 days and those diagnosed with HIV or hepatitis virus infection were excluded. The study was approved by the Ethics Committee of Helsinki University Hospital (Ethical Approval Number 126/E6/07 25.4.2007). The study was performed in accordance with the Declaration of Helsinki.

Collection of histopathological samples

Full-thickness biopsies, including epithelial and stromal tissue, were collected from patients with OSCC from the site of the tumor according to normal clinical procedures. Biopsy samples from HCs were collected from the uninflamed, healthy-appearing buccal mucosa near the incision site immediately after surgical extraction of a retained wisdom tooth. The samples were fixed in 10% buffered formalin and embedded in paraffin.

Collection of microbial samples

Microbial samples for the ACH measurement and detection of *Candida* were collected using the filter paper sampling method as described in Rusanen et al.¹⁷ The samples were taken from the oral mucosa using a hydrophilic mixed cellulose ester MF-Millipore membrane filter (GSWP01300; Millipore Inc., Billerica, MA; pore size 0.22 μ m, B 13 μ m). The filter paper was placed gently on the oral mucosa for 30 s with the glossy side placed against the mucosa. The

filter paper was then placed in a sterile test tube containing 5 mL of sterile saline solution. The samples were immediately taken to the laboratory at the Department of Bacteriology and Immunology, Haartman Institute, University of Helsinki. All samples were cultured within 1 h of collection. For the ACH analyses, each side of the filter paper was placed on an FAA plate (Fastidious Anaerobe agar (LAB-M LAB 90) supplemented with 5% horse blood) for 30 s and plates were evenly streaked and incubated under anaerobic conditions at 37°C for 7 days¹⁰.

Immunohistochemical staining

Tissue sections of 4 μ m thickness were prepared from the paraffin-embedded samples and applied to glass slides. The sections were deparaffined in xylene followed by rehydration in graded ethanol. To expose the antigenic determinants after formalin fixation and paraffin embedding, the sections were incubated in pepsin for 30 min at room temperature. Endogenous peroxidase activity was quenched in the sections by incubating in hydrogen peroxidase in methanol. For the immunohistochemical staining of p53, the tissue sections were buffered in Tris-EDTA, pH 9, heated 15 min in a microwave oven, and incubated for 30 min at room temperature with an optimally diluted p53 antibody. After the primary antibody incubation, the tissue sections were incubated separately with Dako REAL EnVision kit using Dako automated immunostaining instruments. The reactions were visualized by Dako REAL DAB+ Chromogen also included in the kit (catalogue number K5007, Dako Glostrup Denmark). The dilution of p53 monoclonal mouse anti-human p53 (catalogue number, M7001; Dako Glostrup Denmark) antibody was 1:600. Tissue samples from chronic periodontitis were used as positive controls.²⁸ Negative controls were obtained by omission of the primary antibody.

Evaluation of immunostaining

The expression of p53 was analyzed using a light microscope (Nikon Eclipse 80i). Results were scored semiquantitatively and photographed using an attached camera (Nikon DS-Fi1). All samples and stainings were analyzed and scored by 3 of the authors (TS, EM, and PR); these authors were blinded to clinical data. The staining of the basement membrane zone and of the cells in the basal, intermediate, and superficial layers of the epithelium was scored on a 4-point scale as follows: 0 = no staining, 1 = staining of approximately 1% to 33% of cells, 2 = staining of 34% to 66% of cells, and 3 = staining of 67% to 100% of cells. Both the infiltrative zone of the cancer and the healthy-appearing adjacent mucosa next to the carcinoma were scored.

Measurement of acetaldehyde production

Microbial colonies on the FAA plate were carefully scraped and washed off with 3 mL of sterile saline solution. Aliquots of 400 mL of the suspension were transferred into parallel gas chromatograph vials and 50 mL of phosphate-buffered saline containing ethanol (final concentration 22 mM) was added. The vials were immediately sealed. Samples were incubated for 60 min at 37°C and the reactions were stopped by injecting 50 mL of 6 M perchloric acid through the rubber septum of the vial. Control vials in which perchloric acid was added before ethanol were used to measure background ACH and ethanol levels. Three parallel samples were processed and the mean values were used for statistical analysis. The formed ACH levels were measured by gas chromatography (Perkin Elmer Headspace Sampler HS 40 XL, Perkin Elmer Autosystem Gas Chromatograph equipped with Ionization Detector FID, Perkin Elmer, Waltham, MA).⁶

Statistical analysis

Data were analyzed using GraphPad Prism version 5.00 (GraphPad Inc., San Diego, CA). The 2-tailed Mann-Whitney *U* test and Spearman's rho (*r_s*) were used for analyses of correlations. The Wilcoxon signed-rank test was used to compare the differences between the different layers of samples and paired observations from samples. *P* values <.05 were considered statistically significant.

RESULTS

Patients

Patient demographic characteristics are shown in Table I. The anatomic sites of the carcinoma were the tongue (*n* = 9), floor of the mouth (*n* = 4), mandibular gingiva (*n* = 5), maxillary gingival (*n* = 3), and soft palate/oropharynx (*n* = 1). Of the 22 patients with OSCC, 8 were female (mean age = 65.0 years; range, 52-85 years) and 14 were male (mean age = 63.9 years; range, 46-80 years). The mean age of all patients with OSCC was 64.3 years (range, 46-85). Of the HCs, 17 were female (mean age = 32.2 years; range, 19-56 years) and 7 were male (mean age = 25.1 years; range, 18-36 years). The mean age of all HCs was 30.1 years (range, 18-56). Five patients with OSCC (23%) and 3 HCs (13%) exceeded World Health Organization levels for harmful alcohol consumption (288 g alcohol per week for men and 192 g per week for women). Three patients with OSCC reported daily alcohol use, whereas none of the HCs consumed alcohol daily. A total of 36% patients with OSCC and 37% of HCs were smokers.

p53 expression

p53 staining could not be detected in the superficial epithelial layers of the HC samples, whereas 36% of

Table I. Patient demographic characteristics and smoking and drinking habits*

	OSCC	HC	<i>P</i> value
Total number	22	24	
Female:male	8:14	17:7	
Age (range), years	64.3 (46-85)	30.1 (19-56)	<.0001
Smokers	8 (36%)	9 (38%)	1.00
Nondrinkers	4 (18%)	2 (8%)	.40
Daily drinkers	3 (14%)	0	.09
Heavy drinkers [†]	5 (23%)	3 (13%)	.44
Nonresponders	1 (5%)	1 (4%)	1.00
Location of tumor			
Tongue	9	N/A	
Floor of the mouth	4	N/A	
Mandibular gingiva	5	N/A	
Maxillary gingiva	3	N/A	
Soft palate/oropharynx	1	N/A	

OSCC, oral squamous cell carcinoma; HC, healthy control; N/A, not applicable.

*One patient with OSCC and 1 HC declined to complete the questionnaires. Percentages of smokers and drinkers given all responders in each group.

[†]Exceeds World Health Organization levels for harmful alcohol consumption (288 g alcohol per week for men and 192 g per week for women).

the OSCC samples showed staining of the superficial adjacent mucosa and 82% of the infiltrative zone. There was no significant difference in p53 staining intensity in any of the epithelial layers of the infiltrative zone and the healthy-appearing adjacent mucosa among the OSCC samples. The staining intensity of p53 was significantly greater in the OSCC samples than in HC samples in the basal and intermediate layers of epithelium (*P* < .0001 and *P* < .0001, respectively; Figure 1).

Fig. 2. p53 staining was significantly stronger in the infiltrative zone of samples of patients with OSCC who smoked compared to nonsmokers (Fig. 2). This was evident in all epithelial layers (basal infiltrative layer, *P* = .0498; intermediate, *P* = .0482; superficial, *P* = .0386). However, there was no significant difference in the p53 status of smokers in the healthy-appearing adjacent mucosa or in the epithelial layers of HCs. There was no significant difference in p53 staining in heavy alcohol drinkers or daily drinkers. No significant differences were seen in the staining intensity of p53 in samples collected from alcohol consumers and nondrinkers in either patient group.

Microbial acetaldehyde production

Overall, 77% of all samples in the OSCC group and 67% of the samples in the HC group produced mutagenic levels of ACH (>100 μM). The mean level of ACH produced by microbes isolated from the oral carcinoma lesions was 158 μM (range, 13-470 μM) and it was 154 μM (range, 23-1000 μM) in the HC samples.

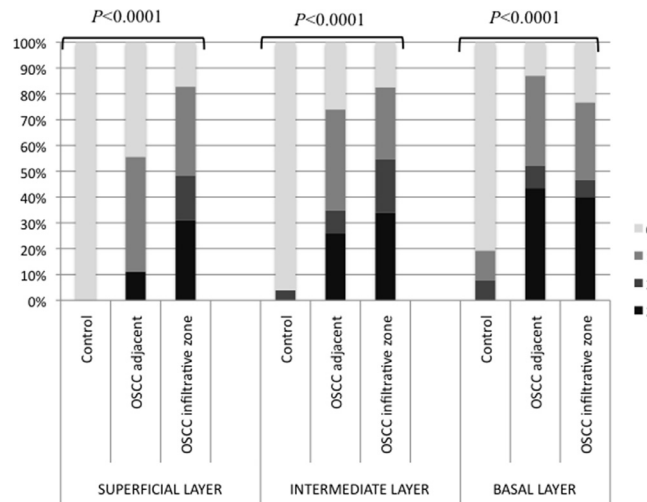


Fig. 1. Staining percentages of p53 in healthy control patients ($n = 22$) and patients with oral cavity squamous cell carcinoma ($n = 24$) in 3 different epithelial layers (superficial, intermediate, and basal layers). 0 = no staining, 1 = staining of approximately 1% to 33% of cells, 2 = staining of 34% to 66% of cells, 3 = staining of 67% to 100% of cells.

There was no statistically significant difference between the levels of ACH produced in the 2 patient groups. All samples (100%) from smokers and heavy alcohol users produced mutagenic levels of ACH ($> 100 \mu\text{M}$), whereas the proportions of mutagenic levels were 62% in nonsmoker samples and 69% in non-heavy drinkers. However, the differences were not statistically significant.

Association between p53 expression and microbial acetaldehyde production

There was a significant positive correlation between microbial ACH production and the p53 expression level in both the intermediate and superficial layers of the epithelium in the infiltrative zone of the OSCC samples ($r_s = 0.69$ [0.36-0.87], $P = .0005$; $r_s = 0.70$ [0.37-0.87]; $P = .0004$, respectively). There was also a positive correlation between ACH production and p53 expression in the superficial layer of the healthy-appearing adjacent mucosa in the carcinoma samples ($r_s = 0.56$ [0.018-0.84]; $P = .0391$). There was no significant correlation between ACH levels and p53 expression in HC samples in any epithelial layers.

DISCUSSION

In the present study, staining intensity of p53 was significantly increased in OSCC samples compared to HC samples in all suprabasal layers of the epithelium. Staining for p53 was not detected in the superficial epithelial layers of HC samples, whereas the majority of the OSCC samples showed staining of the superficial adjacent mucosa and infiltrative zone. This suggests that because of its short half-life, wild-type p53 protein in HC samples is restricted to the basal layer and can be difficult to detect in healthy tissue by

immunohistochemistry.⁵ Detection of p53 protein by immunohistochemistry indicates the presence of mutations in *TP53*. p53 expression in the suprabasal level can be detected in potentially premalignant lesions.³ p53 staining is more intense in oral lichenoid disease compared to healthy oral mucosa, especially in the basal layer of the epithelium.^{4,18} Surprising, the staining intensity of p53 was markedly increased in both the infiltrative zone and the healthy-appearing adjacent mucosa of the OSCC samples. This supports findings from previous studies in which nonmalignant mucosal areas immediately adjacent to OSCCs expressed p53 above the basal layer, indicating that these areas are precursors of the carcinoma⁴.

The majority of microbes cultured from both OSCC and HC samples in this study produced levels of ACH that clearly exceeded mutagenic levels ($> 100 \mu\text{M}$). ACH exposure has been shown to cause mutations in the *TP53* gene that impair p53 functionality at treatment concentrations as low as $100 \mu\text{M}$.⁸ The most frequent mutations caused by ACH in *TP53* are G > A transitions, G > T transversions, and A > G transitions.^{8,15} In the present study, there was a significant association between microbial ACH production and p53 expression levels in OSCC samples but not in HC samples. It is well established that carcinogenesis is a multifactorial cascade affected by several intrinsic and extrinsic factors leading to loss of cell cycle control and finally to tumor progression. The transformation of healthy epithelium into cancer is based on a complex series of genetic mutations, resulting in loss of cell control mechanisms (such as apoptosis) and consequently alterations in cell differentiation.² p53 contributes to cell cycle control, apoptosis, and preservation of genetic stability and is one of the most commonly

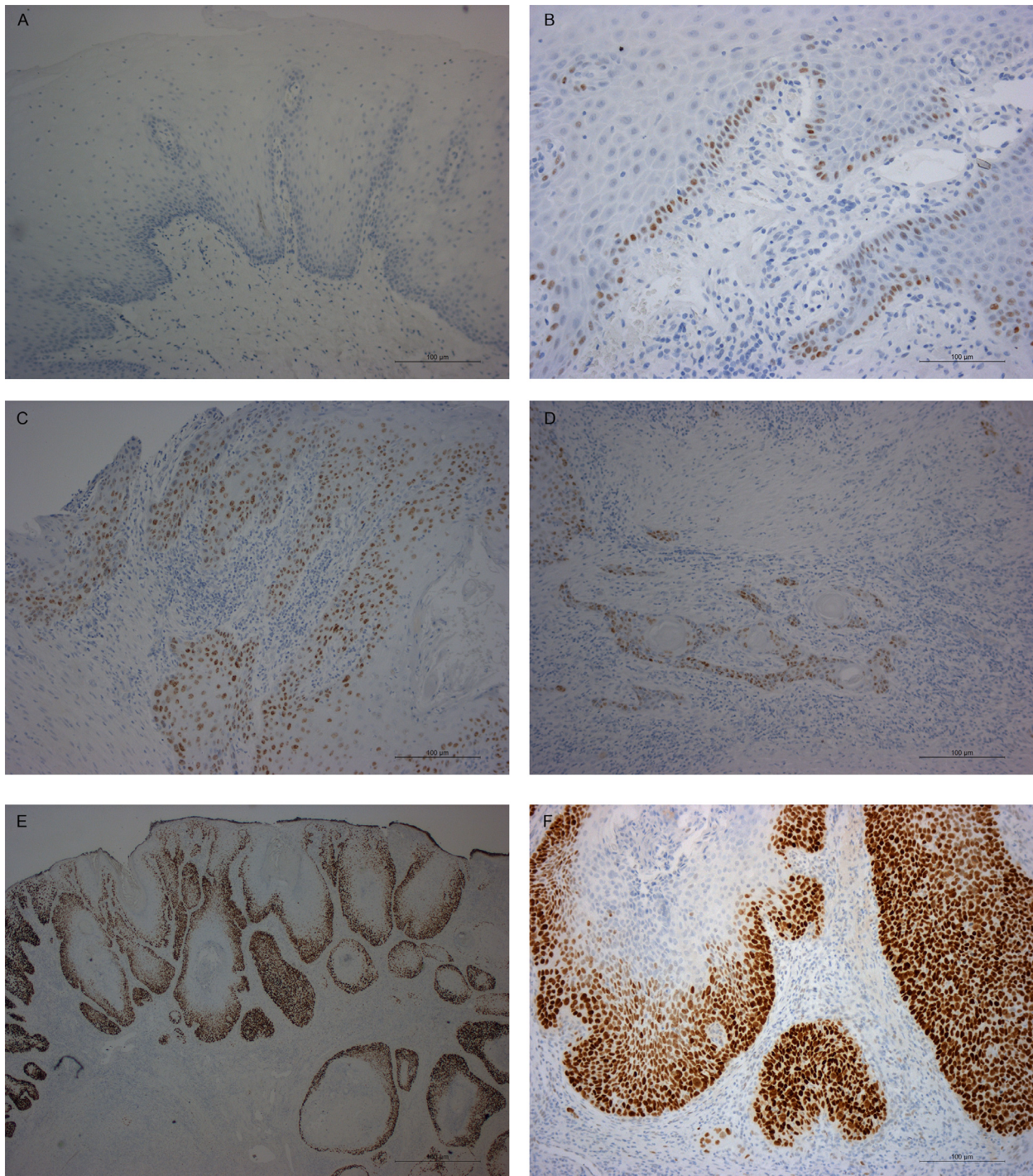


Fig. 2. Staining intensities for p53 in healthy control (HC) and oral squamous cell carcinoma (OSCC) samples. (A) p53 staining could not be detected in the superficial epithelial layers of the HC samples (10 ×). (B) In the deeper layers of HC samples with inflammation some staining of p53 could be detected (20 ×). (C) Staining of p53 was more significant in OSCC samples in the adjacent mucosa (10 ×) as well as the (D) infiltration zone. (E) and (F) In samples from patients with OSCC who smoked, the staining of p53 was high in the infiltrative zone.

mutated genes in several cancers.¹² Several mutations and mutational types have been identified in *TP53*. In contrast to other tumor suppressor genes, the vast majority of *TP53* mutations are missense rather than

nonsense or frameshift mutations.⁹ The primary regulator of p53 protein stability is MDM2, which inhibits transcriptional activity, nuclear localization, and protein stability. Several mutations in MDM2, as well as

alternative splicing of mRNA precursors, have been identified.⁷ Missense mutations in *TP53* are associated with malignant cell proliferation and increased invasion.¹⁶ Our findings indicate a connection between oral microbial ACH and p53.

In samples from patients with OSCC, there was a significant association between p53 staining and smoking habits in the infiltrative layer. However, no such association was seen in samples from HCs. Additionally, all samples from smokers and heavy drinkers produced mutagenic levels of ACH. The proportions of samples producing mutagenic levels of ACH were lower in nonsmokers and non-heavy drinkers. However, the difference was not statistically significant. This may partly be due to the small number of patients, because the total number of heavy drinkers was 8 and the number of smokers was 13. Smoking is one of the main risk factors for OSCC and smoking increases salivary ACH levels markedly. Our previous study revealed a significant association between microbial ACH production and smoking.¹⁰ Compared to nonsmokers, active smokers have an additional 200 to 400 μM increase in ACH concentration in saliva that persists for as long as smoking continues.^{6,20} Associations between p53 immunostaining and smoking habits have been previously reported.⁴ Repeated smoking and ACH peaks could lead to mutation of *TP53* and increased p53 immunostaining.

CONCLUSION

Our results show an association with ACH production from ethanol by microbes cultured from OSCC patients and immunostaining of p53 in the tumor site and in the adjacent healthy-appearing mucosa.

REFERENCES

- Almangush A, Heikkinen I, Mäkitie AA, et al. Prognostic biomarkers for oral tongue squamous cell carcinoma: a systematic review and meta-analysis. *Br J Cancer*. 2017;117:856-866.
- Coussens LM, Werb Z. Inflammation and cancer. *Nature*. 2002;420:860-867.
- Cruz IB, Snijders PJ, Meijer CJ, et al. p53 expression above the basal cell layer in oral mucosa is an early event of malignant transformation and has predictive value for developing oral squamous cell carcinoma. *J Pathol*. 1998;184:360-368.
- Cruz I, Snijders PJ, Van Houten V, et al. Specific p53 immunostaining patterns are associated with smoking habits in patients with oral squamous cell carcinomas. *J Clin Pathol*. 2002;55:834-840.
- Ebrahimi M, Nylander K, van der Waal I. Oral lichen planus and the p53 family: what do we know? *J Oral Pathol Med*. 2011;40:281-285.
- Homann N, Jousimies-Somer H, Jokelainen K, et al. High acetaldehyde levels in saliva after ethanol consumption: a microbiological approach to oral cavity cancer. *Carcinogenesis*. 2000;21:663-668.
- Inoue K, Fry EA. Aberrant splicing of the DMP1-ARF-MDM2-p53 pathway in cancer. *Int J Cancer*. 2016;139:33-41.
- Paget V, Lechevrel M, Sichel F. Acetaldehyde-induced mutational pattern in the tumour suppressor gene TP53 analysed by use of a functional assay, the FASAY (functional analysis of separated alleles in yeast). *Mutat Res*. 2008;652:12-19.
- Makarov EM, Shtam TA, Kovalev RA, et al. The rare nonsense mutation in p53 triggers alternative splicing to produce a protein capable of inducing apoptosis. *PLoS One*. 2017;12:e0185126.
- Marttila E, Uittamo J, Rusanen P, et al. Acetaldehyde production and microbial colonization in oral squamous cell carcinoma and oral lichenoid disease. *Oral Surg Oral Med Oral Pathol Oral Radiol*. 2013;116:61-68.
- Marttila E, Bowyer P, Uittamo J, et al. Fermentative 2-carbon metabolism produces carcinogenic levels of acetaldehyde in *Candida albicans*. *Mol Oral Microbiol*. 2013;28:281-291.
- Massano J, Regateiro FS, Januário G, et al. Oral squamous cell carcinoma: review of prognostic and predictive factors. *Oral Surg Oral Med Oral Pathol Oral Radiol Endod*. 2006;102:67-76.
- Menendez D, Shatz M, Resnick MA. Interactions between the tumor suppressor p53 and immune responses. *Curr Opin Oncol*. 2013;25:85-92.
- Nieminen MT, Salaspuro M. Local acetaldehyde—an essential role in alcohol-related upper gastrointestinal tract carcinogenesis. *Cancers (Basel)*. 2018;10.
- Noori P, Hou SM. Mutational spectrum induced by acetaldehyde in the HPRT gene of human T lymphocytes resembles that in the p53 gene of esophageal cancers. *Carcinogenesis*. 2001;22:1825-1830.
- Roszkowska KA, Gizinski S, Sady M, et al. Gain-of-function mutations in p53 in cancer invasiveness and metastasis. *Int J Mol Sci*. 2020;21:1334.
- Rusanen P, Siikala E, Uittamo J, et al. A novel method for sampling the microbiota from the oral mucosa. *Clin Oral Investig*. 2009;13:243-246.
- Rusanen P, Marttila E, Uittamo J, et al. TLR1-10, NF- κ B and p53 expression is increased in oral lichenoid disease. *PLoS One*. 2017;12:e0181361.
- Römer L, Klein C, Dehner A, et al. p53—a natural cancer killer: Structural insights and therapeutic concepts. *Angew Chem Int Ed Engl*. 2006;45:6440-6460.
- Salaspuro V, Salaspuro M. Synergistic effect of alcohol drinking and smoking on in vivo acetaldehyde concentration in saliva. *Int J Cancer*. 2004;111:480-483.
- Surget S, Khoury MP, Bourdon JC. Uncovering the role of p53 splice variants in human malignancy: a clinical perspective. *Onco Targets Ther*. 2013;7:57-68.
- Uittamo J, Siikala E, Kaihovaara P, et al. Chronic candidosis and oral cancer in APECED patients: production of carcinogenic acetaldehyde from glucose and ethanol by *Candida albicans*. *Int J Cancer*. 2009;124:754-756.
- van Houten VM, Tabor MP, van den Brekel MW, et al. Mutated p53 as a molecular marker for the diagnosis of head and neck cancer. *J Pathol*. 2002;198:476-486.
- Warnakulasuriya KAAS, Tavassoli M, Johnson NW. Relationship of p53 overexpression to other cell cycle regulatory proteins in oral squamous cell carcinoma. *J Oral Pathol Med*. 1998;27:376-381.
- Seitz G, Stickel R. Molecular mechanisms of alcohol-mediated carcinogenesis. *Nat Rev Cancer*. 2007;7(599-612).

26. Pöschl, Seitz. Alcohol and cancer. *Alcohol Alcohol*. 2004;39:155-165.
27. Timmons, Nwankwo, Domann. Acetaldehyde activates Jun/AP-1 expression and DNA binding activity in human oral keratinocytes.. *Oral Oncol*. 2002;38:281-290.
28. Beklen, Hukkanen, Richardson, et al. Immunohistochemical localization of Toll-like receptors 1-10 in periodontitis.. *Oral Microbiol Immunol*. 2008;23:425-431.

Reprint request:

Dr. Emilia Marttila
Department of Oral and Maxillofacial Surgery
Helsinki University Hospital
PO Box 220
FI-00029 Helsinki
Finland
Emilia.marttila@helsinki.fi