



Carcinoma mistaken for periodontal disease: importance of careful consideration of clinical and radiographic findings

Mohanad Al-Sabbagh, DDS, MS,^a Ahmad Hawasli, DDS, MSc,^b Rachad Kudsi, BDS,^a Galal Omami, BDS, MSc, MDentSc, FRCD(C),^c Joel B. Epstein, DMD, MSD,^{d,e} and Craig S. Miller, DMD, MS^c

(Oral Surg Oral Med Oral Pathol Oral Radiol 2021;131:e151–e156)

Dentists must be vigilant in the search for signs and symptoms of oral cancer in their patients. Failure to recognize these features can be serious; however, the low prevalence of oral cancer makes this encounter infrequent for most dentists.¹ Because the average annual incidence of oral cancer in the United States is estimated to be 12 per 100,000 population,² every dentist is open to the probability of encountering patients with this disease.

A complicating factor is that gingival carcinoma may mimic a periodontal inflammatory lesion, and this may lead to a delay in diagnosis and treatment. Diagnostic delay (>1.5 months) and diagnosis at advanced stages (T4 primary tumor) have been reported in 25% and 67% of gingival cancers, respectively.³ Moreover, late diagnosis has been shown to impact approaches to the treatment and prognosis of patients with oral cancer.⁴

We report 2 cases of gingival squamous cell carcinoma masquerading as periodontal disease. This occurrence has been documented rarely in the literature.⁵⁻⁸ The findings reported in these 2 new cases emphasize recognition of the clinical and radiographic features and the importance of a thorough evaluation and biopsy to rule out the possibility of unexpected disease in patients whose conditions are resistant to standard periodontal therapy.

CASE PRESENTATION

Case 1

A 64-year-old woman was referred to a periodontist for evaluation of persistent deep probing depths on the palatal aspect of the maxillary left central and lateral

incisors. The patient reported continuous “mild discomfort” in the area but did not report taking any pain medication. The patient’s medical history was significant for hypertension, cardiomyopathy, and a familial history of breast cancer. The patient was a nonsmoker and did not consume alcohol. Her past surgical history included thyroidectomy, hysterectomy, and gastric bypass. Her medications included pantoprazole, carvedilol, simvastatin, spironolactone, liothyronine plus levothyroxine, multivitamins, and low-dose aspirin.

Six months before her visit to the periodontist, her general dentist had referred her to an endodontist for evaluation. That visit revealed previous adequate endodontic therapy on the right lateral and left central incisors and normal vitality of the right central and left lateral incisors. There was no tenderness on palpation or percussion. A baseline periapical radiograph showed mild interproximal bone loss around the left central and lateral incisors without significant change in the periapical bone (Figure 1A).

Clinical examination revealed 8- to 9-mm probing depths and gingival inflammation on the palatal surface of the left central and lateral incisors. The central incisor was slightly supererupted and inclined facially, and there was 3-4 mm of palatal gingival recession. The lateral incisor responded normally to pulp testing. The maxillary anterior teeth demonstrated fremitus and Miller class I mobility. A periapical radiograph revealed ill-defined bone loss around the left central and lateral incisors (Figure 1B). In addition, recurrent carious lesions were noted on the incisors and left canine. A diagnosis of localized periodontitis was made, and the patient was scheduled for scaling and root debridement.

At 4 weeks after scaling and root debridement, the periodontal pocket depths, gingival inflammation, and mobility had not resolved. The patient was then scheduled for a palatal open-flap procedure to investigate the bony defect. During the open debridement surgery, significant palatal and interproximal alveolar bone loss were noted around the right central incisor and left incisors and canine (Figure 2). No root fracture or cystic lesion was detected.

The patient was referred back to her general dentist for a prosthetic treatment plan. Because of the mobility

^aDivision of Periodontics, College of Dentistry, University of Kentucky, Lexington, KY, USA.

^bWoodbridge Periodontal and Implant Center, Woodbridge, VA, USA.

^cDivision of Oral Diagnosis, Oral Medicine, and Oral Radiology, College of Dentistry, University of Kentucky.

^dCity of Hope Comprehensive Cancer Center, Duarte, CA, USA.

^eCedars-Sinai Health System, Los Angeles, CA, USA.

Received for publication Dec 20, 2020; accepted for publication Jan 8, 2021.

© 2021 Elsevier Inc. All rights reserved.

2212-4403/\$-see front matter

<https://doi.org/10.1016/j.oooo.2021.01.009>

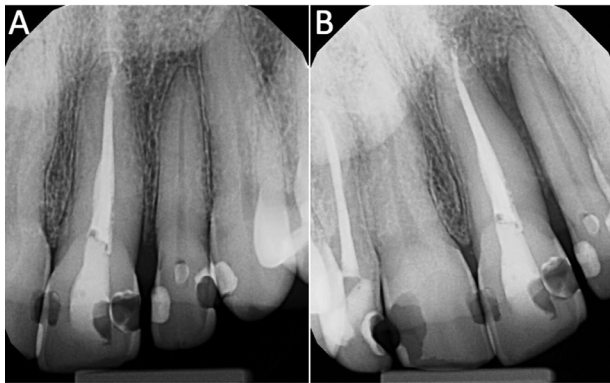


Fig. 1. (A) Baseline periapical image shows intact laminae durae and periodontal ligament spaces. (B) One-year follow-up intraoral radiograph shows an area of ill-defined bone loss around teeth 9 and 10. Note the loss of lamina dura between the 2 teeth.

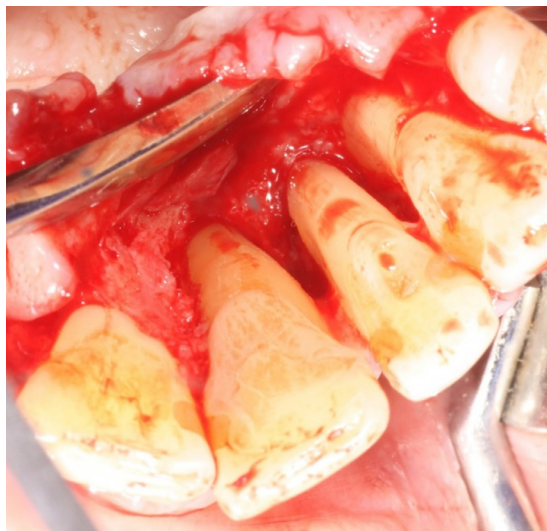

Fig. 2. Significant bone loss on the palatal aspect and between teeth 9, 10, and 11 evident during the flap surgery.

of the teeth, recurrent caries, and existing bone defect, the treatment plan included extraction of the involved teeth, ridge augmentation, and implant placement. The final prosthesis planned was an implant-supported bridge.

Upon the patient's return visit to the periodontist, the involved teeth were extracted without complications. Extraction sites were grafted using a mixture of autogenous blood coagulum with freeze-dried bone allograft and inorganic bovine bone material. The grafted area was then covered with a titanium-reinforced expanded polytetrafluoroethylene membrane. The mucoperiosteal flap was coronally advanced, and primary closure was obtained. The surgery occurred without complication, and a temporary acrylic removable prosthesis was delivered. Two weeks later, the patient presented for

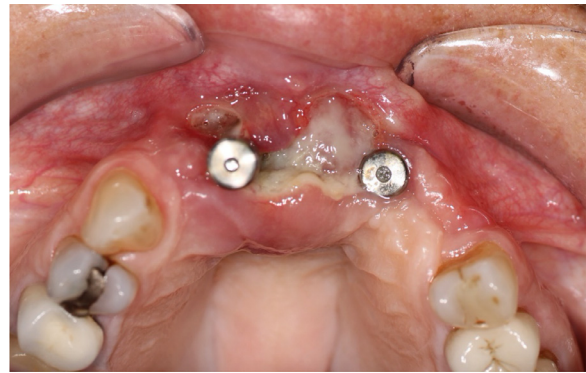


Fig. 3. Occlusal view showing extensive tissue destruction and necrosis between existing implants 7 and 10.

the postoperative visit with uneventful healing. At 8 weeks, the membrane was removed because of large membrane exposure. All further follow-up visits revealed normal healing.

Five months after extraction, the patient presented for implant placement. Slight inflammation and tenderness were present at the surgical site. Purulence was not noted. A mucoperiosteal flap was raised, and implant osteotomy was prepared using the osseodensification technique with Densah burs. Zimmer implants (3.7 × 13 mm) were placed at the right central and left lateral incisor sites using standard manufacturing protocols. During all follow-up visits after the implants were placed, the patient continued to report pain and tenderness. Gingival inflammation was noted, but no signs of purulence were present. Five weeks postoperatively, the surgical site revealed wound dehiscence covered with sloughing and necrotic tissue (Figure 3). The existing implants were removed, and a biopsy was obtained and submitted for histopathologic evaluation. The biopsy specimen confirmed the presence of squamous cell carcinoma (Figure 4). At that point, the patient was referred to an oral and maxillofacial surgeon, who performed a partial maxillectomy. At the 6-month follow-up visit, the patient was doing well, with no clinical or imaging evidence of a recurrence.

Case 2

A 50-year-old man with a 30-pack-year history of smoking, dental caries, periodontitis with calculus, and limited prior dental care (last dental visit more than 10 years prior) was seen for a dental visit. The patient reported trauma to the lower anterior teeth 30 years prior as a result of a motor vehicle accident but had no current symptoms or history of treatment. The patient reported pain in the lower anterior teeth. Periapical films revealed a radiolucency around the roots of the left central and right lateral incisors; there was no mobility of the teeth. Minimal root resorption was identified (Figure 5).

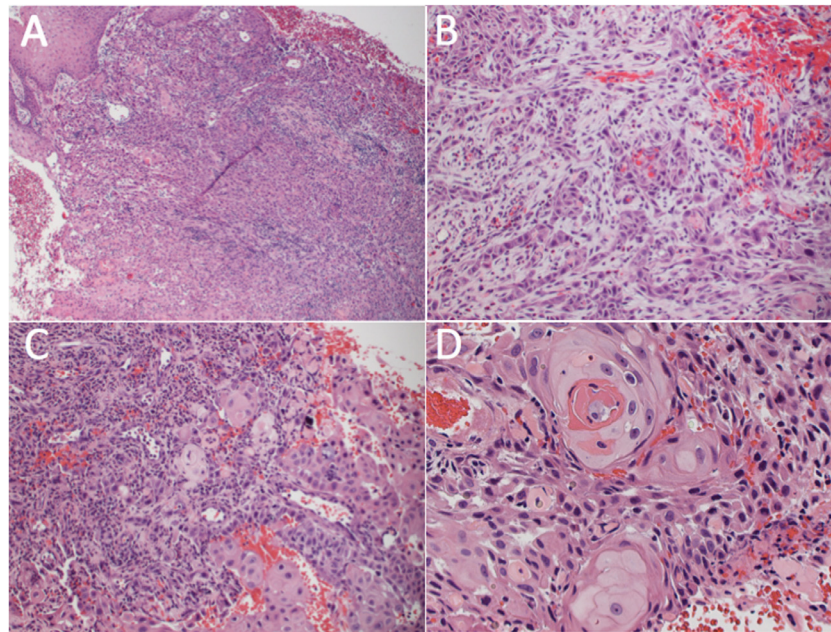


Fig. 4. Squamous cell carcinoma of the gingiva. (A) Dysplastic stratified squamous epithelium exhibiting transition to an invasive squamous cell carcinoma (hematoxylin and eosin [H&E] stain; original magnification, $\times 100$). (B) Tumor cells with hyperchromatic and pleomorphic nuclei arranged in cords are invading into underlying fibrous connective tissue (H&E stain; original magnification, $\times 200$). (C) Small islands of malignant epithelium invading inflamed and vascular connective tissue (H&E stain; original magnification, $\times 200$). (D) Malignant tumor islands demonstrating keratin pearl formation and individual cell keratinization (H&E stain; original magnification, $\times 400$).

Three months later, he reported mobility of the lower anterior teeth and was referred for periodontal evaluation as well as an endodontic consult. The initial periodontal evaluation suggested periodontitis and possible bone necrosis. The patient received oral prophylaxis and a consultation with a second periodontist, who performed flap curettage. Endodontic evaluation did not uncover a dental cause, and continuing periodontal

follow-up was provided. A tissue biopsy was not obtained.

Clinical periodontal evaluation at 5 months after the initial visit showed grade III mobility of the incisors and gingival “granulation” tissue. Periapical images at this visit showed progression in bone destruction. The mobile teeth were extracted, and a temporary bridge was delivered (Figure 6). Three months later, loss of tissue on the lingual aspect of the mandible resulted in a space between the temporary bridge and the gingival margin. The patient’s symptoms progressed, leading to the use of topical anesthetics to control pain and antibiotics. Root exposure and continuing discomfort in the anterior region were noted; a flap was raised; and “necrotic bone” was removed. Again, a biopsy was not obtained. There were no risk factors for osteonecrosis due to medication or radiation therapy, albeit tobacco use and poor oral hygiene were noted. By the following month, the patient’s pain had increased, and hydrocodone/acetaminophen (Vicodin, AbbVie Inc (North Chicago, IL)) was prescribed. Swelling and redness of the tissue reportedly improved; the temporary bridge was removed; and a removable acrylic prosthesis was delivered. Food debris under the prosthesis and local irritation were attributed to poor oral hygiene. The patient was seen by a wound management service because of persistence of symptoms. One month later, he

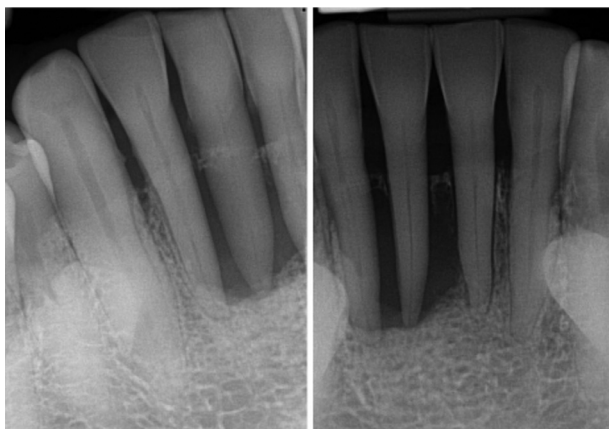


Fig. 5. Periapical films show a sharply destructive lytic lesion around the incisor teeth. Note the sparing of the adjacent alveolar crest, which indicates the epicenter of the lesion is in the midroot area of the involved teeth.

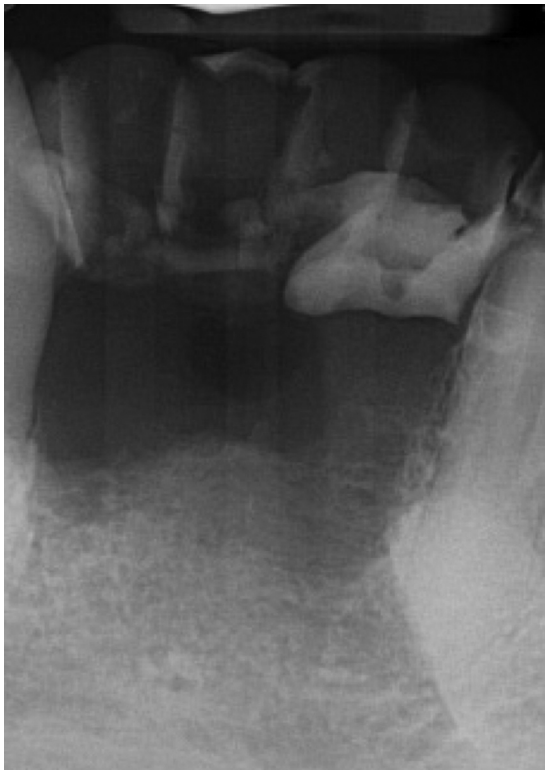


Fig. 6. Four months later, bone destruction is extensive, resulting in loss of teeth.

developed erythema and a visible swelling on the labial aspect of the anterior mandible under the prosthesis. At that time, the patient reported a 5-month history of pain in the anterior mandible but denied altered sensation in the jaw or lip. Clinically, the bone was exposed

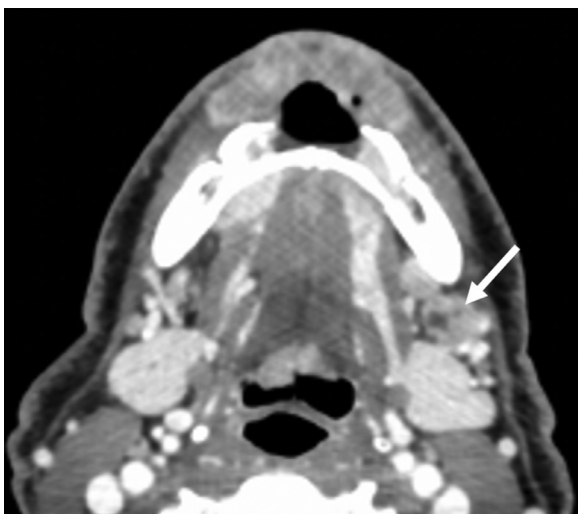


Fig. 7. Axial contrast-enhanced computed tomographic image showing inhomogeneous enhancement of a large, destructive soft-tissue mass arising in the anterior mandible. There is a metastatic left level IB node that appears to have a necrotic center (arrow).

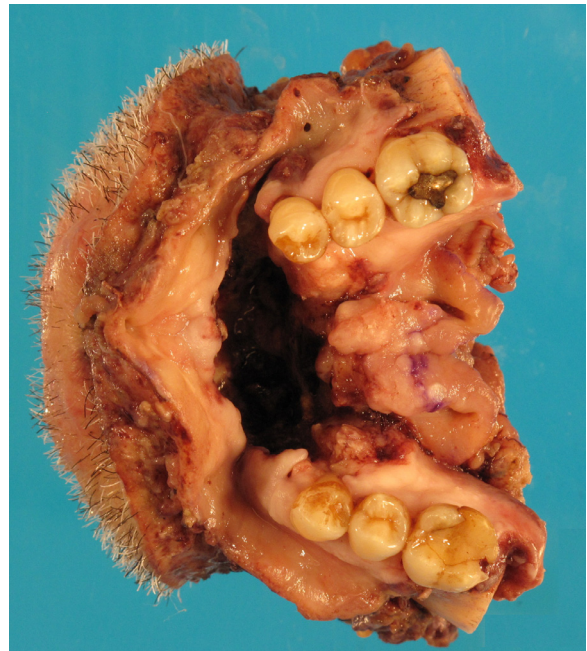

Fig. 8. Surgical specimen of segmental mandibulectomy with a through-and-through resection of the musculature of the floor of the mouth, including the overlying skin.

with “granulation-like” tissue in the area, but no “mass” or discharge was seen. Necrotic-appearing bone was noted, and both canines were mobile. A cone-beam computed tomographic examination showed extensive loss of bone in the mandibular anterior area (more profound on the facial than on the lingual surface). The clinical differential diagnosis at that time included osteomyelitis and squamous cell carcinoma. A tissue biopsy was completed, and moderately differentiated to well-differentiated squamous cell carcinoma was identified.

The patient was referred for cancer management. Magnetic resonance imaging revealed an alveolar bone lesion and possible left level IB nodes. Contrast-enhanced computed tomographic imaging showed a destructive soft-tissue mass in the anterior mandible extending to the lip and chin. Bone destruction was identified primarily on the facial aspect of the mandible (Figure 7).

Nine months after developing mobility of his lower anterior teeth, he had a mandibular resection, neck dissection, and flap reconstruction (Figure 8). He was staged as pT4N2aM0. Pathologic evaluation showed extensive invasion of mandibular bone with extension into soft tissue, with a positive node on the left and right at level 3 and on the right at level 4. He received combined radiotherapy and docetaxel with cetuximab per RTOG 1216.⁵ He also had a left ear lesion that, on biopsy, showed squamous cell carcinoma and associated in situ changes at the margins representing a

second primary. After chemoradiotherapy, he developed a left pulmonary node, pleural effusion, and confirmed metastasis. Nine months after surgery, he was admitted to the hospital with respiratory failure due to lung involvement and received pembrolizumab. He subsequently entered hospice care.

DISCUSSION

Oral cancer accounts for approximately 3% of all cancers and 2% of cancer-related mortality in the United States, whereas in South Central Asia it accounts for a little over 30% of all malignancies.^{2,9} More than 90% of oral malignant tumors are squamous cell carcinomas.¹⁰ Most oral squamous cell carcinomas are encountered in older men with poor oral hygiene and a long history of tobacco and alcohol use.¹¹

Persistent ulceration, rapidly enlarging mass, pain with no identifiable dental cause, loosened teeth over a short time, hemorrhage, paresthesia, unhealed extraction sockets, regional lymphadenopathy, and weight loss should raise the index of suspicion for a malignant process. The most affected sites are the floor of the mouth; the posterior lateral and ventral borders of the tongue; buccal mucosa; and, less frequently, the retromolar area, gingiva, and hard palate. It is believed that the thin, nonkeratinized mucosa of particular intraoral subsites may be more susceptible to the action of carcinogens, resulting in an increased risk of cancer at those sites.¹²

Very rarely, central (intraosseous) examples of squamous cell carcinoma may develop from epithelial components enclosed within the jaw during the embryonic process or from the epithelial lining of a pre-existing dental cyst.¹³ However, when the tumor destroys the cortex and invades the oral mucosa, it may be difficult to determine whether the lesion has arisen from the overlying mucosa or from within the bone.

Both patients in this report presented with localized periodontal involvement that was resistant to conventional therapy. The clinicians did not consider carcinoma early in the course of the diseases in either patient, even though both initially had a visible lesion potentially suggestive of carcinoma. Although the

exact site of origin could be debated in these cases, the carcinoma in the first case appears to have arisen from surface epithelium. In this instance, even if the outer attached gingiva appeared normal, the involvement of the crevicular epithelium could have gone undetected.⁶ We suggest that the same scenario applies to the second case, especially with the type of alveolar bone loss noted (i.e., bone destruction limited to the facial aspect of the mandible).

Gingival squamous cell carcinoma accounts for approximately 9% of all intraoral carcinomas, more commonly affecting the mandibular gingiva.¹⁴ Involvement of the underlying bone is a frequent finding, occurring in nearly 67% of gingival carcinomas at initial presentation.³ When bone is involved, the radiographic examination is of great value in identification of the tumor. Gingival carcinoma that erodes into the underlying alveolar bone may mimic periodontal disease in plain radiographs.⁵⁻⁸ Thus, plain radiographs should be interpreted with caution and within the clinical context.

The radiographic features seen in gingival carcinoma compared with periodontal disease are listed in **Table I**. Radiographic evidence of tumor invasion around teeth may first appear as irregular widening of periodontal ligament space with destruction of adjacent lamina dura. The differential diagnosis for lesions with this appearance should include osteosarcoma, metastatic carcinoma, and lymphoma. With progression, the destruction of the supporting alveolar bone may be so severe that the teeth appear to be “floating.” With this presentation, the differential diagnosis should include Langerhans cell histiocytosis. The bony margins are usually irregular and lack any sharp demarcation from the adjacent normal bone, resulting in difficulty in defining the precise extent of the disease. These margins are produced by finger-like extension of the tumor into the surrounding bone in an infiltrating pattern with absence of reactive marginal sclerosis. In most cases, malignant tumors appear not to cause root resorption.

In constructing a differential diagnosis, it is helpful to know that primary carcinoma does not tend to

Table I. Radiographic differentiation of periodontal disease and gingival carcinoma

| Periodontal disease | Gingival carcinoma |
|---|--|
| Bone destruction starts at the alveolar crest and extends apically down the root surface. | Bone destruction starts in the midroot region of the involved teeth. |
| Widening of the periodontal ligament space develops at the alveolar crest and furcation region. | Irregular widening of the periodontal ligament space accompanied by destruction of the lamina dura. |
| The margin of the alveolar bone defect is sharp and smooth. | Margins are poorly defined and ragged. |
| The radiolucent defect does not contain trabecular remnants. | Little residual bone may be present within the center of the radiolucent area. |
| The lesion may stimulate a reaction in the surrounding bone. | Lack of peripheral bone reaction (sclerosis) |
| The bone loss is often generalized, and local irritating factors such as calculus may be seen. | The bone loss is often limited to a single region of bone involvement with absence of local factors for periodontal disease. |

produce any new bone within the lesion or in the adjacent bone; however, secondary (metastatic) carcinoma may be purely radiolucent (osteolytic), radiopaque (osteoblastic), or mixed radiolucent and radiopaque.¹⁵

In the second case, the plain radiograph revealed an extensive periodontal lesion; however, the crestal bone was intact, suggesting that the epicenter of the bone destruction was in the midroot region rather than at the crest, which belies its inflammatory nature.

Periodontal lesions that are refractory to conventional therapy should raise suspicion of a neoplastic process necessitating biopsy to establish a tissue diagnosis. In both cases, despite opportunities for earlier biopsy, the lack of recognition of the potential for bone loss to be owing to a malignant process led to months of delay in diagnosis and poor outcomes.

In summary, the specific clinical and radiographic features that might have led to a proper diagnosis earlier in the 2 cases are listed below:

1. Periodontal involvement of a few adjacent teeth in the absence of generalized periodontitis
2. Unexplained dental pain
3. Loosened teeth over a short time
4. Lack of normal healing after periodontal treatment
5. Necrosis and ulceration of the overlying mucosa
6. Exposure of underlying bone
7. Evidence of bone destruction with subsequent soft-tissue mass
8. Ill-defined bone destruction with lack of reactive peripheral sclerosis
9. Extensive bone destruction of a localized region beyond the periodontium
10. Radiographic evidence that the epicenter of the bone destruction is in the midroot region instead of the alveolar crest

CONCLUSIONS

This report documents the importance of considering gingival carcinoma, even in the absence of a visible lesion, in 2 patients with periodontal lesions unresponsive to conventional therapy. The importance of submitting periodontal tissues excised during surgical procedures for histopathologic analysis is emphasized. In addition, careful history and detailed review of imaging may provide guidance in the decision for biopsy. Dentists should be especially diligent in the search for potential signs and symptoms of malignancy in their patients, because failure to recognize a malignant condition can lead to delayed diagnosis and treatment, added morbidity and mortality, and increased medical legal liability.

REFERENCES

1. Onizawa K, Nishihara K, Yamagata K, Yusa H, Yanagawa T, Yoshida H. Factors associated with diagnostic delay of oral squamous cell carcinoma. *Oral Oncol.* 2003;39:781-788.
2. National Cancer Institute, Surveillance, Epidemiology, and End Results Program. Cancer stat facts: cancer of the oral cavity and pharynx. Available at: <https://seer.cancer.gov/statfacts/html/oralcav.html>. Accessed December 12, 2020.
3. Seoane J, Varela-Centelles PI, Walsh TF, Lopez-Cedrun JL, Vazquez I. Gingival squamous cell carcinoma: diagnostic delay or rapid invasion? *J Periodontol.* 2006;77:1229-1233.
4. Kowalski LP, Franco EL, Torloni H, et al. Lateness of diagnosis of oral and oropharyngeal carcinoma: factors related to the tumour, the patient and health professionals. *Eur J Cancer B Oral Oncol.* 1994;30B:167-173.
5. Bornstein MM, Andreoni C, Meier T, Leung YY. Squamous cell carcinoma of the gingiva mimicking periodontal disease: a diagnostic challenge and therapeutic dilemma. *Int J Periodontics Restorative Dent.* 2018;38:253-259.
6. Heller AN, Klein A, Barocas A. Squamous cell carcinoma of the gingiva presenting as an endoperiodontic lesion. *J Periodontol.* 1991;62:573-575.
7. Yoon TY, Bhattacharyya I, Katz J, Towle HJ, Islam MN. Squamous cell carcinoma of the gingiva presenting as localized periodontal disease. *Quintessence Int.* 2007;38:97-102.
8. Kim OS, Uhm SW, Kim SC, et al. A case of squamous cell carcinoma presenting as localized severe periodontitis in the maxillary gingiva. *J Periodontol.* 2012;83:753-756.
9. Sankaranarayanan R, Ramadas K, Thomas G, et al. Effect of screening on oral cancer mortality in Kerala, India: a cluster-randomised controlled trial. *Lancet.* 2005;365:1927-1933.
10. Kirsch C. Oral cavity cancer. *Top Magn Reson Imaging.* 2007;18:269-280.
11. Mathur R, Singhvi HR, Malik A, Nair S, Chaturvedi P. Role of poor oral hygiene in causation of oral cancer—a review of literature. *Indian J Surg Oncol.* 2019;10:184-195.
12. Mashberg A, Meyers H. Anatomical site and size of 222 early asymptomatic oral squamous cell carcinomas: a continuing prospective study of oral cancer. II. *Cancer.* 1976;37:2149-2157.
13. Eversole LR, Siar CH, van der Waal I. Primary intraosseous squamous cell carcinomas. In: El-Naggar AK, Chan JKC, Grandis JR, Takata T, Slootweg PJ, eds. *WHO Classification of Head and Neck Tumours*, 3rd ed., Lyon, France: IARC Press; 2005:290-291.
14. Funk GF, Karnell LH, Robinson RA, Zhen WK, Trask DK, Hoffman HT. Presentation, treatment, and outcome of oral cavity cancer: a National Cancer Data Base report. *Head Neck.* 2002;24:165-180.
15. White S, Pharaoh M. Malignant diseases. In: White S, Pharaoh M, eds. *Oral Radiology: Principles and Interpretation*, 7th ed., St. Louis, MO: Mosby; 2014:427-451.

Reprint requests:

Galal Omami BDS, MSc, MDentSc, FRCD(C)
Division of Oral Diagnosis
Oral Medicine, and Oral Radiology
College of Dentistry
University of Kentucky
800 Rose Street
Lexington
KY, 40536
United States
galal.omami@uky.edu