

Fetal Surgery in the Primate 4.0: A New Technique 30 Years Later

Erin E. Perrone^{a, b} Laura A. Galganski^c Alice F. Tarantal^d Katie J. Olstad^e
Marjorie C. Treadwell^{b, f} Deborah R. Berman^{b, f} Marcus D. Jarboe^{a, b}
George B. Mychaliska^{a, b} Diana L. Farmer^{c, g}

^aSection of Pediatric Surgery, Department of Surgery, C.S. Mott Children's Hospital, Michigan Medicine, University of Michigan, Ann Arbor, MI, USA; ^bFetal Diagnosis and Treatment Center, Michigan Medicine, University of Michigan, Ann Arbor, MI, USA; ^cDepartment of Surgery, UC Davis Children's Hospital, University of California, Davis, Sacramento, CA, USA; ^dDepartments of Pediatrics and Cell Biology and Human Anatomy, School of Medicine, and California National Primate Research Center, University of California, Davis, CA, USA; ^eLaboratory Animal Pathology, California National Primate Research Center, University of California, Davis, CA, USA; ^fDivision of Maternal-Fetal Medicine, Department of Obstetrics and Gynecology, C.S. Mott Children's Hospital and Von Voigtlander Women's Hospital, Michigan Medicine, University of Michigan, Ann Arbor, MI, USA; ^gFetal Care and Treatment Center, University of California, Davis, Davis, CA, USA

Keywords

Hysterotomy · Fetal surgery · Harmonic ACE[®]+7 Shears · Prenatal surgery

Abstract

Introduction: Open fetal surgery requires a hemostatic hysterotomy that minimizes membrane separation. For over 30 years, the standard of care for hysterotomy in the gravid uterus has been the AutoSuture Premium Poly CS*-57 stapler. **Objective:** In this study, we sought to test the feasibility of hysterotomy in a rhesus monkey model with the Harmonic ACE[®]+7 Shears. **Methods:** A gravid rhesus monkey underwent midgestation hysterotomy at approximately 90 days of gestation (2nd trimester; term = 165 ± 10 days) using the Harmonic ACE[®]+7 Shears. A two-layer uterine closure was completed and the dam was monitored by ultrasound intermittently throughout the pregnancy. At 58 days after hysterotomy (near term), a final surgery was performed to evaluate

the uterus and hysterotomy site. **Results:** A 3.5-cm hysterotomy was completed in 2 min 7 s. The opening was hemostatic and the membranes were sealed. Immediately after closure and throughout the pregnancy, ultrasound revealed intact membranes without separation and normal amniotic fluid levels. At term, the scar was well healed without signs of thinning or dehiscence. **Conclusions:** The Harmonic ACE[®]+7 Shears produced a hemostatic midgestation hysterotomy with membrane sealing in the rhesus monkey model. Importantly, healing was acceptable. © 2020 S. Karger AG, Basel

Introduction

Open fetal surgery began in the 1980s at the University of California, San Francisco [1]. Initial work in the rhesus monkey model was performed to optimize anesthesia, tocolysis, and operative technique, including

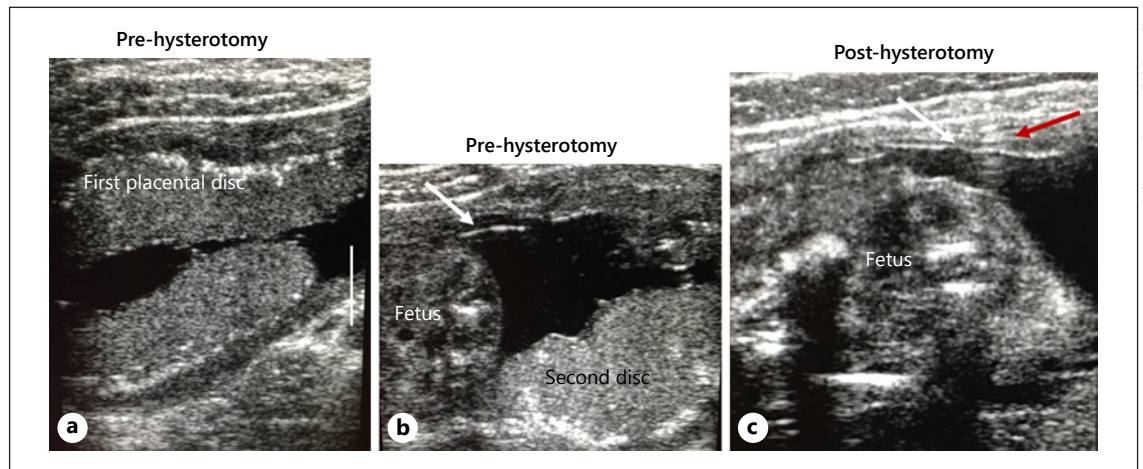


Fig. 1. Ultrasound images before (**a, b**) and after hysterotomy (**c**). **a, b** Before hysterotomy the location of the placental discs was verified and intact membranes (white arrow) and viability of the fetus were confirmed. **c** The post-hysterotomy scan showed intact membranes (white arrow) at the site of the uterine scar (red arrow indicates artifact from a suture). The scale bar in **a** denotes 1 cm.

opening and closing of the uterus. The published results for those studies were titled *Fetal Surgery in the Primate I, II, and III* [2–4]. During this time, with the aid of this translational nonhuman primate model, the fetal community learned that metallic staples were detrimental to future fertility. To ameliorate the problem of infertility in future reproductive life, a novel stapler using absorbable copolymer staples was developed. Following safety and efficacy testing in the rhesus monkey model, the AutoSuture Premium Poly CS*-57 stapler (Medtronic, Minneapolis, MN, USA) has remained the standard of care for open fetal surgery to this day [4, 5]. As the sole use of this stapler is fetal surgery, its utility is limited [6, 7]. Additionally, limited international availability has resulted in exploration of alternative techniques for uterine opening without background safety data in animal models [8].

We have shown previously that the Harmonic ACE®+7 Shears (Ethicon, Somerville, NJ, USA) performed similarly to the AutoSuture Premium Poly CS*-57 stapler for uterine opening in the gravid ovine model. The Harmonic ACE®+7 Shears hysterotomy resulted in similar tensile strength and less fibrosis than the stapler [9]. That study also tested the LigaSure™ Impact (Medtronic) for uterine opening. The LigaSure™ Impact performed a hemostatic hysterotomy with membrane sealing; however, the lateral thermal spread was significantly increased, thus it was not studied further in pregnancy continuation and healing was not evaluated [9]. The ovine study evaluated whether there was a role in utilizing a surgical power de-

vice for hysterotomy incision, but the ovine myometrium thinness limited comparability to human use. In the feasibility study reported herein, we sought to determine whether the Harmonic ACE®+7 Shears could be used to safely open the uterus in the rhesus monkey model as the rhesus uterus is more comparable to that of humans [10]. We also sought to determine whether, with traditional closure techniques, the hysterotomy healed and permitted continued gestation.

Methods

A normally cycling adult female rhesus monkey (*Macaca mulatta*; 7.4 kg, approximately 9 years of age) with a history of prior pregnancy was bred and identified as pregnant according to established methods [11]. The dam was sonographically monitored during gestation to confirm normal fetal growth and development prior to selection for the project.

Initial Hysterotomy Surgery

On the day of surgery (approximately 90 days of gestation, second trimester; term = 165 ± 10 days) the dam was sedated with ketamine (10 mg/kg i.m.). A 1.5-mL blood sample was collected from a peripheral vessel for a complete blood count and chemistry panel, which were both within normal limits. An ultrasound examination was performed to confirm fetal viability and placental disc locations (bidiscoid placenta) immediately prior to surgery. The locations of the placental discs were documented, with the primary disc located laterally (right) and anterior and the secondary disc located posteriorly (Fig. 1a). The dam was brought from the imaging suite to the surgery suite for intubation followed by

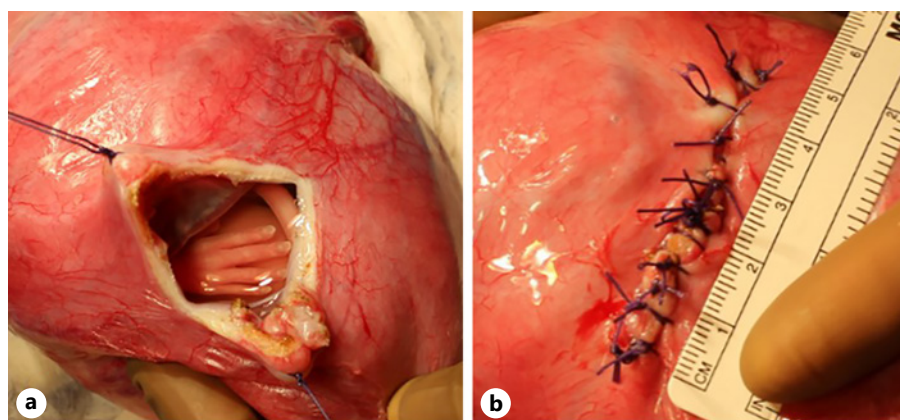


Fig. 2. Hemostatic hysterotomy (3.5 cm) completed on both sides of the stay sutures with a Harmonic ACE®+7 Shears (a) and after two-layer closure (b).

placement of an intravenous catheter. Atropine (0.04 mg/kg) was administered. The dam was then placed on intravenous fluids and inhaled isoflurane (2.5% for induction followed by maintenance at 1.5%) for general anesthesia. A midline laparotomy was performed and the gravid uterus was carefully exteriorized from the maternal abdomen. The placental locations were confirmed with palpation, and the location for safe uterine opening was selected. Two hemostatic stay sutures were placed on either side with 2-0 Vicryl (Ethicon). The uterus was initially entered between these sutures with Bovie electrocautery. The Harmonic ACE®+7 Shears, utilizing the advanced hemostasis mode, was used to complete a 3.5-cm opening in the uterus (Fig. 2a). The hysterotomy was then closed in two layers utilizing a single running layer and interrupted retention sutures; all uterine suture was 2-0 Vicryl (Fig. 2b). Prior to closure, an intraperitoneal dose of antibiotics was given (500 mg of nafcillin in 60 mL of warmed sterile saline) for infection prophylaxis. The uterus was returned to the maternal abdomen and the fascia and skin were closed.

Postoperative Monitoring

Postoperative medications included valium (0.5 mg/kg i.v.) and midazolam (38 mg s.c.) immediately after surgery. Prior to extubation an ultrasound examination confirmed that the amniotic membranes were intact (Fig. 1b). Analgesia was given for 3 days, including hydromorphone (0.15 mg/kg i.m. three times daily), buprenorphine (0.03 mg/kg i.m. once daily), and ketoprofen (5.0 mg/kg i.m. three times daily). The dam and fetus were monitored with ultrasound 2 days postoperatively and intermittently throughout the pregnancy.

Hysterotomy Recovery Surgery

At 58 days after hysterotomy (approximately 148 days of gestation, near term; term 165 ± 10 days), the dam was sedated with ketamine (10 mg/kg i.m.), a blood sample was collected for presurgery complete blood count, and an ultrasound examination was performed to confirm fetal viability and uterine healing. The dam was intubated, an intravenous catheter was placed, and general anesthesia was initiated with atropine (0.04 mg/kg) and isoflurane (2.5% with maintenance at 1.5%). A midline laparotomy was performed and the gravid uterus was exteriorized from the maternal abdomen. The healed hysterotomy incision was inspected grossly and resected for histological analysis. The hysterotomy was closed

and the uterus was returned to the maternal abdomen. The abdominal fascia and skin were closed.

Histological Analysis

The tissue was sectioned perpendicular to the scar and fixed in 10% buffered formalin and routinely processed; 5- μ m sections were stained with hematoxylin and eosin as well as Masson's trichrome. A board-certified veterinary pathologist categorized the degree of inflammation and fibrosis as mild, moderate, or severe, as previously described [9]. The presence of inflammatory cells, foreign material, appearance of fetal membranes, adherence of adipose tissue, and presence of amniotic fluid components was also evaluated.

Results

Initial Hysterotomy Surgery

The 3.5-cm hysterotomy was completed in 4 min 50 s: primary opening with the Bovie was 2 min 43 s and completion with the Harmonic ACE®+7 Shears was 2 min 7 s. Each centimeter of uterine opening with the Harmonic ACE®+7 Shears took approximately 25 s to complete. Membrane separation was noted at the point of initial opening with the Bovie, but the membranes were sealed at all areas where the Harmonic ACE®+7 Shears was used (Fig. 2a). Importantly, the membranes did not adhere to the Harmonic ACE®+7 Shears during the procedure, which has been observed with the LigaSure™ Impact in the ovine model [9].

Postoperative Monitoring

The immediate postoperative ultrasound examination confirmed transient fetal bradycardia which resolved and intact membranes without separation (Fig. 1). Follow-up ultrasound examinations 2 days after hysterotomy and subsequently throughout pregnancy revealed a normal

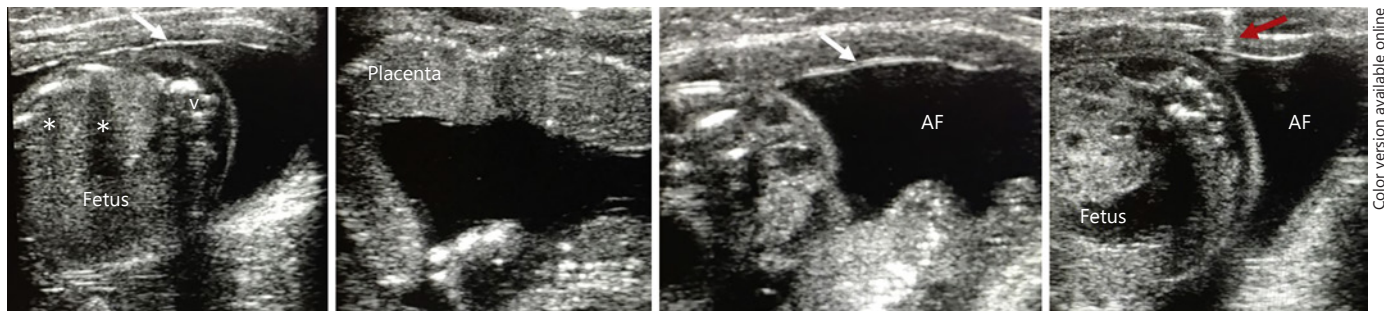


Fig. 3. Ultrasound images 2 days after hysterotomy. The white arrows highlight intact membranes, the red arrow artifact from suture. AF, amniotic fluid; v, fetal vertebrae; *, fetal rib shadowing.

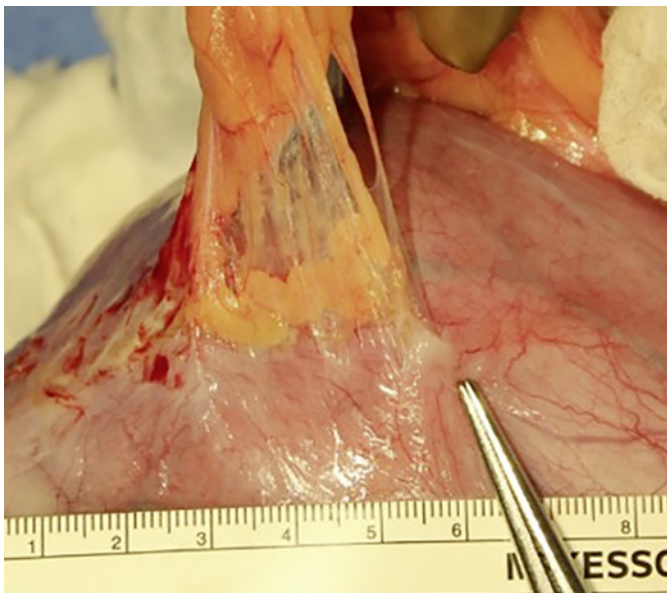


Fig. 4. Healed hysterotomy 58 days after initial surgery. The omentum adhered to the incision site. The incision was well healed without signs of thinning or dehiscence.

fetal heart rate, intact membranes, and pockets of amniotic fluid within normal limits (Fig. 3). The dam showed no signs of discomfort when postoperative analgesics were completed, and all fetal parameters were within normal limits at all time points assessed (e.g., heart rate, growth and development, and placental parameters).

Hysterotomy Recovery Surgery

At 58 days after hysterotomy, the uterine incision grossly appeared well healed and measured 5 cm in length. The omentum was adherent to the incision site (Fig. 4) and there were no signs of thinning or dehiscence (Fig. 4).

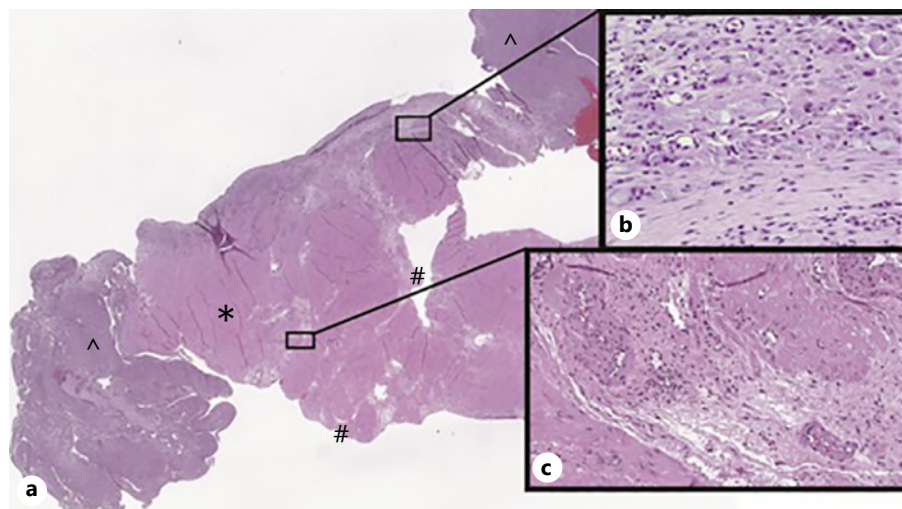
Histological analysis showed moderate multifocal inflammation and fibrosis throughout the myometrium (Fig. 5). Inflammation consisted of perivascular and scattered lymphocytes, plasma cells, and fewer neutrophils. In addition, there was generalized myometrial edema. The amniotic membrane, when present, appeared normal. Foreign material was surrounded by giant cell macrophages and fibrosis in the central area of the grossly observed scar.

Discussion

In this study, we demonstrated that the Harmonic ACE[®]+7 Shears resulted in a good outcome for mid-gestation hysterotomy in the rhesus monkey model as evidenced by a well-healed uterine incision and continued pregnancy without incident. The membranes sealed upon uterine opening and remained fused for the remainder of the pregnancy. There was no evidence of chorion-amnion separation and the amniotic fluid volume was normal by ultrasound evaluation across the remainder of pregnancy. The incision was well healed at the recovery operation and showed no signs of dehiscence or thinning.

The AutoSuture Premium Poly CS*-57 stapler was developed for fetal surgery in the 1980s and remains the standard of care to this day. The benefits of this stapler included simple use, hemostasis, membrane sealing, and fewer adverse effects upon future reproduction than metallic staplers [5]. This was important as it met the goals of hysterotomy for fetal surgery, i.e., the membranes remained intact to decrease the risk of premature rupture of membranes, the hysterotomy opening was hemostatic to avoid unnecessary blood loss, and post-hysterotomy healing was adequate to ensure continuation of the pregnancy. Use of this stapler for cesarean deliveries has been

Fig. 5. Hematoxylin and eosin stain of the hysterotomy scar demonstrated moderate inflammation. Cross-section of the hysterotomy scar with myometrium (*), decidua (^), and serosa (#). **a** Low magnification of uterine and placental tissue taken from the middle of the surgical site ($\times 0.3$). **b** Fibrosis surrounding foreign material ($\times 40$). **c** Perivascular inflammation ($\times 10$).



Color version available online

studied with mixed results [6, 12, 13]. However, both a 2000 and 2014 Cochrane Database review showed no difference in cesarean delivery performed with the stapling device versus traditional opening. Due in part to the expense, the copolymer stapler has not gained wide use outside of fetal surgery [7, 14].

Despite its innovative and novel design, the AutoSuture Premium Poly CS*-57 stapler is not without limitations even in the field of fetal surgery. The production process to manufacture the absorbable copolymer staples is quite complex, requiring exact specifications that often result in demand exceeding supply. The stapler has occasionally been on backorder, leaving our institution and others without the product for limited periods of time. The lack of universal availability internationally as well as local unavailability have resulted in the rise of innovative techniques that have not been studied in a primate model. In our experience, the stapler device will also occasionally misfire, resulting in unintentional bleeding and/or membrane separation.

Due to these limitations, our group has explored alternative methods of hysterotomy in animal models. A previous study compared two commercially available surgical energy devices in an ovine model and found the Harmonic ACE[®]+7 Shears suitable for creating a timely, hemostatic hysterotomy without membrane separation. Importantly, there was significantly less thermal injury when using the Harmonic ACE[®]+7 Shears compared to the LigaSure[™] Impact [9]. Due to this decreased thermal injury in the Harmonic ACE[®]+7 Shears, subsequent ovine studies compared the Harmonic ACE[®]+7 Shears to the historically used stapler device. Healing was adequate

after 5–6 weeks of continued gestation with the Harmonic ACE[®]+7 Shears and showed similar inflammation with less fibrosis when compared to the AutoSuture Premium Poly CS*-57 stapler [9]. For both the ovine study and the current nonhuman primate study, the advanced hemostasis mode was utilized on the Harmonic ACE[®]+7 Shears as this allows sealing of blood vessels up to 7 mm in diameter with less lateral thermal damage than with other devices [15].

The degree of histological inflammation and fibrosis of the hysterotomy scar observed in this study was similar to that produced with the stapler in both ovine and human studies [9, 16]. The fibrosis was moderate and multifocal as seen with use of the AutoSuture Premium Poly CS*-57 stapler in the ovine model [9]. In this single animal, the fibrosis was more multifocal than the mild fibrosis that was largely limited to the region surrounding suture material in the ovine model [9]. Adhesions from adipose tissue on the serosa were visualized similarly to those seen with human stapled hysterotomy [16].

Although our study supports the consideration of hysterotomy creation with the Harmonic ACE[®]+7 Shears for human studies, it is not without limitations. The primary limitation is that the study was completed on a single animal; we recognize that more animals would be needed to fully address safety. The second limitation is that we did not explore future reproductive potential after surgery. We anticipate that the Harmonic ACE[®]+7 Shears hysterotomy will not have a detrimental effect upon fertility or the course of future pregnancies since there is no retained foreign body and the tissue impact is minimal. A third limitation is that the procedure did not

fully simulate open fetal surgery as there was minimal fetal manipulation. This study was designed to assess the feasibility of using the Harmonic ACE[®]+7 Shears to safely open the uterus and demonstrate healing with continued gestation, which it achieved. Although the rhesus monkey uterus is the best primate model of the human uterus [10], we also recognize that rhesus monkeys are smaller, and while more comparable to humans than the sheep, the uterus does not have the same thickness as that of humans at this stage of gestation. However, it is important to recognize that the original studies performed with the AutoSuture Premium Poly CS*-57 stapler in rhesus monkeys provided the safety data necessary to advance human clinical studies and were predictive. Finally, we recognize that some centers describe using other surgical power devices in the human for hysterotomy (unpublished data). Based on our prior experience, we limited the current study to the Harmonic ACE[®]+7 Shears device.

Conclusion

The Harmonic ACE[®]+7 Shears successfully created a hemostatic, midgestation hysterotomy with membrane sealing in the rhesus monkey model. Amniotic fluid volumes remained stable throughout the pregnancy and healing was observed at delivery.

Acknowledgments

We would like to thank Michael R. Harrison, MD for his advice and knowledge of fetal surgery in the rhesus monkey. We thank all of the team members at the California National Primate Research Center who assisted with the surgery and care of the animal, particularly Kari Christe, DVM, DACLAM.

References

- 1 Deprest JA, Flake AW, Gratacos E, Ville Y, Hecher K, Nicolaides K, et al. The making of fetal surgery. *Prenat Diagn*. 2010 Jul;30(7):653–67.
- 2 Harrison MR, Anderson J, Rosen MA, Ross NA, Hendrickx AG. Fetal surgery in the primate I. Anesthetic, surgical, and tocolytic management to maximize fetal-neonatal survival. *J Pediatr Surg*. 1982 Apr;17(2):115–22.
- 3 Nakayama DK, Harrison MR, Seron-Ferre M, Villa RL. Fetal surgery in the primate II. Uterine electromyographic response to operative procedures and pharmacologic agents. *J Pediatr Surg*. 1984 Aug;19(4):333–9.
- 4 Adzick NS, Harrison MR, Glick PL, Anderson J, Villa RL, Flake AW, et al. Fetal surgery in the primate. III. Maternal outcome after fetal surgery. *J Pediatr Surg*. 1986 Jun;21(6):477–80.
- 5 Bond SJ, Harrison MR, Slotnick RN, Anderson J, Flake AW, Adzick NS. Cesarean delivery and hysterotomy using an absorbable stapling device. *Obstet Gynecol*. 1989 Jul;74(1):25–8.
- 6 Gilson GJ, Kephart WH, Izquierdo LA, Joffe GM, Qualls CR, Curet LB. Comparison of absorbable uterine staples and traditional hysterotomy during cesarean delivery. *Obstet Gynecol*. 1996 Mar;87(3):384–8.
- 7 Dodd JM, Anderson ER, Gates S, Grivell RM. Surgical techniques for uterine incision and uterine closure at the time of caesarean section. *Cochrane Database Syst Rev*. 2014 Jul;(7):CD004732.
- 8 Botelho RD, Imada V, Rodrigues da Costa KJ, Watanabe LC, Rossi Júnior R, De Salles AA, et al. Fetal Myelomeningocele Repair through a Mini-Hysterotomy. *Fetal Diagn Ther*. 2017;42(1):28–34.
- 9 Church JT, McLeod JS, Coughlin MA, Bergin IL, Perkins EM, Hoffman HR, et al. An Early Investigation into Possible Alternatives to Staged Hysterotomy in Open Fetal Surgery. *Am J Perinatol*. 2019 Jun;36(7):742–50.

Statement of Ethics

All procedures conformed to the requirements of the Animal Welfare Act and were approved by the Institutional Animal Care and Use Committee at the University of California, Davis, which is AAALAC-accredited and adheres to all guidelines as established in the current edition of the Guide for the Care and Use of Laboratory Animals and the Animal Welfare Act (A3433-01).

Conflict of Interest Statement

An unfunded agreement was obtained between the University of Michigan and Ethicon for the Harmonic ACE[®]+7 Shears. The authors have no other conflicts of interest to declare.

Funding Sources

Funding for this project was made possible by the Jack L. Berman, MD and Barbara A. Berman, PhD, Fetal Diagnosis Research Fund at the University of Michigan. This study was also supported by the Office of the Director, National Institutes of Health (NIH), through grant No. P51 OD01107 to the California National Primate Research Center. L.A. Galganski was supported by the National Center for Advanced Translational Sciences, NIH, through grant No. UL1 TR001860 to the UC Davis Clinical and Translational Science Center. Ultrasound imaging was performed by A.F. Tarantal with instrumentation funded by the NIH (S10 grant No. OD016261 to A.F. Tarantal).

Author Contributions

Study conception and design: E.E. Perrone, M.C. Treadwell, G.B. Mychaliska, D.R. Berman, M.D. Jarboe. Data acquisition: E.E. Perrone, L.A. Galganski, A.F. Tarantal, D.L. Farmer. Analysis and data interpretation: E.E. Perrone, L.A. Galganski, K.J. Olstad, A.F. Tarantal. Drafting of the manuscript: E.E. Perrone, L.A. Galganski, K.J. Olstad, A.F. Tarantal. Critical revision: D.L. Farmer, A.F. Tarantal, M.C. Treadwell, G.B. Mychaliska, D.R. Berman, M.D. Jarboe.

- 10 Kabagambe SK, Lee CJ, Goodman LF, Chen YJ, Vanover MA, Farmer DL. Lessons from the Barn to the Operating Suite: A Comprehensive Review of Animal Models for Fetal Surgery. *Annu Rev Anim Biosci*. 2018 Feb;6(1):99–119.
- 11 Tarantal AF. Ultrasound imaging in rhesus and long-tailed macaques: reproductive and research applications. In: Wolf-Coote, editor. *The laboratory primate*. Philadelphia: Elsevier; 2005. p. 317–51.
- 12 Hoskins IA, Ordorica SA, Frieden FJ, Young BK. Performance of cesarean section using absorbable staples. *Surg Gynecol Obstet*. 1991 Feb;172(2):108–12.
- 13 Burkett G, Jensen LP, Lai A, O’Sullivan MJ, Yasin S, Beydoun S, et al. Evaluation of surgical staples in cesarean section. *Am J Obstet Gynecol*. 1989 Sep;161(3):540–5; discussion 545–7.
- 14 Wilkinson C, Enkin MW. Absorbable staples for uterine incision at caesarean section. *Cochrane Database Syst Rev*. 2000; 2:CD000005.
- 15 Ethicon. Harmonic ACE®+7 Shears with Advanced Hemostasis. Product Guide. 2020. Available at: https://www.jnjmedicaldevices.com/en-US/product/harmonic-ace-7-shears-laparoscopic-surgery?gclid=EAlaIqobChMIy77GjeHF7AIVgYbACh0XDQy3EAAYASAA-EgJdmvD_BwE&gclid=aw.ds&utm_campaign=ethicon%7Cus-2020-harmonic-branded%3BS%3BMD%3BBR%3BSUR%3BHCP%3BBR&utm_content=ACE%20%2B7&utm_medium=cpc&utm_source=google&utm_term=%2Bharmonic%20%2Bace%20%2B7%20%2Bshears.
- 16 Ochsenbein-Köblle N, Brandt S, Bode P, Krähenmann F, Hüsler M, Möhrle U, et al. Clinical and Histologic Evaluation of the Hysterotomy Site and Fetal Membranes after Open Fetal Surgery for Fetal Spina Bifida Repair. *Fetal Diagn Ther*. 2019;45(4):248–55.