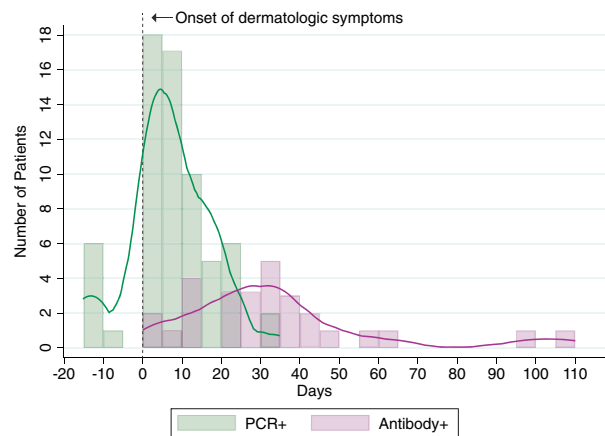
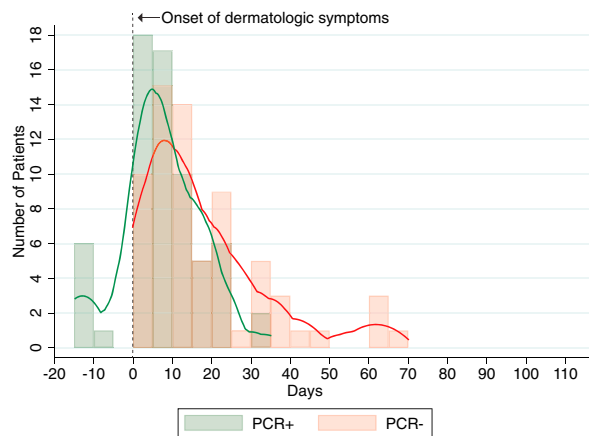


All dermatologic manifestations



Pernio only

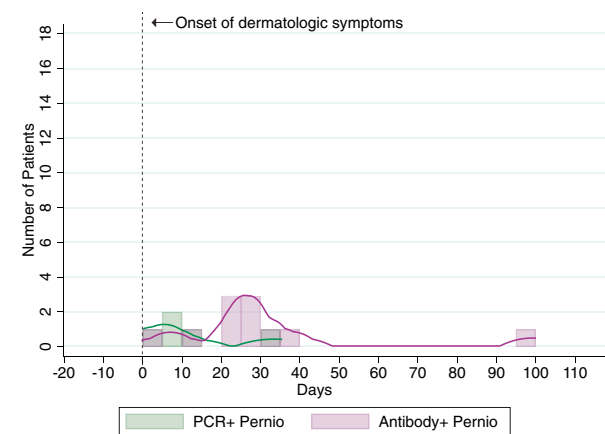
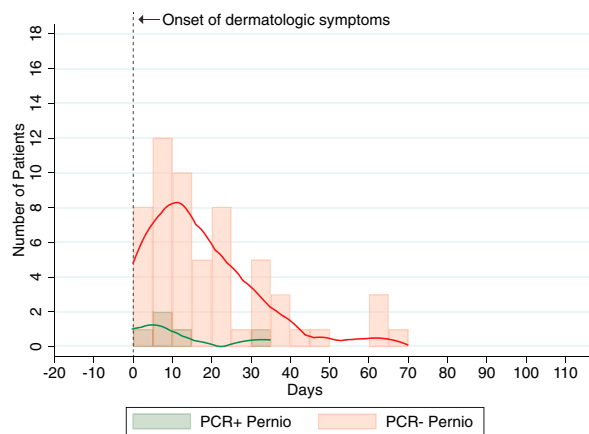


Fig 1. Distribution of positive and negative coronavirus disease 2019 test results in relation to onset of dermatologic symptoms, including polymerase chain reaction–positive/negative test results and polymerase chain reaction–positive/antibody-positive test results. Individual cases graphed as 5-day bins, defined by date of laboratory testing. *PCR*, Polymerase chain reaction.

REFERENCES

- Freeman EE, McMahon DE, Lipoff JB, et al. The spectrum of COVID-19-associated dermatologic manifestations: an international registry of 716 patients from 31 countries. *J Am Acad Dermatol.* 2020;83(4):1118-1129.
- Hubiche T, Le Duff F, Chiaverini C, Giordanengo V, Passeron T. Negative SARS-CoV-2 PCR in patients with chilblain-like lesions. *Lancet Infect Dis.* [https://doi.org/10.1016/S1473-3099\(20\)30518-1](https://doi.org/10.1016/S1473-3099(20)30518-1).
- Freeman EE, McMahon DE, Fitzgerald ME, et al. The AAD COVID-19 Registry: crowdsourcing dermatology in the age of COVID-19. *J Am Acad Dermatol.* 2020;83(2):509-510.
- Sethuraman N, Jeremiah SS, Ryo A. Interpreting diagnostic tests for SARS-CoV-2. *JAMA.* 2020;323(22):2249-2251.
- Robbiani DF, Gaebler C, Muecksch F, et al. Convergent antibody responses to SARS-CoV-2 in convalescent individuals. *Nature.* 2020;584(7821):437-442.

<https://doi.org/10.1016/j.jaad.2020.09.007>

Chilblain-like lesions and COVID-19 infection: A prospective observational study at Spain's ground zero



To the Editor: Chilblain-like lesions (CBL) have been related to severe acute respiratory coronavirus 2 (SARS-CoV-2) infection,¹ although solid microbiological confirmation is still lacking.

We present a prospective cohort study of 37 patients (median age, 14 years) presenting new-onset CBL during the COVID-19 outbreak in Spain that included (1) SARS-CoV-2 testing (nasopharyngeal polymerase chain reaction [PCR] and serologies) and immunologic profiles for all patients, (2) custom recall antigen experiments and

intracellular cytokine production evaluation in selected cases, and (3) skin biopsy for histopathology and immunochemistry (11 samples) and SARS-CoV-2 PCR and electron microscopy (3 cases) (Supplemental Tables I-IV; available via Mendeley at <https://doi.org/10.17632/vgvxtcb82c.1>).

CBLI mainly affected the toes (Table 1), with other features including dusky erythematodematosus changes on the dorsal surfaces of the toes and fingers (24.32%), purpuric macules (37.83%), and blisters (10.81%). Two patients presented with more obvious signs of distal skin ischemia (Supplemental Figs 1-3; available via Mendeley at <https://doi.org/10.17632/vgvxtcb82c.1>). In most cases, the lesions fully/partially remitted with topical therapy or no therapy. Only 1 patient presented with signs of retinal vasculitis. Vascular pulses and Doppler ultrasonography showed normal blood flows in the entire series. All biopsy specimens were consistent with pernio, and 54.5% showed complement C3d and C4d deposition around small vessels (Supplemental Fig 4; available via Mendeley at <https://doi.org/10.17632/vgvxtcb82c.1>). Nasopharyngeal PCR had positive results in 8.1%, and SARS-CoV-2 serology results were positive in just 8.1% of patients. Recall antigen assays showed positive responses in the 3 patients who underwent them (2 with negative SARS-CoV-2 serologies). Five of the 37 patients presented mild anticardiolipin titer elevation. Interferon (IFN) alfa levels were increased in only 1 of 24 tested patients, whereas the rest of the cytokines remained within normal or undetectable levels. No virus was detected on electron microscopy or PCR testing in skin samples.

Our patients presented with CBLI in striking parallel to the rise and fall of the COVID-19 pandemic in Madrid, but approximately 2 weeks later (Fig 1). The low proportion of positive SARS-CoV-2 serology test results would argue against the idea of a causal relationship between CBLI and SARS-CoV-2 infection. Lack of serologic test accuracy and a more prominent innate immune response might explain this discrepancy.² However, our preliminary results with SARS-CoV-2 assays suggest that patients could have been exposed to SARS-CoV-2 despite negative routine serologic test results. These patients might have had mild SARS-CoV-2 infection, although the upregulation of the type I IFN pathway could have resulted in the onset of CBLI in genetically predisposed patients. The lower rate of measured IFN alfa could be due to the fact that we measured it in a late phase of infection, according to PCR test results.

Table 1. Summary of demographic and clinical features of the patients presenting chilblain-like lesions (N = 37)

Sex, n (%)	
Female	20 (54.05)
Male	17 (45.95)
Mean age, y, mean \pm SD	22.08 \pm 15.46
Median age, y	14
Latency between systemic symptoms and skin lesions, days	21.76 \pm 23.01
Affected areas, n (%)	
Toes only	15 (40.55)
Fingers only	10 (27.03)
Toes and sides of feet	7 (18.92)
Toes and heels	2 (5.40)
Toes and fingers	2 (5.40)
Toes, fingers, and sides of feet	1 (2.70)
Associated signs and symptoms, n (%)	
Purpuric macules	14 (37.83)
Erythema	6 (16.21)
Pruritus	5 (13.51)
Cold skin	5 (13.51)
Blisters	4 (10.81)
Pain	3 (8.10)
Edema	3 (8.10)
Ulceration and/or necrosis	2 (5.40)
History of systemic symptoms, n (%)	17 (45.95)
Evolution of the lesions (+2 weeks), n (%)	
Complete resolution	16 (43.24)
Partial resolution	14 (37.84)
Persistence	4 (10.81)
Worsening	3 (8.11)
Prescribed therapy, n (%)	
None	24 (64.86)
Topical corticosteroids	8 (21.63)
Oral corticosteroids	1 (2.70)
Pentoxifylline	4 (10.81)

SD, Standard deviation.

The exact role of SARS-CoV-2 in the development of CBLI, if any, remains unclear.³ We were unable to detect the virus in skin samples; however, the SARS-CoV-2 spike protein has been shown in the endothelial and epithelial cells of eccrine glands.⁴ Additionally, immune complex deposition can lead to tissue injury through various mechanisms, including complement activation, which could contribute to their pathogenesis.⁵

In conclusion, if CBLI were secondary to SARS-CoV-2, absence of a more evident humoral response would be highlighted. Recall antigen assays could help clarify this association.

Marta Feito-Rodríguez, PhD,^a Ander Mayor-Ibarguren, MD,^a Carmen Cámara-Hijón,

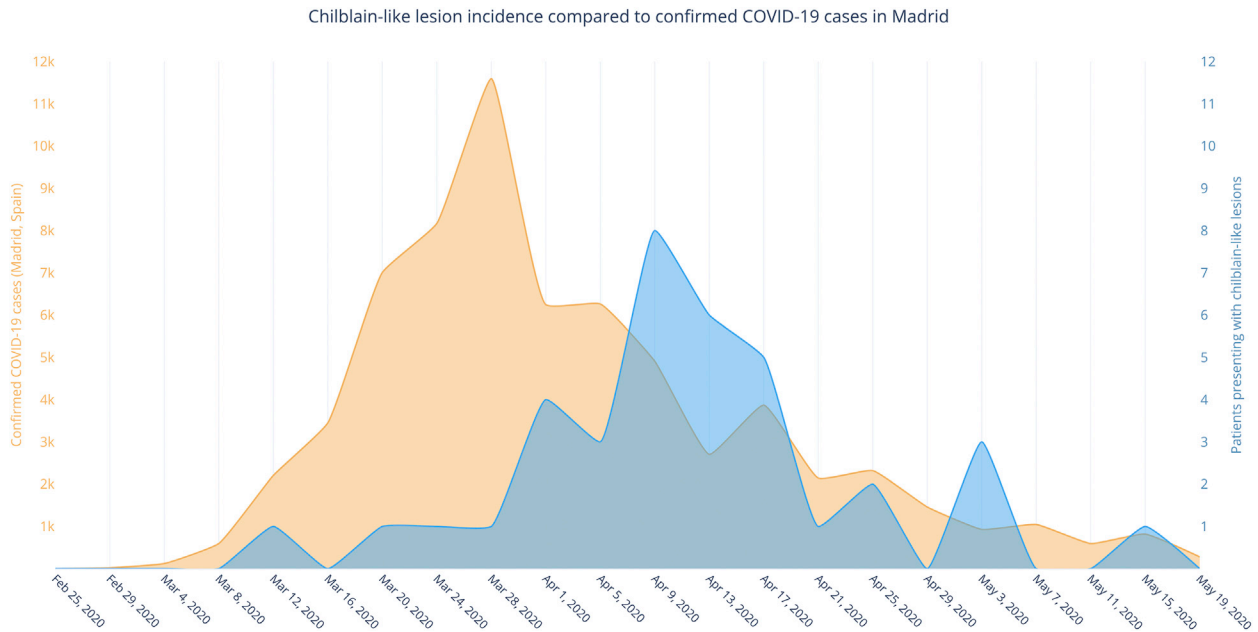


Fig 1. Chilblain-like lesions: the incidence at our center compared with confirmed COVID-19 cases over time in Madrid.

PhD,^b Dolores Montero-Vega, MD,^c Guillermo Servera-Negre, MD,^a Elena Ruiz-Bravo, MD,^d Pilar Nozal, MD,^b José Luis Rodríguez-Peralto, PhD,^e Ana Belén Engueta, PhD,^e Luz Yadira Bravo-Gallego, MD,^b Marí Granados-Fernández, MD,^f Celia Fernández-Alcalde, MD,^f Álvaro Fernández-Heredero, MD,^g Marina Alonso-Riaño, MD,^e Víctor Jiménez-Yuste, PhD,^b Almudena Nuño-González, PhD,^a Raúl De Lucas-Laguna, MD,^a Eduardo López-Granados, PhD,^b and Pedro Herranz-Pinto, PhD^a

From the Department of Dermatology, La Paz University Hospital, Madrid, Spain^a; Department of Clinical Immunology, La Paz University Hospital, Madrid, Spain^b; Department of Microbiology, La Paz University Hospital, Madrid, Spain^c; Department of Pathology, La Paz University Hospital, Madrid, Spain^d; Department of Pathology, Doce de Octubre University Hospital, Madrid, Spain^e; Department of Ophthalmology, La Paz University Hospital, Madrid, Spain^f; Department of Vascular Surgery, La Paz University Hospital, Madrid, Spain^g; and Department of Hematology, La Paz University Hospital, Madrid, Spain.^b

Funding sources: None.

Conflicts of interest: None disclosed.

IRB approval status: Reviewed and approved by the IRB of La Paz University Hospital, Madrid, Spain.

Reprints not available from the authors.

Correspondence to: Marta Feito-Rodríguez, PhD, Department of Dermatology, Hospital Universitario La Paz, Paseo de la Castellana 261, 28046 Madrid, Spain

E-mail: marta8marta@hotmail.com

REFERENCES

- Colmenero I, Santonja C, Alonso-Riaño M, et al. SARS-CoV-2 endothelial infection causes COVID-19 chilblains: histopathological, immunohistochemical and ultrastructural study of seven paediatric cases. *Br J Dermatol.* 2020;183(4):729-737.
- Netea MG, Joosten LAB. Trained immunity and local innate immune memory in the lung. *Cell.* 2018;175:1463-1465.
- Kanitakis J, Lesort C, Danset M, Jullien D. Chilblain-like acral lesions during the COVID-19 pandemic ("COVID toes"): histologic, immunofluorescence and immunohistochemical study of 17 cases. *J Am Acad Dermatol.* 2020;83:870-875.
- Torrelo A, Andina D, Santonja C, et al. Erythema multiforme-like lesions in children and COVID-19. *Pediatr Dermatol.* 2020;37:442-446.
- Rojko JL, Evans MG, Price SA, et al. Formation, clearance, deposition, pathogenicity, and identification of biopharmaceutical-related immune complexes: review and case studies. *Toxicol Pathol.* 2014;42:725-764.