

## Oral syphilis

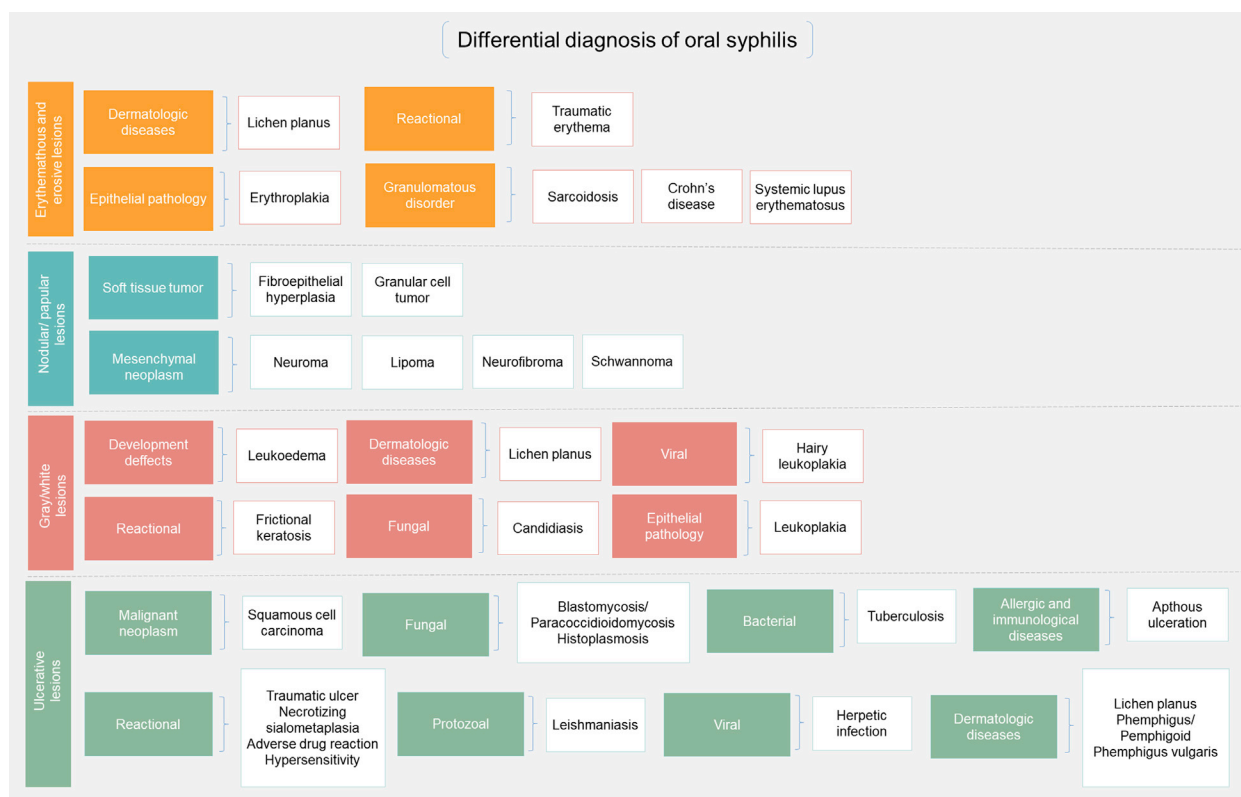


*To the Editor:* Lampros et al<sup>1</sup> draw attention to the difficulty of diagnosing the oral manifestations of secondary syphilis in a well-documented series. However, we would like to highlight the variable spectrum of lesions in oral syphilis, which can mimic other groups of diseases. Providers, including dermatologists, otolaryngologists, and dentists, should be familiar with the oral manifestations of syphilis and be prepared to include it in the setting of differential diagnosis of atypical oral lesions, avoiding misdiagnosis or underdiagnosis.

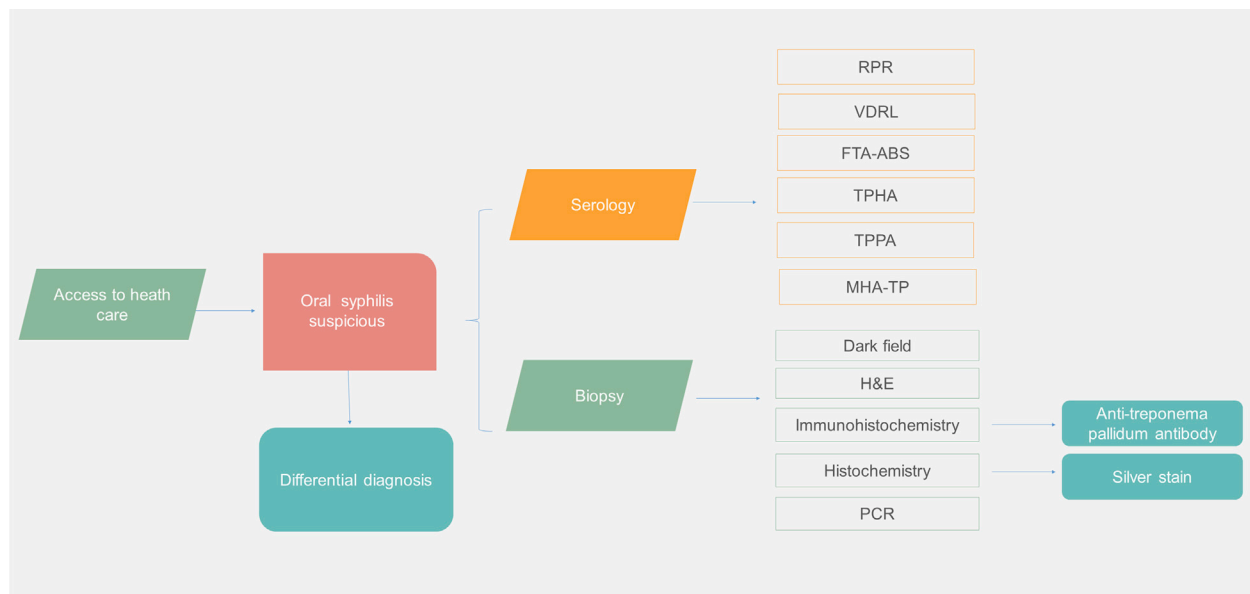
Syphilis can be categorized as congenital or acquired. The latter form is classified as primary, secondary, latent, and tertiary, depending on the time elapsed after exposure.<sup>2</sup> Primary syphilis is characterized by a chancre, a single, usually ulcerated oral lesion with a yellow transudate, with base infiltration and hardened high margins. Erythema, edema, and petechial hemorrhage may also occur. The lesion is often painless and is associated with nontender regional lymphadenopathy. It becomes clinically evident 3 to 90 days after the initial exposure. The vermillion and mucosa of the lips and the dorsum and lateral border of the tongue are the most common locations.<sup>2,3</sup> Secondary-stage

oral lesions are typically painful and multiple, and they may be accompanied by cutaneous eruptions; the duration varies from 4 to 10 weeks. In this stage, the 2 most common oral lesions are enanthem and mucous patches, the latter being the most frequent. Mucous patches are oval or serpiginous, slightly elevated erosions, with the presence of fissures or shallow ulcers with an erythematous border. There are overlying silvery gray or white membranous exudates. Multiple sites may be involved, including the soft palate, tongue, and buccal mucosa.<sup>2,3</sup> Tertiary syphilis is a multiorgan disease stage characterized by a painless localized granuloma that presents as a hardened, nodular, or ulcerated lesion that usually affects the hard palate or the dorsum of the tongue. There may be eventual bone destruction, palatal perforation, and oronasal fistulas.<sup>2</sup> Thus, the differential diagnosis of oral syphilis must consider a myriad of erythematous and erosive lesions, nodular/papular lesions, gray/white lesions, and ulcerative lesions (Fig 1).

Efforts to identify *Treponema pallidum* involve several detection approaches (Fig 2). Serologic studies continue to be the criterion standard.<sup>1-3</sup> Silver staining or immunohistochemistry should be used for tissue sections because histopathologic findings are nonspecific and mimic other conditions.



**Fig 1.** Differential diagnosis of oral syphilis.



**Fig 2.** Syphilis detection methods. *FTA-ABS*, fluorescent treponemal antibody-absorption; *H&E*, hematoxylin and eosin; *MHA-TP*, microhemagglutination assay for *Treponema pallidum*; *PCR*, polymerase chain reaction; *RPR*, rapid plasma reagin; *TPHA*, *T pallidum* hemagglutination assay; *TPPA*, *T pallidum* particle agglutination assay; *VDRL*, venereal disease research laboratory.

Syphilis rates are known to have varied widely across different countries and populations over the past 100 years, contributing to this concept of a sudden resurgence.<sup>4</sup> Although rates dropped worldwide in the post-penicillin era after 1945, they have remained, until recently, much higher in Sub-Saharan Africa compared to other regions.<sup>4</sup> This occurrence is attributed to the fact that in low- and middle-income countries, individuals start their sexual lives earlier and, therefore, are more exposed to sexually transmitted infections.<sup>3</sup> Moreover, individuals with many sexual partners and who maintain sexual promiscuity are particularly affected.<sup>3,5</sup> HIV-syphilis coinfection has been extensively reported. Of note, since 2000, there has been an alarming resurgence of syphilis in the United States,<sup>5</sup> with oral manifestations also occurring at high frequency.<sup>3</sup> Nevertheless, the number of positive syphilis cases documented elsewhere may be underestimated.<sup>3</sup>

José Alcides Almeida de Arruda, DDS, MSc, Isabella Bittencourt do Valle, DDS, MSc, Ricardo Alves Mesquita, DDS, PhD, and Tarcília Aparecida Silva, DDS, PhD

From the Department of Oral Surgery and Pathology, School of Dentistry, Universidade Federal de Minas Gerais, Belo Horizonte, Minas Gerais, Brazil.

Funding sources: None.

Conflicts of interest: None disclosed.

IRB approval status: Not applicable.

Reprint requests: Tarcília Aparecida Silva, DDS, PhD, Department of Oral Surgery and Pathology, School of Dentistry, Universidade Federal de Minas Gerais, Av. Pres. Antônio Carlos, 6627, Room 3204, Belo Horizonte, MG, Brazil, CEP: 31.270-910

E-mail: [silva.tarcilia@gmail.com](mailto:silva.tarcilia@gmail.com); [tarcilia@ufmg.br](mailto:tarcilia@ufmg.br)

#### REFERENCES

- Lampros A, Seta V, Gerhardt P, Isnard C, Husson C, Dupin N. Oral forms of secondary syphilis, an illustration of the pitfalls set by the great imitator. *J Am Acad Dermatol*. 2021;84:348-353.
- Leão JC, Gueiros LA, Porter SR. Oral manifestations of syphilis. *Clinics (Sao Paulo)*. 2006;61(2):161-166.
- Schuch LF, da Silva KD, de Arruda JAA, et al. Forty cases of acquired oral syphilis and a review of the literature. *Int J Oral Maxillofac Surg*. 2019;48(5):635-643.
- Kenyon CR, Osbak K, Tsoumanis A. The global epidemiology of syphilis in the past century—a systematic review based on antenatal syphilis prevalence. *PLoS Negl Trop Dis*. 2016;10(5):e0004711.
- Schmidt R, Carson PJ, Jansen RJ. Resurgence of syphilis in the United States: an assessment of contributing factors. *Infect Dis (Auckl)*. 2019;12:1178633719883282.

<https://doi.org/10.1016/j.jaad.2020.09.067>