

Panoramic trichoscopy



Leonardo Spagnol Abraham, MD, MSc,^a Sofia Sales Martins, MD,^b
Rodrigo Pirmez, MD,^c and Bruna Duque-Estrada, MD^c
Brasília and Rio de Janeiro, Brazil

Key words: alopecia; dermoscopy; follow-up; frontal fibrosing alopecia; hair loss; hairline; image enhancement; mobile phone; smartphone.

Abbreviation used:

FFA: frontal fibrosing alopecia

TECHNOLOGY CHALLENGE

Trichoscopy is a useful tool in the diagnosis of hair loss and follow-up of patients. A current limitation of the method is that only small portions of the scalp can be photographed.¹ This may pose some difficulty when trying to analyze large areas, such as the entire hairline in patients with frontal fibrosing alopecia (FFA), or when attempting to compare the same field of view in posterior evaluations. To overcome this problem, we propose panoramic trichoscopy: the use of a smartphone camera in panorama mode attached to a dermatoscope.

SOLUTION

To perform panoramic trichoscopy, first attach a handheld dermatoscope to a smartphone. Select the panorama (or similar) mode with the camera app of the phone. To obtain the best image in FFA, tie the hair back into a ponytail, hold the hairline with a flexible comb, and start scanning the hairline. A steady and continuous movement of the hand is necessary to avoid the formation of visual artifacts. Panoramic trichoscopy allows visually matching of hair shafts in before and after pictures (Fig 1), enhancing the analysis of disease activity signs and hair loss in patient follow-up.² We have successfully used this technique to evaluate the hairline in FFA, but it can be used in other areas, such as the eyebrows and in patients with other types of hair loss.

REFERENCES

1. Dellatorre G, Gadens GA. Wide area digital dermoscopy. *J Am Acad Dermatol*. 2019;80(6):e153.
2. Cervantes J, Miteva M. Distinct trichoscopic features of the sideburns in frontal fibrosing alopecia compared to the frontotemporal scalp. *Skin Appendage Disord*. 2018;4(1):50-54.

From the Hospital Regional da Asa Norte (HRAN), Brasília^a; Universidade de Brasília^b; and Instituto de Dermatologia Prof Rubem David Azulay, Rio de Janeiro.^c

Funding sources: None

Conflicts of interest: None disclosed.

Reprints not available from the authors.

Correspondence to: Leonardo Spagnol Abraham, MD, MSc, SEPS 709/909, Sala S13, Asa Sul, Brasília-DF, Brazil. E-mail: leosabraham@gmail.com.

J Am Acad Dermatol 2021;84:e85-6.

0190-9622/\$36.00

© 2019 by the American Academy of Dermatology, Inc.

<https://doi.org/10.1016/j.jaad.2019.09.041>

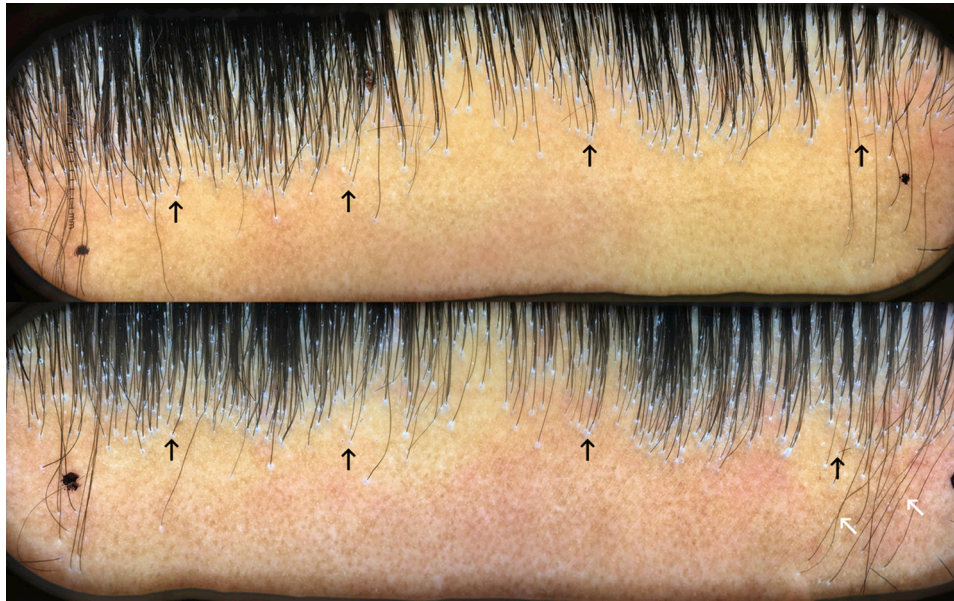


Fig 1. Panoramic trichoscopy of the hairline in a patient with FFA. Pictures taken on 2 different days with an iPhone 6s (iOS version 12.2; Apple, Cupertino, CA) attached to a DermLite Foto X (3Gen Inc, San Juan Capistrano, CA). This technique allows precisely matching trichoscopy images (black arrows) of the same area in the follow-up. Of note, artifacts may eventually appear as a result of the sliding movement, which we named “wave-like hairs” (white arrow) and should not be confused with pili torti. FFA, Frontal fibrosing alopecia.