

# Age-Related Macular Degeneration



Catherine J. Thomas, MD, MHA, MS, Rukhsana G. Mirza, MD, MS,  
Manjot K. Gill, MD, FRCS (C)\*

## KEYWORDS

- Drusen • Choroidal neovascularization (CNV)
- Vascular endothelial growth factor (VEGF)
- Neovascular (exudative, wet) age-related macular degeneration
- Nonneovascular (nonexudative, dry) age-related macular degeneration
- Geographic atrophy

## KEY POINTS

- Age-related macular degeneration is a leading cause of irreversible vision loss globally.
- Dilated fundus examination should be performed on individuals over the age of 55 to screen for age-related macular degeneration.
- Age, smoking history, hyperlipidemia, family history, and ethnicity are all risk factors for developing age-related macular degeneration.
- Ophthalmologists generally do not advise cessation of systemic antiplatelet/anticoagulation therapies, but discussion with the prescribing physician may be warranted in certain clinical scenarios.
- There is no cure for age-related macular degeneration; however, intravitreal injections are the gold-standard treatment for advanced neovascular disease.

## INTRODUCTION

Age-related macular degeneration (AMD) affects millions of people worldwide and is a leading cause of blindness globally.<sup>1</sup> There are 2 main types of AMD, neovascular and nonneovascular AMD, which can be further classified based on specific features of the disease. Nonneovascular AMD (“dry” AMD) accounts for almost 80% to 85% of all cases and generally carries a more favorable visual prognosis. Neovascular AMD (“wet” AMD) affects the remaining 15% to 20% and accounts for approximately 80% of severe vision loss as a result of AMD.<sup>2</sup>

---

Department of Ophthalmology, Feinberg School of Medicine, Northwestern University, 645 North Michigan Avenue, Suite 440, Chicago, IL 60611, USA

\* Corresponding author.

E-mail address: [mgill@nm.org](mailto:mgill@nm.org)

Twitter: [@CJThomasMD](https://twitter.com/CJThomasMD) (C.J.T.); [@rg-mirza](https://twitter.com/rg-mirza) (R.G.M.); [@ManjotGillMD](https://twitter.com/ManjotGillMD) (M.K.G.)

Med Clin N Am 105 (2021) 473–491

<https://doi.org/10.1016/j.mcna.2021.01.003>

[medical.theclinics.com](https://www.medical.theclinics.com)

0025-7125/21/© 2021 The Authors. Published by Elsevier Inc. This is an open access article under the CC BY-NC-ND license (<http://creativecommons.org/licenses/by-nc-nd/4.0/>).

## BACKGROUND

AMD involves pathologic changes to the deeper retinal layers of the macula and surrounding vasculature resulting in central vision loss. The accumulation of retinal deposits, called drusen, are a hallmark clinical finding in AMD (described in later discussion) and may be the first sign of the “dry” form of the disease. Dry AMD is the most common morphologic type and may progress to “wet” or neovascular AMD, whereby central choroidal neovascular membranes (CNV) can lead to hemorrhaging and exudation in the retina and profound vision loss. These membranes form as a result of abnormal vascular proliferation or angiogenesis owing to the release of vascular endothelial growth factor (VEGF). The treatment of choice for these lesions is intravitreal injections with anti-vascular endothelial growth factor (anti-VEGF) therapy, which has revolutionized the management of advanced AMD. Another variant of late AMD is the “dry” or nonexudative type, whereby geographic atrophy or atrophic scars develop in the macula. These atrophic lesions do not respond to anti-VEGF therapy and have similarly devastating permanent effects on visual function if involving the fovea.

AMD is the leading cause of irreversible blindness in the developed world in individuals over the age of 60.<sup>3</sup> Consequences of poor vision include increased risk of fall, depression, and the need for long-term care if unable to perform activities of daily living, such as dressing, eating, and working.<sup>4</sup> The direct cost of AMD to the North American health care system was more than 250 billion dollars in 2008 with a steady increase in the number of new cases annually.<sup>5</sup> The aging population indicates that these numbers will continue to increase at an exponential rate. The visual implications of AMD can exacerbate the already challenging health-related concerns and comorbidities of the elderly and significantly impact quality of life. Understanding the basic signs and symptoms of AMD is useful in counseling patients on when to seek ophthalmologic care and prevent further vision loss.

Although there is no cure for AMD, preventative and proactive measures are crucial. Disease progression can be slowed by addressing certain modifiable risk factors, such as smoking, diet, and cardiovascular disease.<sup>6</sup> The Age-Related Eye Disease Study (AREDS) led to the development of a specific combination of vitamin supplementation for the prevention of disease progression for patients with specific characteristics of AMD.<sup>7</sup> There are several subtypes of AMD, not all of which respond to anti-VEGF therapy or meet criteria for recommending AREDS vitamins. The prognosis is variable depending on the stage of the disease. Timely referral for ophthalmologic care is important for the treatment and prevention of the long-term sequelae of AMD.

## EPIDEMIOLOGY

Almost 200 million people worldwide have some form of AMD.<sup>3</sup> In the United States, the numbers exceed 10 million and are steadily increasing.<sup>5</sup> Age is the main risk factor for developing AMD; however, cigarette smoking, increased body mass index, hypertension, hyperlipidemia, and genetics are other important risk factors.<sup>8,9</sup> The US Twin Study of Age-Related Macular Degeneration examined cigarette smoking and omega-3 fatty acid intake in elderly male twins and demonstrated that both current smokers and those with a past history of smoking had an almost 2-fold increased risk of developing AMD.<sup>10</sup> Other studies suggest a 4-fold increase in the risk of developing AMD for smokers.<sup>11</sup> The Rotterdam Study demonstrated that former smokers are at an increased risk even after 20 years of abstinence from cigarettes.<sup>12</sup> Conversely, dietary omega-3 fatty acids and omega-6 fatty acids most commonly found in fish were found to be protective against AMD.<sup>10</sup> Several studies have shown an increased risk of AMD

in individuals with hypertension possibly because of the impact of systolic blood pressure on choroidal blood flow.<sup>13</sup> Hyperlipidemia as a risk factor for AMD has also been widely examined with some investigators, suggesting that elevated high-density lipoprotein and high cholesterol intake may be associated with neovascular AMD and elevated serum cholesterol with the development of geographic atrophy.<sup>13</sup> Studies on gender predilection have been inconclusive, although a female preponderance for AMD has been reported in the literature.<sup>14</sup>

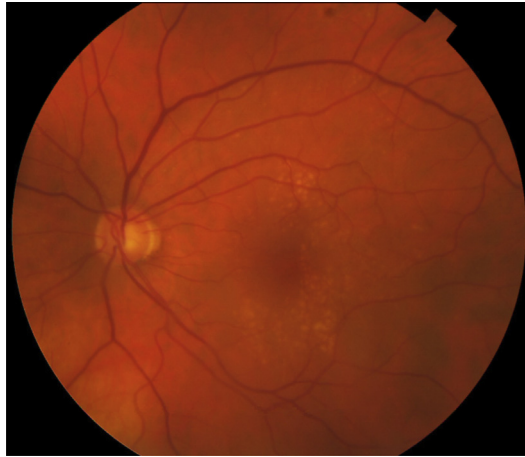Wong and colleagues<sup>3</sup> reported the prevalence of AMD across ethnicities. Findings showed that those of European ancestry were more likely to develop early, intermediate, and advanced AMD compared with Asians and Africans. Europeans were also more likely to develop geographic atrophy than Asians, Hispanics, and Africans.<sup>3</sup> Although Hispanics are considered lower risk for AMD compared with whites, the Los Angeles Latino Eye Study found the prevalence of AMD to be greater than 8% in Latinos over 80 years old.<sup>15</sup>

## SIGNS AND SYMPTOMS

There may be minimal to no symptoms associated with early and intermediate AMD whereby there are predominantly small- and medium-sized drusen deposited in the macula. Patients may note subtle changes, such as distortion (metamorphopsia), increased blurring at near, particularly while reading, and decreased contrast sensitivity. The presence of neovascular AMD generally leads to more rapid and profound visual symptoms that may be acute or gradually worsen. These symptoms include severe distortion and/or a large central scotoma or blind spot owing to retinal hemorrhage and fluid accumulation. Patients may complain of difficulty recognizing faces. Patients with geographic atrophy may also note similar symptoms of distortion and central scotoma. The Amsler grid<sup>16</sup> was developed as a self-monitoring tool for patients to test each eye independently, looking for distortion or the presence of a scotoma that may indicate progression from dry to wet or neovascular AMD.

## OVERVIEW AND CLASSIFICATION

AMD is defined by the presence of specific changes in the macula particularly the deposition of focal yellow extracellular deposits known as drusen. The presence of macular drusen may be the first sign of the dry form of the disease, and patients may often be asymptomatic (**Fig. 1**). The size and number of drusen contribute to the risk of disease progression. Small drusen are classified as less than 63  $\mu\text{m}$  in diameter, medium drusen 63 to 124  $\mu\text{m}$ , and large drusen  $\geq 125 \mu\text{m}$ .<sup>17</sup> Drusen may also be described as hard or soft, whereby hard drusen have discrete borders and are often small. Soft drusen have less distinct borders and may become confluent to form larger, more high-risk lesions.<sup>17</sup> The Beaver Dam Eye Study demonstrated an incidence close to 30% for the development of advanced AMD in patients with the presence of larger soft drusen.<sup>18,19</sup> The classification of AMD is divided into early, intermediate, and advanced nonneovascular AMD or advanced neovascular AMD (**Table 1**). The presence of small macular drusen or few medium-sized drusen poses a lower risk in terms of progression to advanced AMD and may not lead to vision loss. Pigmentary changes in the macula may also be a sign of early disease and serve as a predictor of progression to more advanced AMD.<sup>18</sup> Many medium-sized drusen or 1 large drusen, defined as intermediate AMD, confers a higher risk for progression to advanced disease with more judicious monitoring recommended (**Fig. 2**).



**Fig. 1.** Macular drusen of the left eye. (Image courtesy of R. Mirza, M.D.)

### ***Wet Versus Dry Age-Related Macular Degeneration***

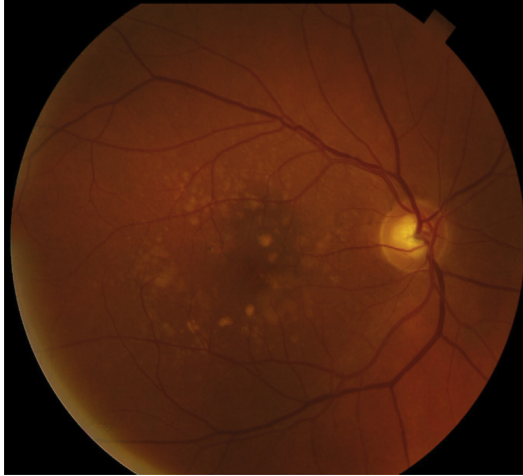
There are certain morphologic features to further categorize AMD based on the presence or absence of abnormal CNV proliferation or the presence or absence of atrophic lesions referred to as geographic atrophy. “Dry” (nonexudative or nonneovascular) AMD refers to both the presence of drusen in either early or intermediate disease and also the atrophic variant of dry AMD whereby geographic atrophy is the predominant feature (Fig. 3). The presence of geographic atrophy in the macula is categorized as advanced dry AMD when it involves the fovea and may lead to progressive permanent vision loss, as these lesions often advance over time. Atrophic changes occur because of loss of outer retinal tissue and the surrounding vascular network, specifically the retinal pigment epithelial (RPE) layer, Bruch membrane, and the choriocapillaris. Advanced dry AMD is thought to be due in part to inflammatory and degenerative insults that lead to subsequent photoreceptor loss.<sup>20</sup>

“Wet” (exudative or neovascular) AMD is the most common form of advanced AMD.<sup>18</sup> The neovascularization that develops leads to hemorrhaging and leakage of fluid in the inner retinal layers or subretinal space, ultimately causing fibrosis and permanent vision loss in the absence of treatment (Figs. 4 and 5). The early or intermediate forms of dry AMD may have a more favorable prognosis if the disease course

**Table 1**

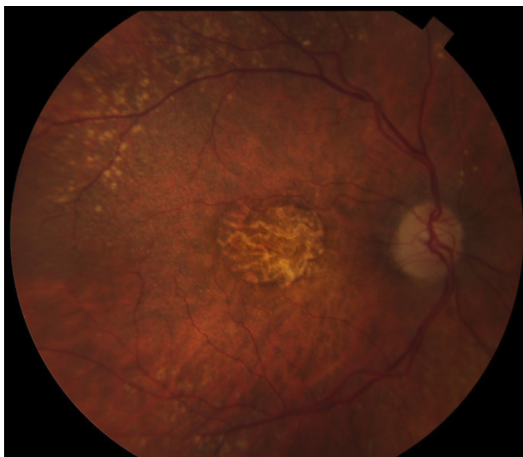
**Classification of age-related macular degeneration based on the Age-Related Eye Disease Study<sup>19</sup>**

<b>Early AMD</b>	<b>Intermediate AMD</b>	<b>Advanced Nonneovascular AMD (Advanced Dry AMD)</b>	<b>Advanced Neovascular AMD (Wet AMD)</b>
Presence of small drusen or few medium-sized drusen in 1 or both eyes Pigmentary changes	Presence of many medium-sized drusen, 1 large drusen, and/or geographic atrophy not involving the central macula (fovea)	Geographic atrophy involving the central macula or fovea	Choroidal neovascularization in 1 eye

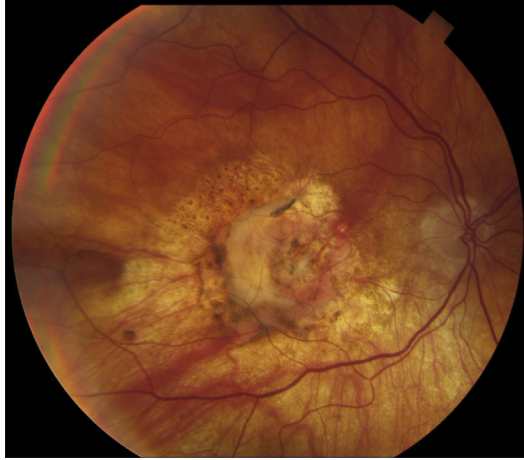

**Fig. 2.** Intermediate AMD. (Image courtesy of R. Mirza, M.D.)

remains stable. It is important to be aware that for all forms of dry AMD there is a 10% to 15% risk of progression to wet AMD<sup>21</sup> at some point throughout the disease course. There may also be overlap in both atrophic and neovascular features, where wet or neovascular AMD progresses to geographic atrophy and vice versa.<sup>22</sup> Many practitioners and patients are concerned about continuing systemic anticoagulation/antiplatelet medications in cases of neovascular AMD. An epidemiologic review demonstrated an increased risk of intraocular hemorrhage in those on systemic anticoagulants, specifically aspirin, clopidogrel, and warfarin; however, ophthalmologists do not advise cessation of these therapies, especially when used to treat life-threatening conditions.<sup>23</sup> A discussion may be warranted between the primary care



**Fig. 3.** Central geographic atrophy with drusen outside of the macula. (Image courtesy of R. Mirza, M.D.)

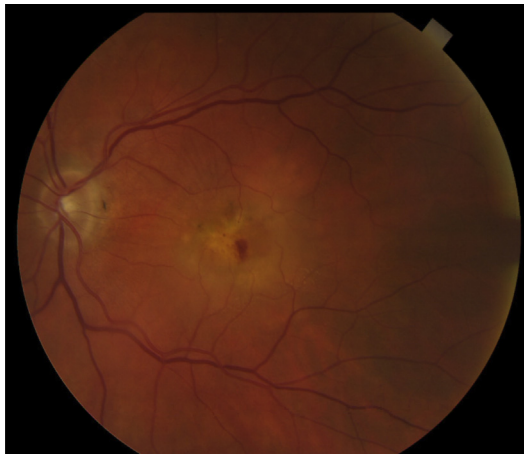


**Fig. 4.** Macular fibrosis and scar formation as a result of neovascular AMD. (Image courtesy of M. Gill, M.D.)

provider and the ophthalmologist in certain scenarios to evaluate the risks and benefit profile.

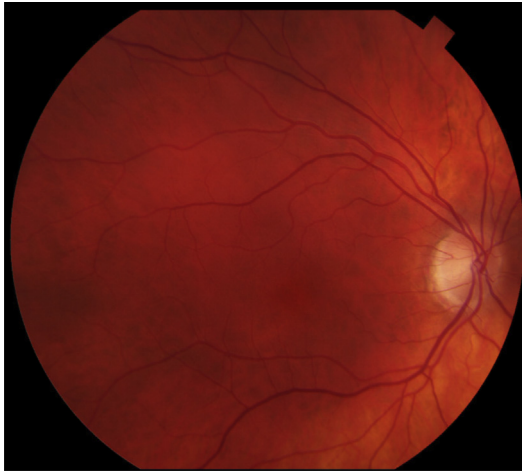
#### **PATHOPHYSIOLOGY**

The retina is the transparent central nervous system tissue lining the inner aspect of the back wall of the eye and is essential for vision. There are multiple layers and components of the retina, each serving different functions. The central portion of the retina, termed the macula, refers to the multilayered area responsible for the most detailed aspects of human vision. The center of the macula, the fovea, is essential for maintaining basic visual function necessary to perform daily activities, such as facial recognition, reading, and driving (**Fig. 6**). AMD primarily affects the outer retina, which includes the RPE, Bruch membrane, the choriocapillaris, and underlying choroid



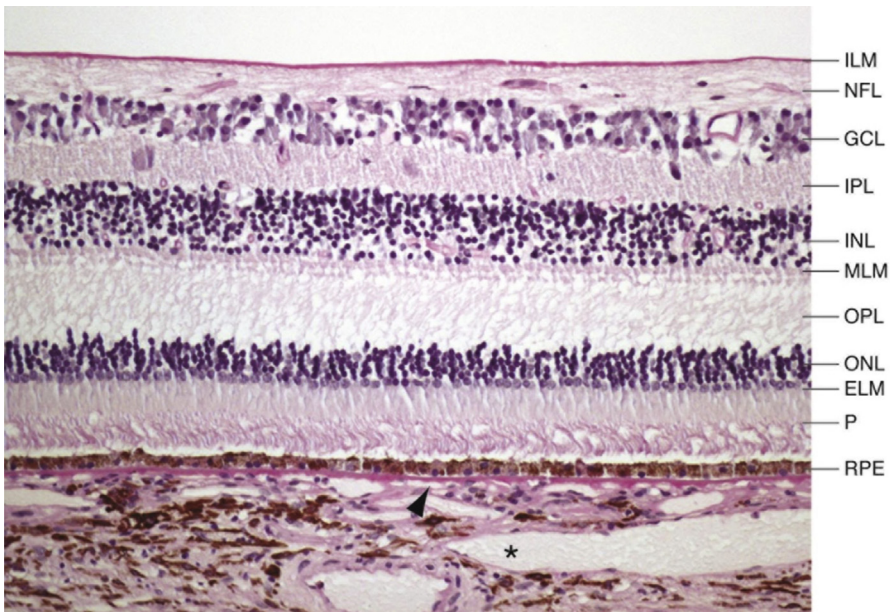
**Fig. 5.** Exudative AMD with hemorrhage and fluid accumulation involving the fovea. (Image courtesy of R. Mirza, M.D.)





**Fig. 6.** Normal fundus photo of the right eye. (Image courtesy of M. Gill, M.D.)

(**Fig. 7.**) The RPE maintains important homeostatic functions of the retina, including but not limited to nutrient absorption, phagocytosis, and electrolyte balance, whereas the choriocapillaris and choroid contain the rich vascular network that nourishes the outer layers of the retina.<sup>24</sup> Bruch membrane mediates interactions between the



**Fig. 7.** Normal layers of the retina (periodic acid-Schiff [PAS] stain). ELM, external limiting membrane; GCL, ganglion cell layer; ILM, internal limiting membrane; INL, inner nuclear layer; IPL, inner plexiform layer; MLM, middle limiting membrane; NFL, nerve fiber layer; ONL, outer nuclear layer; OPL, outer plexiform layer; P, photoreceptors (inner/outer segments) of rods and cones. Bruch membrane, arrowhead; choroid, asterisk. © American Academy of Ophthalmology.

RPE and choriocapillaris and plays an important role in the development of neovascular lesions in AMD. The RPE nourishes the photoreceptor layer, where the rods and cones perform the intricate phototransduction process essential to visual function.<sup>20</sup> The dysfunction and atrophy of the RPE present in AMD impact the health of the photoreceptor layer and interferes with phototransduction. Such dysfunction leads to disruption of signal transmission from the retina to the brain and subsequent vision loss. In addition, the choroidal vasculature is thought to be affected by microvascular insults that occur in certain systemic diseases, such as hypertension and hyperlipidemia.<sup>13</sup> These microvascular insults suggest both an ischemic and an inflammatory component influencing the pathophysiology of the disease.

Abnormal angiogenesis is mediated by VEGF and plays a critical role in the development of CNV in advanced neovascular AMD. The normal retinal circulation requires VEGF for healthy choroidal and retinal vasculature. The abnormal expression of specific VEGF subtypes is induced by hypoxia and leads to the proliferation of new blood vessels susceptible to leakage and bleeding characteristic of neovascular AMD.<sup>25</sup>

### **Genetics**

---

There are many genes linked to the development of AMD.<sup>26</sup> The complement factor H gene was the first identified gene for susceptibility to AMD, whereby disruption in complement-mediated regulatory function is thought to play a role in the formation of drusen.<sup>21</sup> The noncomplement mediated age-related maculopathy susceptibility 2 gene is also associated with the development of AMD. At this time, routine genetic testing is not currently recommended, as the results do not support altering current treatment guidelines for advanced AMD. In addition, there are few qualified testing centers, and more analysis is needed in order to appropriately interpret the results.<sup>27</sup> Genetics are likely to play an increasingly relevant role in AMD especially as the function of genetic testing and gene therapy evolves.

### **DIAGNOSIS**

Individuals over 55 years of age should have a dilated fundus examination to screen for macular degeneration.<sup>8</sup> In order to diagnose AMD, the examiner will evaluate the macula for deposits of drusen, pigmentary changes, geographic atrophy, hemorrhage, fluid, exudate, scar formation, and fibrosis. Attention is given to the size, number, and distribution of drusen. A complete eye examination is also performed to rule out other coexisting ocular pathologic conditions. The staging of the disease may largely be based on the examination; however, use of a variety of imaging techniques is now considered essential to correlate examination findings and guide management.<sup>28</sup> Technological advancements in ophthalmology continue to progress at an impressive pace with retinal imaging modalities evolving significantly in the past 30 years.

### **Imaging Modalities**

---

Fluorescein angiography (FA) has historically been the gold standard for assessing choroidal neovascularization in AMD. It is an invasive procedure whereby fluorescein dye is injected into the vein of a patient, and images of the chorioretinal circulation are taken over the course of several minutes that may detect the presence of leakage from different types of neovascular lesions.<sup>28</sup> Indocyanine green angiography (ICG) is a similar method that may be performed in certain scenarios. ICG involves the injection of indocyanine green, a dye that is useful in evaluating the choroidal circulation, whereby occult CNV lesions may be detected.



Optical coherence tomography (OCT) is a widely used, noninvasive tool that allows for an in-depth display of each of the retinal layers and has revolutionized the understanding and management of AMD.<sup>28</sup> OCT is comparable to ultrasound but uses light rather than sound waves<sup>29</sup> to provide a detailed cross-sectional image of the 10 retinal layers and underlying choroid, allowing for visualization of the specific layers impacted by AMD (Fig. 8). The images help to differentiate between wet and dry AMD and allow the physician to better characterize disease stage and CNV activity. OCT may show fluid within and beneath the retina that is found in wet macular degeneration and can be compared longitudinally to assess response to treatment and guide management (Figs. 9–11).

A more recent imaging modality includes optical coherence tomography angiography (OCT-A). OCT-A is a noninvasive advancement that allows for better visualization of the rich vascular network of the choroid. This technique aids in the understanding of the microvascular changes that occur in the presence of CNV lesions in neovascular AMD. OCT-A also serves as a tool that may allow for earlier detection of neovascularization with the goal of closer monitoring and earlier intervention when appropriate.<sup>30</sup> In many cases, OCT-A has replaced FA and ICG.

## MANAGEMENT

### *Laser Therapy*

Before 2000, thermal laser therapy was the mainstay of treatment of wet AMD. Argon-laser photocoagulation leads to regression of CNV with scar formation through the use of thermal energy to directly target neovascular lesions.<sup>31</sup> A limitation of focal laser is the occurrence of scotoma or permanent central vision loss in the treated area.

Around the year 2000, photodynamic therapy (PDT) became available. PDT involves the intravenous injection of a photosensitizing dye (verteporfin) that travels throughout the body and accumulates in CNV and upon treatment with longer wavelength infrared laser can induce closure of CNV lesions. PDT is still used today as an adjuvant in cases refractory to anti-VEGF alone.

### *Intravitreal Injections and Anti-Vascular Endothelial Growth Factor Agents*

The development of localized intravitreal treatment with anti-VEGF therapy has revolutionized the treatment of AMD in addition to other diseases, whereby angiogenic factors play a role, such as diabetic retinopathy, venous occlusive disease, and other causes of choroidal neovascularization. The injections can be done quickly and seamlessly in office and require little to no recovery time for the patient with minimal risks and few side effects. The technique allows for the safe and direct delivery of the

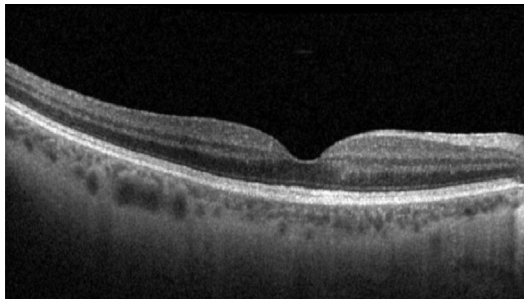
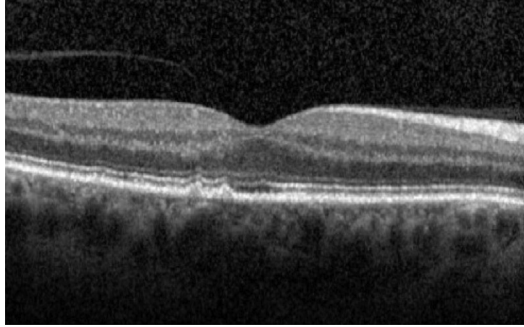


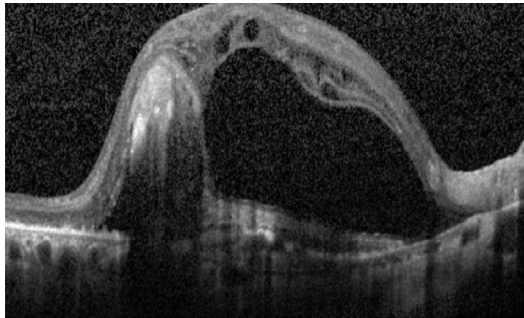
Fig. 8. Normal OCT of right eye showing intact retinal layers. (Image courtesy of M. Gill, M.D.)



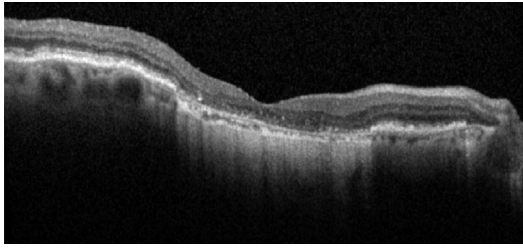
**Fig. 9.** Dry AMD with macular drusen. (Image courtesy of M. Gill, M.D.)

desired agent into the vitreous cavity using a small, 30-gauge needle through the pars plana, which lies 3 to 4 mm behind the limbus (**Fig. 12**). Topical anesthetic options are available for patient comfort, and povidone-iodine has proven to be safe and effective in the prevention of infection.<sup>32</sup> The volume of medication injected is generally 0.05 mL and is delivered in a prefilled syringe from the manufacturer or compounding pharmacy. Despite patients' perceptions and fears regarding intravitreal injections, most patients studied by Fallor and colleagues<sup>33</sup> thought that their vision was preserved and treatments were effective.

For wet AMD, anti-VEGF agents have proven to be beneficial in targeting CNV lesions and preserving vision.<sup>34</sup> VEGF is present throughout the body and required for normal angiogenesis. However, the pathologic upregulation of VEGF leads to leakage and neovascularization that develop in advanced AMD.<sup>25</sup> VEGF-A was one of the earliest mediators implicated in the development of CNV and an early target of anti-VEGF therapies. There are various isoforms of VEGF-A and additional angiogenic forms of VEGF, including VEGF-B and placental-like growth factor (PLGF). The 3 most widely used intravitreal agents for wet AMD include ranibizumab (Genentech), aflibercept (Regeneron), and bevacizumab (Genentech). Ranibizumab is a recombinant, humanized, monoclonal antibody fragment that neutralizes all forms of VEGF-A and was first approved for use in 2005. Aflibercept was Food and Drug Administration (FDA) approved in 2011 and is a VEGF-trap fusion protein that binds both VEGF-A and platelet-derived growth factor. Bevacizumab is a monoclonal



**Fig. 10.** OCT depicts neovascular AMD with significant intraretinal and subretinal fluid involving the macula and fovea with complete disruption of retinal architecture. (Image courtesy of M. Gill, M.D.)



**Fig. 11.** Geographic atrophy at the center of the macula with loss of outer retinal layers. (Image courtesy of R. Mirza, M.D.)

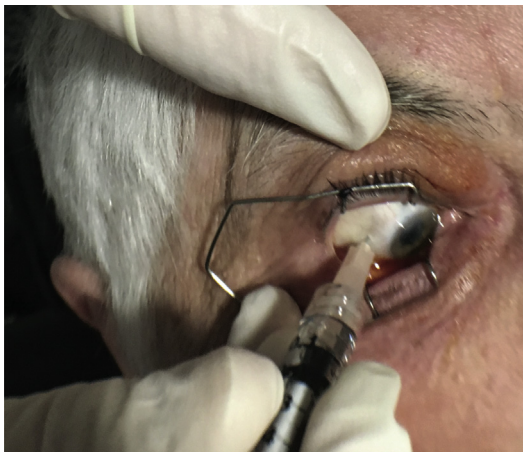antibody that binds to all VEGF-A isoforms and is used systemically in the treatment of colon cancer. Ranibizumab and aflibercept are both FDA approved for exudative AMD, while bevacizumab is used in an off-label manner and is a cost-effective alternative.

### ***Surgery***

Surgical excision of neovascular lesions was previously described as an option but has largely been abandoned because of current minimally invasive, more successful treatments as described above. In the 1990s, the Submacular Surgery Trials investigated outcomes in patients with neovascular AMD who underwent submacular surgery for hemorrhage owing to CNV lesions. The outcomes of the study showed no benefit in the group that underwent surgery versus observation alone and demonstrated an increased rate of complications in the surgery arm.<sup>35</sup>

### ***Trials***

There are several landmark clinical trials describing the efficacy of the 3 main anti-VEGF agents currently in use. MARINA (Minimally Classic/Occult Trial of the Anti-VEGF Antibody Ranibizumab in the Treatment of Neovascular AMD) and ANCHOR



**Fig. 12.** Intravitreal injection technique. This image was originally published in the Retina Image Bank Web site. John T. Thompson, MD. Intravitreal injection of anti-VEGF Drug. Retina Image Bank. 2017; Image Number 27125. © the American Society of Retina Specialists.

(Anti-VEGF Antibody for the Treatment of Predominantly Classic Choroidal Neovascularization in AMD) evaluated the efficacy of monthly injections of ranibizumab. Both studies were the first to demonstrate a significant improvement in vision with regularly dosed injections in patients with exudative AMD.

The Comparison of AMD Treatment Trial (CATT) study compared the efficacy of ranibizumab and bevacizumab for the treatment of exudative AMD as well as compared differing treatment strategies. Both agents showed equivalent outcomes in terms of final visual acuity. The 2-year CATT study also demonstrated that receiving injections at regular monthly intervals as opposed to as needed can result in slightly better visual outcomes.<sup>36</sup> The efficacy of aflibercept was evaluated in the VEGF Trap-Eye: Investigation of Efficacy and Safety in Wet AMD (VIEW 1, VIEW 2) and showed noninferiority to ranibizumab.<sup>37</sup>

### ***Newer Anti-Vascular Endothelial Growth Factor Considerations***

---

Brolucizumab is a single-chain antibody fragment that binds VEGF-A and was FDA approved for neovascular AMD in October 2019. The smaller molecular size is thought to penetrate tissue more effectively and clear more rapidly.<sup>38</sup> The HAWK and HARRIER trials compared brolucizumab with aflibercept and found that brolucizumab was noninferior for the treatment of neovascular macular degeneration. The safety of the drug is now being reevaluated because of serious postmarketing adverse events that have been reported, including inflammation and occlusive vasculitis with severe vision loss.<sup>39</sup>

The development of a port delivery system with ranibizumab is currently under investigation with promising results. The phase 3 Archway study examined the efficacy and safety of a surgically implanted port that can be refilled with ranibizumab in office every 6 months.<sup>40,41</sup> This option would significantly reduce the treatment burden of frequent injections, as many patients require treatment every 4 to 12 weeks with current options. The long-term evaluation of safety and efficacy is ongoing but shows promise in extending treatments up to 6 months.

### ***Current Practice***

---

Practice patterns for patients with wet AMD are focused on a tailored approach based on physician and patient preferences, patient characteristics with extent of disease, and response to treatment.<sup>34</sup> Often if there is minimal or no response to 1 agent, the medication is switched to another. If patients maintain a good response to treatment, generally defined by improvement in vision and resolution of intraretinal and subretinal fluid, the interval for injection administration may be spaced out as tolerated. Generally spacing out of injection visits is done cautiously to ensure there is no recurrence. OCT imaging is critical to this algorithm of treatment to assess treatment response.

### ***Safety and Other Considerations***

---

Although the associated risks of injections are considered low, there are certain local ocular adverse events and systemic events that need to be addressed with the patient before initiating treatment. Local ocular adverse events include elevated intraocular pressure, subconjunctival hemorrhage, vitreous hemorrhage, retinal detachment, and endophthalmitis. Endophthalmitis, an acute inflammatory response inside the eye usually due to infection, is one of the most dreaded complications following any intraocular procedure or surgery and may carry a poor visual prognosis. The risk of endophthalmitis following intravitreal injections for AMD

is very low, with Daien and colleagues<sup>42</sup> reporting a rate of postinjection endophthalmitis of less than 1%.

The amount of systemic absorption of intravitreal anti-VEGF agents for patients with AMD is not fully understood. There is the theoretic risk of increased thrombotic events. Bressler and colleagues<sup>43</sup> reported an increased risk of stroke with higher doses of ranibizumab, although results were confounded by other variables and not considered significant. A large analysis of the systemic safety of ranibizumab in patients with neovascular AMD evaluated events such as myocardial infarction, cerebrovascular accident or transient ischemic attack, thromboembolic events, and major vascular events as per the Antiplatelet Trialists' Collaboration (APTC). The number of adverse events was low, which further supported the safety of the drug.<sup>44</sup> Kitchens and colleagues<sup>45</sup> found a similar safety profile for aflibercept with no statistically significant rate of major vascular events defined by APTC. Patients should be educated on the possible increased risk of thrombotic events, especially if there is a history of previous thrombotic events; however, the exact risk at this time is not fully understood. A promising large analysis of the risk of adverse events after bevacizumab, ranibizumab, and aflibercept evaluated more than 80,000 patients and showed no increased risk of acute myocardial infarction, cerebral vascular disease, or major bleeding after administration of either of the 3 agents.<sup>46</sup>

Nephrotoxicity as a result of intravitreal injections is another potential systemic side effect with inconclusive results. Malignant hypertension, thrombotic microangiopathy, proteinuria, and nephrotic syndrome have been reported in patients with diabetes receiving intravitreal injections for diabetic retinopathy,<sup>47</sup> but there is little evidence to suggest a similar impact on patients who receive injections for AMD. These theoretic risks should be addressed with patients, especially in the presence of any underlying renal disease.

## PREVENTION AND LOW-VISION AIDS

The AREDS<sup>48</sup> established criteria for vitamin supplementation and demonstrated a 25% reduction in progression to advanced AMD. The current supplements consist of zinc, vitamin C, vitamin E, lutein, and zeaxanthin. The original formula included beta-carotene but because of the increased risk of lung cancer in smokers was replaced with lutein and zeaxanthin in the AREDS2 formulation (**Table 2**). Supplementation is recommended for intermediate AMD or those with early AMD in 1 eye and advanced AMD in the fellow eye but was not proven to be beneficial in patients with early AMD in both eyes. Supplementation is also not recommended for AMD prophylaxis or for those with a family history of AMD without the appropriate examination findings to support the qualifying diagnosis. Lifestyle

**Table 2**  
Age-Related Eye Disease Study2 nutrient supplementation and dosage

Vitamin C	400 mg
Vitamin E	400 IU
Copper	2 mg
Lutein	10 mg
Zeaxanthin	2 mg
Zinc	80 mg

modifications are advised for all patients and for those with early AMD in 1 or both eyes. Such modifications include dietary changes to incorporate antioxidant-rich foods and omega-3 and omega-6 fatty acids found in fish, along with weight loss and smoking cessation. Other modifiable risk factors include blood pressure and lipid control. There is conflicting evidence to support the role of UV light exposure and the development of AMD; however, limiting sun exposure is another potential lifestyle modification.<sup>49</sup>

### **Low-Vision Aids**

---

Access to low-vision aids is vital for patients with significant vision loss because of advanced AMD to optimize level of visual function for daily living. Previously, magnification lenses were the primary option available. Although these are an important tool, there are newer modalities available for those with low vision. The OrCam is a recently discovered optical recognition device that is mounted on a frame to assist with recognizing faces, text, and other objects.<sup>50</sup> In addition, smart devices now have many features that benefit those with low vision, such as enlarged font, brightness adjustment, dictation, and voice assist, to name a few.<sup>51</sup> Implantable miniature telescope technology is currently under investigation whereby eligible patients undergo a combined procedure with cataract extraction and telescope implantation.<sup>51</sup> These implants serve as a vision simulator and may be a promising option for the appropriate patient. A referral to a low-vision specialist for patients with vision loss owing to AMD or other eye disease can have a profound impact on improving a patient's ability to perform activities of daily living, as well as a positive impact in other nonocular aspects, such as fall risk and mental health.

### **ON THE HORIZON**

The current gold standard for the treatment of advanced AMD with anti-VEGF therapy requires frequent office visits and carries a significant treatment burden. Newer agents with other molecular targets are currently being investigated with the goal to enhance treatment efficacy and reduce burden of treatment. Faricimab is an angiopoietin-2 and VEGF-A inhibitor where phase 2 trials have shown a sustained response to treatment and may represent the opportunity to extend intervals between injections.<sup>52</sup> Conbercept binds to PLGF, VEGF-A, and VEGF-B and C and is approved for use in China.<sup>53,54</sup> The ongoing PANDA trials are designed to expand the sample size and compare global results.<sup>55</sup>

There are clinical trials currently underway for slowing the progression of geographic atrophy. The DERBY and OAKS trials are phase 3 studies evaluating the efficacy and safety of intravitreal pegcetacoplan, a complement component 3 inhibitor. Phase 2 results were promising and showed a reduced growth rate of geographic atrophy by 29% ( $P = .008$ ) after 12 months.<sup>56</sup>

There is ongoing research in stem cell transplantation and gene replacement therapy focused on treating advanced disease. Clinical trials are underway for stem cell therapy focusing on the transplantation of RPE cells for tissue damaged by CNV or tissue loss owing to geographic atrophy.<sup>57</sup> There have been reports of success with improvement in vision. Early studies for gene therapy were discontinued because of unclear efficacy, but newer methods are on the horizon, and delivery strategies are being explored with promising results.<sup>58</sup>

Recent studies demonstrate a relationship between the use of Metformin for type 2 diabetes and a decreased risk of developing AMD.<sup>59</sup> Anti-inflammatory properties of the drug may play a role, and further investigations are underway.



## SUMMARY

AMD presents a major global health concern with a significant impact on quality of life for the elderly population. Loss of central vision impacts the ability to read, drive, recognize faces, and perform basic living tasks. There is significant variability in the phenotypic expression of the disease whereby early or intermediate AMD may cause minimal symptoms to advanced disease whereby the patient may experience visual distortion, decreased central visual acuity, scotomas, and total loss of central vision. The advent of anti-VEGF therapy has transformed visual outcomes for cases of advanced neovascular AMD. There are limited treatment options for those with advanced AMD secondary to geographic atrophy. Supplementation with AREDS2 vitamins can reduce risk of progression to advanced disease by 25% and is recommended for patients with advanced AMD in 1 eye and early or intermediate disease in the fellow eye. Risk factor modification includes smoking cessation, weight loss, lipid control, and incorporating antioxidant-rich foods into the diet.

## CLINICAL CARE POINTS

- Age-related macular degeneration is primarily a disease of the elderly.
- Most patients have nonexudative or nonneovascular age-related macular degeneration and require ophthalmologic examinations and monitoring.
- Patients should be advised to quit smoking, control blood pressure and cholesterol levels, and maintain a healthy body mass index.
- Providers should be alerted to refer patients who complain of decreased vision, a central blind spot, or distortion in the vision for immediate ophthalmologic evaluation.
- Intravitreal injections are often necessary to preserve vision in those with advanced neovascular age-related macular degeneration.
- There is no treatment for advanced age-related macular degeneration because of geographic atrophy; however, ongoing trials are underway to slow the progression.
- The systemic side effects of intravitreal injections with anti-vascular endothelial growth factor agents may include thromboembolic events; however, these are theoretic risks with limited supporting evidence.

## DISCLOSURE

The authors have nothing to disclose.

## REFERENCES

1. Klein R, Klein BE, Knudtson MD, et al. Fifteen-year cumulative incidence of age-related macular degeneration: the Beaver Dam Eye Study. *Ophthalmology* 2007; 114(2):253–62.
2. Ferris FL III, Fine SL, Hyman L. Age-related macular degeneration and blindness due to neovascular maculopathy. *Arch Ophthalmol* 1984;102:1640–2.
3. Wong WL, Su X, Li X, et al. Global prevalence of age-related macular degeneration and disease burden projection for 2020 and 2040: a systematic review and meta-analysis. *Lancet Glob Heal* 2014;2:e106–16.
4. Casten RJ, Rovner BW. Update on depression and age-related macular degeneration. *Curr Opin Ophthalmol* 2013;24(3):239–43.

5. Age-related macular degeneration: facts & figures. BrightFocus Foundation; 2019. Available at: <https://www.brightfocus.org/sources-macular-degeneration-facts-figures>. Accessed June 6, 2020.
6. Chakravarthy U, Wong TY, Fletcher A, et al. Clinical risk factors for age-related macular degeneration: a systematic review and meta-analysis. *BMC Ophthalmol* 2010;10:31.
7. Davis MD, Gangnon RE, Lee LY, et al. Age-Related Eye Disease Study Group. The Age-Related Eye Disease Study severity scale for age-related macular degeneration: AREDS Report No. 17. *Arch Ophthalmol* 2005;123(11):1484–98 [Erratum in: *Arch Ophthalmol*. 2006;124(2):289-90].
8. Clemons TE, Milton RC, Klein R, et al. Age-related eye disease study research group. risk factors for the incidence of advanced age-related macular degeneration in the age-related eye disease study (AREDS) AREDS report no. 19. *Ophthalmology* 2005;112(4):533–9.
9. Vellilla S, García-Medina JJ, García-Layana A, et al. Smoking and age-related macular degeneration: review and update. *J Ophthalmol* 2013;2013:895147.
10. Seddon JM, George S, Rosner B. Cigarette smoking, fish consumption, omega-3 fatty acid intake, and associations with age-related macular degeneration: the US Twin Study of Age-Related Macular Degeneration. *Arch Ophthalmol* 2006;124(7):995–1001.
11. Joachim N, Mitchell P, Burlutsky G, et al. The incidence and progression of age-related macular degeneration over 15 years: the Blue Mountains Eye Study. *Ophthalmology* 2015;122(12):2482–9.
12. Vingerling JR, Hofman A, Grobbee DE, et al. Age-related macular degeneration and smoking. The Rotterdam Study. *Arch Ophthalmol* 1996;114(10):1193–6.
13. Pennington KL, DeAngelis MM. Epidemiology of age-related macular degeneration (AMD): associations with cardiovascular disease phenotypes and lipid factors. *Eye Vis (Lond)* 2016;3:34.
14. Comparison of Age-related Macular Degeneration Treatments Trials (CATT) Research Group, Maguire MG, Martin DF, Ying GS, et al. Five-year outcomes with anti-vascular endothelial growth factor treatment of neovascular age-related macular degeneration: the comparison of age-related macular degeneration treatments trials. *Ophthalmology* 2016;123(8):1751–61.
15. Varma R, Fraser-Bell S, Tan S, et al. Los Angeles Latino Eye Study Group. Prevalence of age-related macular degeneration in Latinos: the Los Angeles Latino Eye Study. *Ophthalmology* 2004;111(7):1288–97.
16. Parmet S, Lynn C, Glass RM. Age-related macular degeneration. *JAMA* 2006;295(20):2438.
17. Abdelsalam A, Del Priore L, Zarbin MA. Drusen in age-related macular degeneration: pathogenesis, natural course, and laser photocoagulation-induced regression. *Surv Ophthalmol* 1999;44(1):1–29.
18. Klein R, Klein BE, Tomany SC, et al. Ten-year incidence and progression of age-related maculopathy: the Beaver Dam Eye Study. *Ophthalmology* 2002;109(10):1767–79.
19. Ferris FL, Davis MD, Clemons TE, et al. A simplified severity scale for age-related macular degeneration: AREDS Report No. 18. *Arch Ophthalmol* 2005;123(11):1570–4.
20. Fritsche LG, Fariss RN, Stambolian D, et al. Age-related macular degeneration: genetics and biology coming together. *Annu Rev Genomics Hum Genet* 2014;15:151–71.

21. Gehrs KM, Anderson DH, Johnson LV, et al. Age-related macular degeneration—emerging pathogenetic and therapeutic concepts. *Ann Med* 2006;38(7):450–71.
22. Grunwald JE, Pistilli M, Daniel E, et al. Incidence and growth of geographic atrophy during 5 years of comparison of age-related macular degeneration treatments trials. *Ophthalmology* 2017;124(1):97–104.
23. Kiernan DF, Hariprasad SM, Rusu IM, et al. Epidemiology of the association between anticoagulants and intraocular hemorrhage in patients with neovascular age-related macular degeneration. *Retina* 2010;30(10):1573–8.
24. Sparrow JR, Hicks D, Hamel CP. The retinal pigment epithelium in health and disease. *Curr Mol Med* 2010;10(9):802–23.
25. Homayouni M. Vascular endothelial growth factors and their inhibitors in ocular neovascular disorders. *J Ophthalmic Vis Res* 2009;4(2):105–14.
26. Fritsche LG, Igl W, Bailey JN, et al. A large genome-wide association study of age-related macular degeneration highlights contributions of rare and common variants. *Nat Genet* 2016;48(2):134–43.
27. Csaky KG, Schachat AP, Kaiser PK, et al. The use of genetic testing in the management of patients with age-related macular degeneration: American Society of Retina Specialists Genetics Task Force Special Report. *J VitreoRetinal Dis* 2017;1(1):75–8.
28. Gess AJ, Fung AE, Rodriguez JG. Imaging in neovascular age-related macular degeneration. *Semin Ophthalmol* 2011;26(3):225–33.
29. Fujimoto JG, Pitris C, Boppart SA, et al. Optical coherence tomography: an emerging technology for biomedical imaging and optical biopsy. *Neoplasia* 2000;2(1–2):9–25.
30. Ma J, Desai R, Nesper P, et al. Optical coherence tomographic angiography imaging in age-related macular degeneration. *Ophthalmol Eye Dis* 2017;9:1179172116686075.
31. Jager RD, Mieler WF, Miller JW. Age-related macular degeneration. *N Engl J Med* 2008;358(24):2606–17 [Erratum in: *N Engl J Med*. 2008;359(16): 1736].
32. Lau PE, Jenkins KS, Layton CJ. Current evidence for the prevention of endophthalmitis in anti-VEGF intravitreal injections. *J Ophthalmol* 2018;2018:8567912.
33. Fallor MA, Simon SS, Gill MK, et al. Understanding patient perspectives of anti-VEGF treatment experience and effect in age-related macular degeneration. *J Ophthalmol* 2016;1(2):000111.
34. Brown D, Heier J, Boyer D, et al. Current best clinical practices—management of neovascular AMD. *J VitreoRetinal Dis* 2017;1(5):294–7.
35. Submacular Surgery Trials (SST) Research Group. Surgery for subfoveal choroidal neovascularization in age-related macular degeneration. *Ophthalmology* 2004;111(SST report no. 11):1967–80.
36. CATT Research Group. Ranibizumab and bevacizumab for neovascular age-related macular degeneration [published online April 28, 2011]. *N Engl J Med* 2011;364(20):1897–908.
37. Heier JS, Brown DM, Chong V, et al. Intravitreal aflibercept (VEGF trap-eye) in wet age-related macular degeneration. *Ophthalmology* 2012;119(12):2537–48 [published correction appears in *Ophthalmology*. 2013 Jan;120(1):209–10].
38. Gaudreault J, Gunde T, Floyd HS, et al. Preclinical pharmacology and safety of ESBA1008, a single-chain antibody fragment, investigated as potential treatment for age related macular degeneration. *Invest Ophthalmol Vis Sci* 2012;53:3025.
39. Hahn P, Arevalo JF, Blinder KJ, et al. Occlusive retinal vasculitis following intravitreal brodalumab: an ASRS Research and Safety in Therapeutics (ReST) Committee Report. *Retina Times* 2020.

40. Pieramici D. LADDER trial of the Port Delivery System with ranibizumab: initial study results. Presented at the Retina Society 2018 annual meeting; San Francisco, California; September 14, 2018.
41. Pieramici D. Port Delivery System with ranibizumab (PDS): from dose ranging in LADDER phase 2 to ARCHWAY phase 3 study design. Presented at the 2018 American Academy of Ophthalmology Annual Meeting; Chicago, Illinois; October 27, 2018.
42. Daien V, Nguyen V, Essex RW, et al. Incidence and outcomes of infectious and noninfectious endophthalmitis after intravitreal injections for age-related macular degeneration. *Ophthalmology* 2018;125(1):66–74.
43. Bressler NM, Boyer DS, Williams DF, et al. Cerebrovascular accidents in patients treated for choroidal neovascularization with ranibizumab in randomized controlled trials. *Retina* 2012;32(9):1821–8.
44. Zarbin MA, Francom S, Grzeschik S, et al. Systemic safety in ranibizumab-treated patients with neovascular age-related macular degeneration: a patient-level pooled analysis. *Ophthalmol Retina* 2018;2:1087–96.
45. Kitchens JW, Do DV, Boyer DS, et al. Comprehensive review of ocular and systemic safety events with intravitreal aflibercept injection in randomized controlled trials. *Ophthalmology* 2016;123(7):1511–20.
46. Mahoney M, Payne S, Herrin J, et al. Risk of systemic adverse events after intravitreal bevacizumab, ranibizumab, and aflibercept in routine clinical practice. *Ophthalmol* 2020. <https://doi.org/10.1016/j.ophtha.2020.07.062>.
47. Hanna RM, Barsoum M, Arman F, et al. Nephrotoxicity induced by intravitreal vascular endothelial growth factor inhibitors: emerging evidence. *Kidney Int* 2019;96(3):572–80.
48. The Age-Related Eye Disease Study 2 (AREDS2) Research Group. Lutein + zeaxanthin and omega-3 fatty acids for age-related macular degeneration: the Age-Related Eye Disease Study 2 (AREDS2) randomized clinical trial. *JAMA* 2013;309(19):2005–15.
49. Zhou H, Zhang H, Yu A, et al. Association between sunlight exposure and risk of age-related macular degeneration: a meta-analysis. *BMC Ophthalmol* 2018;18:331.
50. Moisseiev E, Mannis MJ. Evaluation of a portable artificial vision device among patients with low vision. *JAMA Ophthalmol* 2016;134(7):748–52.
51. Rush D. Helping patients maximize low-vision technology on smart devices. *Retin Physician* 2020;17:29–31.
52. Csaky KG. Data supporting the sustained efficacy of faricimab, a bispecific antibody neutralizing both angiopoietin-2 and VEGF-A. Presented at: American Academy of Ophthalmology annual meeting; Oct. 11–15, 2019; San Francisco.
53. Zhang M, Yu D, Yang C, et al. The pharmacology study of a new recombinant human VEGF receptor-fc fusion protein on experimental choroidal neovascularization. *Pharm Res* 2009;26(1):204–10.
54. Zhang M, Zhang J, Yan M, et al. Recombinant anti-vascular endothelial growth factor fusion protein efficiently suppresses choroidal neovascularization in monkeys. *Mol Vis* 2008;14:37–49.
55. Kirkner R. Pipeline Report: despite major approvals, the queue gets longer. *Retina Specialist*. Available at: <https://www.retina-specialist.com/article/despite-major-approvals-the-queue-gets-longer>. Accessed August 16, 2020.
56. Dole M. Apellis completes enrollment in two phase 3 studies of the targeted C3 therapy, pegcetacoplan, in patients with geographic atrophy (GA). Available at: <https://>

- [investors.apellis.com/news-releases/news-release-details/apellis-completes-enrollment-two-phase-3-studies-targeted-c3](https://investors.apellis.com/news-releases/news-release-details/apellis-completes-enrollment-two-phase-3-studies-targeted-c3). Accessed August 16, 2020.
57. Zarbin M, Sugino I, Townes-Anderson E. Concise review: update on retinal pigment epithelium transplantation for age-related macular degeneration. *Stem Cells Transl Med* 2019. <https://doi.org/10.1002/sctm.18-0282>.
  58. Ho A, Avery R. Gene therapy trials for wet age-related macular degeneration. *Retina Today*. Available at: <https://retinatoday.com/articles/2019-may-june/gene-therapy-trials-for-wet-age-related-macular-degeneration>. Accessed July 31, 2020.
  59. Brown EE, Ball JD, Chen Z, et al. The common antidiabetic drug metformin reduces odds of developing age-related macular degeneration. *Invest Ophthalmol Vis Sci* 2019;60(5):1470–7.