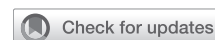

## Robotic aortic valve replacement

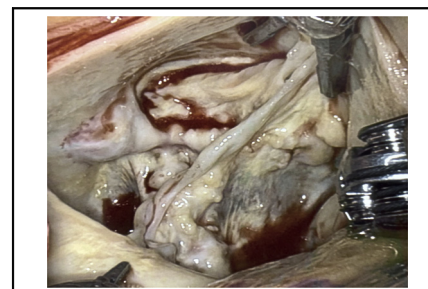


Vinay Badhwar, MD,<sup>a</sup> Lawrence M. Wei, MD,<sup>a</sup> Chris C. Cook, MD,<sup>a</sup> J. W. Awori Hayanga, MD, MPH,<sup>a</sup> Ramesh Daggubati, MD,<sup>b</sup> Partho P. Sengupta, MD,<sup>b</sup> and J. Scott Rankin, MD<sup>a</sup>

▶ Video clip is available online.

The management of aortic valve disease has benefited substantially from the introduction and international application of transcatheter aortic valve replacement (TAVR), particularly for patients deemed at prohibitive, high, or intermediate risk.<sup>1-3</sup> Although the rate of TAVR use recently eclipsed that of surgical aortic valve replacement (SAVR), the volume of SAVR continues to grow incrementally over time, without any increase beyond a 2% risk-adjusted operative mortality.<sup>4</sup> Despite the recent low-risk TAVR trials leading to US regulatory approval,<sup>5,6</sup> controversy remains as to the best longitudinal option for patients at low surgical risk. This is particularly true for populations specifically excluded from published low-risk trials and for whom SAVR may be deemed more appropriate by the multidisciplinary heart team (MDT).<sup>7,8</sup> These management gaps may include the following: aortic insufficiency (AI) without annular calcification, bicuspid aortic stenosis (AS), age <65 years, low surgical risk, need for concomitant procedures or mechanical valve therapy, and higher-risk anatomy for TAVR, such as horizontal valve position and left ventricular outflow tract (LVOT) hypertrophy or calcification. Although SAVR may be favored in many of these circumstances by both the MDT and the patient, traditional SAVR via a full sternotomy is often not.

Minimally invasive SAVR via an upper sternotomy is a readily reproducible technique that has been performed thousands of times worldwide with excellent outcomes comparable to those of SAVR with full sternotomy.<sup>9,10</sup> Minimally invasive right anterior thoracotomy (RAT) also is being performed with increasing frequency, often facilitated by the use of sutureless valves.<sup>11,12</sup> The application of robotic assistance via an 8-cm RAT was first described in 5 patients undergoing SAVR by Folliguet in 2004. The



Robotic exposure of severe bicuspid aortic valve stenosis.

### CENTRAL MESSAGE

This first report of fully robotic aortic valve replacement via a lateral mini-thoracotomy reviews the technique, outcomes, and potential role in valvular disease management.

See Commentaries on pages 1760, 1762, and 1763.

procedure was largely abandoned, however, until recent reports of using the RAT approach to robotically facilitate initial cases of sutureless valve implantation.<sup>13-18</sup> A robotic approach to mitral valve surgery via a 3-cm minimally invasive lateral thoracotomy at the level of the anterior axillary line has been established as a reproducible approach with an excellent safety profile and longitudinal outcomes.<sup>19</sup>

In this report, we introduce the first human experience with an entirely robotic surgical aortic valve replacement (rAVR) using conventional prostheses performed via a minimally invasive lateral thoracotomy working incision. We review the technical aspects, early results, and potential suggestions for rAVR's future role in the management of aortic valve disease.

### SURGICAL TECHNIQUE

#### Development

Based principally on a contemporary, well-established and routinely applied robotic mitral platform, a 2-surgeon team (V.B., L.W.) performed 4 cadaver laboratories over a 24-month period to help refine the instrumentation for aortic valve exposure and SAVR, using the identical lateral approach for robotic-assisted mitral operations.

From the <sup>a</sup>Department of Cardiovascular and Thoracic Surgery and <sup>b</sup>Division of Cardiology, West Virginia University, Morgantown, WV.

Received for publication Aug 31, 2020; revisions received Oct 4, 2020; accepted for publication Oct 19, 2020; available ahead of print Nov 16, 2020.

Address for reprints: Vinay Badhwar, MD, Department of Cardiovascular and Thoracic Surgery, West Virginia University, 1 Medical Center Drive, Morgantown, WV 26506 (E-mail: [vinay.badhwar@wvumedicine.org](mailto:vinay.badhwar@wvumedicine.org)).

J Thorac Cardiovasc Surg 2021;161:1753-9

0022-5223/\$36.00

Copyright © 2020 by The American Association for Thoracic Surgery

<https://doi.org/10.1016/j.jtcvs.2020.10.078>

Modifications to facilitate aortotomy, valvectomy, interrupted annular suture placement, prosthesis securement, and aortotomy closure included a slightly more distal application of the cross-clamp and introduction of the long-tip grasping forceps as a third robotic instrument.

Once the preliminary rAVR technique and suture management was refined in cadavers, staged clinical application was introduced. To establish and facilitate an operating team routine in preparation for the rAVR approach, 10 patients with fully informed consent underwent nonrobotic direct-vision SAVR with video assistance via this lateral approach facilitated by shafted instruments.

### Implementation

Between January 10, 2020, and July 1, 2020, following Institutional Review Board approval and fully informed patient consent, we performed 20 consecutive fully robotic cases. To inform the present report, operative times of individual segments of the procedure were analyzed, inclusive of in-hospital and 30-day clinical and echocardiographic outcomes in all patients and an additional 90-day clinical follow-up in the 17 patients who were beyond this temporal threshold at time of this writing. As all but 1 case was elective, no operations were performed between April and May 2020 due to the Sars-CoV-2 pandemic.

### Inclusion/Exclusion Criteria

All patients age >18 years with severe, symptomatic AS or AI were considered for inclusion. Patients with coronary disease necessitating surgical revascularization, previous cardiac surgery or right thoracotomy, left ventricular ejection fraction <25%, and severe peripheral vascular disease precluding peripheral cannulation for cardiopulmonary bypass (CPB) were excluded. Preoperative MDT evaluation included computed tomography angiography with 3-dimensional reconstruction for all patients.

### Technique

Identical to our robotic mitral protocol, patients were prepared with upper extremity arterial monitoring and intrathecal injection of 0.1 mg of morphine sulfate, followed by induction of anesthesia through double-lumen endotracheal intubation. Femoral cannulation was established via a 2-cm oblique incision over the right common femoral artery and vein. Bicaval venous drainage was established by placement of supplemental percutaneous right internal jugular venous cannulation to preserve consistency with our mitral protocol. A 5 Fr distal perfusion catheter in the superficial femoral artery connected to the ipsilateral arterial cannula was used in all patients.

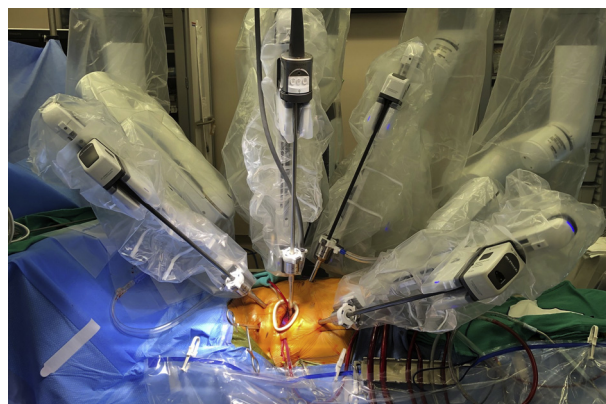
Following initiation of CPB, an aortic root vent was placed through the 3- to 4-cm working incision (cases 1-3 had a 5-cm incision, reduced to 3-4 cm thereafter), and venting was performed by a traditional left ventricular vent

inserted through the right superior pulmonary vein via a separate chest wall stab incision. A transthoracic aortic cross-clamp facilitated 8:1 blood cardioplegic delivery in the aortic root and/or directly via the coronary ostia every 20 minutes, in a protection protocol consistent with all cases in our institution. A 4-port Xi robot (DaVinci; Intuitive Surgical, Sunnyvale, Calif) was used in all cases with the camera port through the working incision in arm 2. Three additional ports via separate stab incisions were used: DeBakey forceps in arm 1, long-tip grasping forceps in arm 3, and scissors/needle driver in arm 4 (Figure 1).

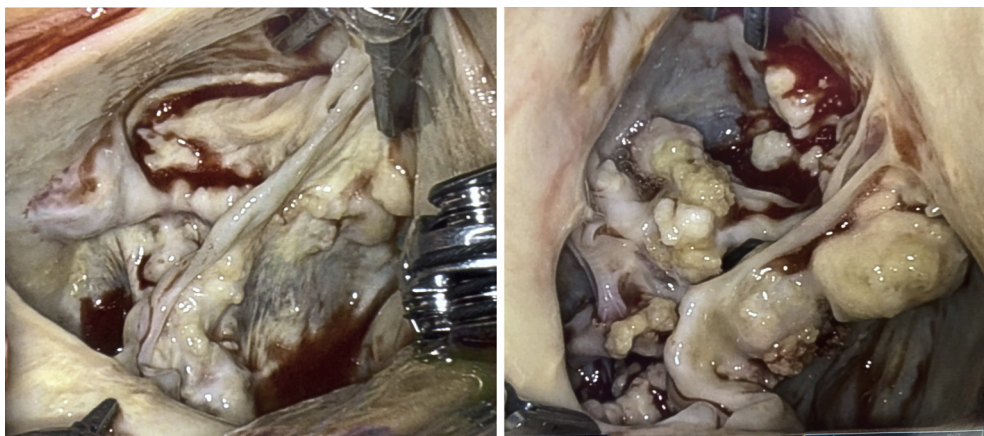
Antegrade cardioplegia via the root or direct coronary ostial perfusion was used in all cases. Retrograde cardioplegia was not used after case 1, to facilitate more efficient suture management and use of arms 3 and 4. The aortotomy commenced at or above the sinotubular junction and extended laterally to the pulmonary artery and posteromedially to the midpoint of the noncoronary sinus to achieve clear valve exposure (Figure 2).

Following valve excision with robotic Metzenbaum scissors in all cases, interrupted 2-0 braided polyester nonpledgetted mattress sutures were robotically placed from the ventricular side commencing at the left noncommissure and proceeding clockwise. We have found that placing sutures through the annulus left-handed from the mid right-coronary leaflet clockwise to the mid noncoronary leaflet annulus facilitates tableside suture management and minimizes potential inadvertent instrument trauma to the aortotomy.

Sizing was then performed coaxially with robotic assistance, using conventional commercially available bioprosthetic or mechanical valve sizers. Following suture placement, the valve was delivered by the tableside assistant within the initial view and then lowered into the annulus robotically to permit navigation of the aortotomy. Suture fasteners facilitated knot tying (Core-Knot; LSI Solutions,



**FIGURE 1.** Robotic aortic valve platform. A 3- to 4-cm lateral working incision in the fourth intercostal space at the level of the anterior axillary line, and a 4-arm setup using the DaVinci Xi (Intuitive Surgical) was used in all cases.



**FIGURE 2.** Robotic valve exposure. Following a curvilinear aortotomy extending to the noncoronary sinus, excellent visualization of the native aortic valve is feasible with the camera port in a lateral working incision: bicuspid (*left*) and tricuspid (*right*).

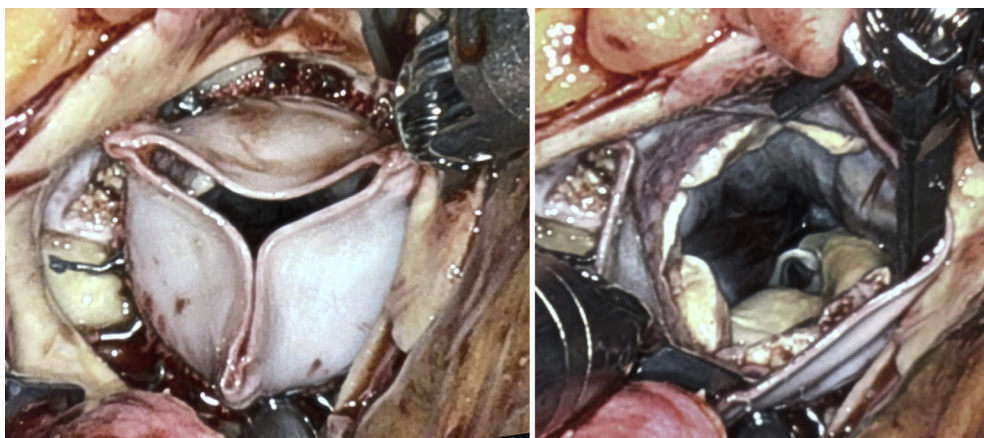
Victor, NY) of both bioprosthetic (Figure 3) and mechanical (Figure 4) prostheses. The aortotomy was closed using 4-0 polypropylene suture in 2 layers. Atrial and ventricular pacing wires were placed robotically, after which warm antegrade reperfusate was injected into the aortic root for reanimation and the cross-clamp was released. Patients were then weaned from CPB under full double-lung ventilation, decannulated, and closed (Video 1).

## EARLY OUTCOMES

### Patient Characteristics

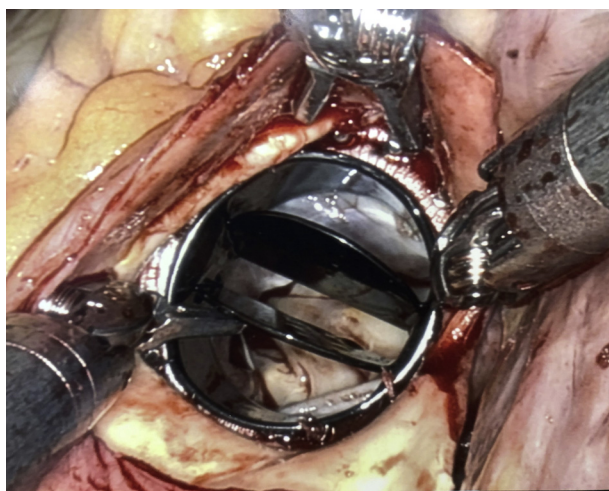
Twenty consecutive patients meeting our inclusion criteria were included. The mean age was  $67.5 \pm 5.4$  years (range, 53-81 years), and mean body mass index was  $29.9 \pm 4.1$  kg/m<sup>2</sup> (range, 20-42 kg/m<sup>2</sup>). The primary pathology was pure AI in 5 patients (25%) and AS in 15 patients (75%), 2 of whom had at least moderate coexistent AI. Two of the patients with AS had low-flow, low-gradient AS, both with an LVEF <30%. One-half of the patients had bicuspid

etiology (10 of 20; 50%). The median New York Heart Association (NYHA) class was 3 (range, 2-4). The median LVEF was 56.5% (range, 25%-65%), with all but 2 patients with an LVEF <65% and 5 patients with an LVEF <50%. The Society of Thoracic Surgeons (STS) mean predicted risk of mortality was  $1.6 \pm 0.7\%$  (range, 0.5%-3.5%), and the composite mean risk of mortality and major morbidity was  $10.8 \pm 3.3\%$  (range, 5%-26%). No patient had more than mild mitral regurgitation. Two patients had paroxysmal atrial fibrillation. Moderate to severe chronic obstructive pulmonary disease without the need for home oxygen was noted in 3 patients, and 5 patients had preoperative moderate to severe pulmonary hypertension. A history of stroke was noted in 3 patients, 3 patients had a hypercoagulable state with venous thromboembolism, 1 patient had steroid-dependent severe rheumatoid arthritis, 1 patient had radiation valvulopathy and aortopathy from previous Hodgkin disease, 1 patient with a body mass index of 20 kg/m<sup>2</sup> had significant frailty with active preoperative aspiration, and 1 patient had been



**FIGURE 3.** Bioprosthetic robotic aortic valve prosthesis. A low profile supra-annular pericardial bioprosthesis following robotic implantation in both the closed (*left*) and open (*right*) positions.





**FIGURE 4.** Mechanical robotic aortic valve prosthesis. A mechanical bi-leaflet prosthesis following robotic implantation.

intubated preoperatively for pulmonary edema due to severe bicuspid AS and an LVEF of 30%, with preoperative balloon valvuloplasty performed in an attempt at stabilization.

### Clinical Outcomes

All patients received a conventional aortic valve prosthesis; no sutureless valves were used. Five patients received a mechanical prosthesis (25%), and 15 received a bioprostheses (75%). The median prosthesis size was 23 mm (range, 19-27 mm), with only 1 patient receiving a 19-mm On-X mechanical prosthesis (CryoLife, Kennesaw, Ga). Concomitant robotic-assisted procedures were performed in 3 patients: 1 epicardial atrial appendage clip, 1 open surgical ablation with endocardial cryoablation (Cox maze III) inclusive of surgical obliteration of the left atrial appendage, and 1 aortic root enlargement with autologous pericardial patch.

There was no operative 30-day mortality, no major morbidity (ie, renal failure, prolonged ventilation, stroke, reoperation for bleeding, or infection), and no paravalvular

leak (PVL) as documented by intraoperative transesophageal echocardiography. Only 1 patient required blood product transfusion, and all but 2 patients were extubated in the operating room, both of whom were extubated within 2.5 hours postoperatively. Only 1 patient developed postoperative conduction difficulties requiring a pacemaker. The median length of stay was 4.5 days (range, 3-15 days). The single patient with a 15-day stay had a preoperative LVEF of 25%; low-flow, low-gradient severe bicuspid AS; a planned balloon pump; and postoperatively planned cardiac resynchronization therapy.

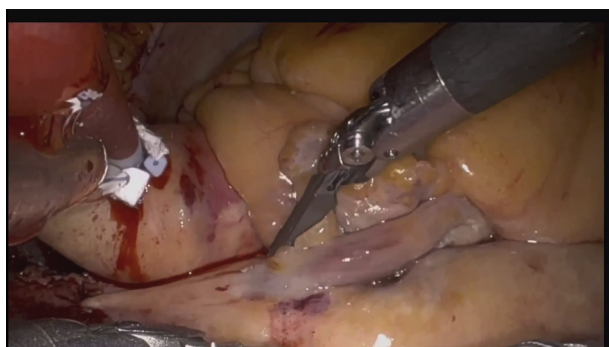
All patients were discharged directly to home except for 1 patient who was released from a skilled nursing facility after 6 days. There were no 30-day readmissions. Nineteen patients were in NYHA class I and 1 patient was in class II at the 30-day follow-up. This patient had known preoperative chronic obstructive pulmonary disease and class IV symptoms before undergoing rAVR. All patients were free of PVL or valvular abnormalities as documented by postoperative 30-day transthoracic echocardiography. All but 1 patient had resumed full activities of daily living, including driving.

Seventeen patients were at or beyond 90 days at the time of this writing, and all reported NYHA class I symptoms with full resumption of normal activity at or substantively enhanced from baseline. Because preoperative baseline quantitative heart failure questionnaire data were not obtained in this preliminary experience, we could not perform a more precise quality of life assessment beyond NYHA class and clinical history.

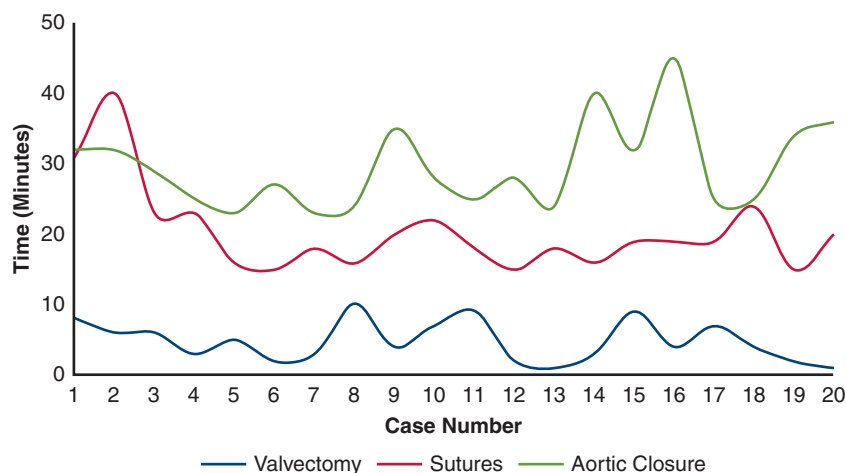
### Operative Technical Observations

Technique proficiency and development were assessed prospectively by analyzing 5 compartmentalized portions of the operative procedure. In an effort focused on learning curve quality improvement, times were recorded in a protocolized manner by the operative team for each of the following robotic operative segments: aortotomy, valvectomy, annular suture placement, suture tying, and aortotomy closure. For the entire cohort, the median time (range) in minutes for each segment was 1 (1-2), 4 (1-10), 19 (15-40), 7.5 (5-21), and 28 (23-45), respectively.

The times for valvectomy, annular suture placement, and aortotomy closure varied with technical experience. After approximately 5 cases, times were relatively consistent for the rest of the patients in this initial cohort (Figure 5). For valvectomy, times for patients with pure AI were consistently only 1 minute. For the 15 patients with AS, the median time was 6 minutes (range 3-10 minutes). All annular debridement was completed with the robotic scissors without the need for tableside rongeur assistance. For annular suture placement, once the technique described above was established by case 5, times were relatively consistent at approximately 18 to 19 minutes. As noted in



**VIDEO 1.** Robotic aortic valve replacement: technique and early outcomes. Video available at: [https://www.jtcvs.org/article/S0022-5223\(20\)32904-4/fulltext](https://www.jtcvs.org/article/S0022-5223(20)32904-4/fulltext).



**FIGURE 5.** Stages and procedural times of robotic aortic valve replacement. To estimate the initial technical learning curve, times to complete steps of robotic aortic valve replacement were recorded, which revealed that baseline was achievable after 5 cases.

Figure 5, after the initial 5-case learning curve, the most time-consuming portion of the operation was aortotomy closure, at approximately 25 to 30 minutes (with 2 cases requiring at least 40 minutes). The patient requiring an aortic root enlargement with an autologous pericardial patch required 40 minutes, and the patient with radiation aortopathy had a calcified and friable root, and closure took 45 minutes. No patient required additional repairs on cross-clamp removal. The mean cross-clamp time for the entire cohort was  $121 \pm 22.1$  minutes (range, 95-216 minutes). If the patients requiring concomitant procedures were censored, the clamp time was  $109 \pm 10.4$  minutes (range, 95-133 minutes) inclusive of the first 5 cases. Similarly, the mean CPB time for the entire cohort was  $175 \pm 33.6$  minutes (range, 134-274 minutes). If the patients requiring concomitant procedures were censored, the CPB time was  $159 \pm 18.6$  minutes (range, 134-217 minutes) inclusive of the first 5 cases, with the last 5 cases all under 150 minutes. All cases were managed with intermittent cold blood antegrade cardioplegia delivered via the coronary ostia with robotic assistance.

## PERSPECTIVE

This introduction of robotic surgical aortic valve replacement using a 4-arm technique facilitated by a lateral minimally invasive thoracotomy working incision may extend the current armamentarium of robotic and minimally invasive surgeons while potentially addressing existing management gaps of low-risk TAVR versus SAVR.

## CURRENT SURGICAL STATUS AND FUTURE DEVELOPMENT

This current technique of rAVR uses a nearly identical platform to that used in thousands of successful robotic mitral valve procedures. The minimally invasive RAT approach was first used to explore 5 cases of rAVR<sup>14</sup> but is now commonly

used to facilitate direct-vision sutureless valve implantation, including a few recent cases performed with robotic assistance.<sup>17,18</sup> The RAT approach provides excellent exposure to the aorta and root. This involves an anteromedial chest incision, often in the second or third intercostal space and midclavicular line, commonly performed by dividing or splitting pectoralis muscle fibers, dividing the right internal thoracic artery, and possibly shingling a rib, with the subsequent need for rib stabilization. Unlike the RAT approach, the current approach to rAVR is performed through a rib-sparing lateral mini-thoracotomy in the fourth intercostal space that spares the pectoralis and latissimus dorsi. This technique uses only conventional commercially available SAVR prostheses. Much like our patients undergoing robotic mitral valve procedures, patients undergoing rAVR are often extubated in the operating room and discharged with minimal or no need for oral narcotic analgesia.<sup>19</sup>

Surgeons are becoming increasingly proficient at robotic mitral valve surgery with over 14% of mitral repairs currently being performed robotically in the United States.<sup>20</sup> As SAVR is a routine operation for most surgeons, for those with robotic experience, it is our anticipation that the current rAVR technique might be readily adopted with a relatively short learning curve as estimated in this report. We have observed that specific portions of robotic mitral valve and aortic valve operations have slightly different orders of complexity (Table 1). For example, the most challenging segment of a robotic mitral case is leaflet valvuloplasty with resection or nonresection techniques, whereas the most challenging portion of a rAVR case is the aortotomy closure. From this initial experience, other than friable aortic tissue in certain cases, we submit that the reason aortotomy closure has been the most challenging is that we had to develop the steps of safe robotic suture technique and exposure as well as the tableside technique and trajectory through the working port.

**TABLE 1. Ranking levels of difficulty in robotic mitral and aortic valve operations**

Robotic mitral valve	Robotic aortic valve
1. Leaflet repair techniques	1. Aortotomy closure
2. Annular suture placement	2. Annular suture placement
3. Atriotomy closure	3. Valvectomy
4. Atriotomy	4. Aortotomy

The current experience was with a 2-surgeon approach, and the importance of a highly experienced tableside assistant cannot be overstated. Team coordination with suture management and aortotomy vigilance are essential to mitigate risk, enhance operative workflow, minimize the learning curve, and enable application of rAVR to patients of increasing complexity and need for concomitant procedures.

### MANAGEMENT GAPS OF TAVR VS SAVR IN LOW-RISK PATIENTS: A POTENTIAL ROLE FOR RAVR

The routine use of TAVR has markedly enhanced the management of aortic valve disease. All-cause mortality and disabling stroke outcomes have shown clear superiority over medical therapy in prohibitive-risk patients and noninferiority in selected randomized high-risk and intermediate-risk patients.<sup>1-3</sup> Its therapeutic availability has increased institutional MDT referrals and global TAVR procedural volumes, yet has permitted continued growth of SAVR, albeit at a far slower pace than for TAVR.<sup>4</sup> The outcomes of 2 recent trials examining patients at low surgical risk of mortality (STS risk <4%), PARTNER 3 (Sapien S3, Edwards, Irvine, Calif) and Evolut Low Risk (CoreValve, Medtronic, Minneapolis, Minn), resulted in US federal approval for low-risk TAVR.<sup>5,6</sup> However, important aspects of these trials merit a brief mention. The PARTNER 3 trial included cardiovascular rehospitalization along with all-cause mortality and stroke in their 1-year composite primary endpoint, and Evolut Low Risk was a Bayesian probability analysis of 2-year all-cause mortality and stroke modeled to noninferiority to SAVR. Both trials met their primary endpoint, yet when examining only all-cause mortality, the data are quite similar.<sup>5,6</sup> Most importantly, the inclusion criteria for both trials were restricted to those of older age, with tricuspid valve morphology, and without subvalvular calcium or anatomic size exclusions deemed not ideal for the TAVR prostheses. This restrictive selection resulted in <7% of patients being age <65 and sponsor selection eligibility screen fail rates of 34% in PARTNER 3 and 15% in Evolut Low Risk.<sup>5,6</sup> Therefore, the current US market approval for low-risk patients is based on evidence largely from rehospitalization and upfront early mortality/morbidity in a highly selected group of patients age

>65 years with tricuspid AS and straightforward TAVR anatomy. Thus, calls for a TAVR-first clinical posture or guideline appear to be premature without real-world longitudinal evidence.<sup>7,8</sup> Existing real-world data, such as that from the Nordic Aortic Valve Intervention trial, show no difference between TAVR and SAVR in an all-comer low-risk population, albeit with earlier-generation devices.<sup>21</sup> Reardon, co-principal investigator in the CoreValve trials (Medtronic), and colleagues<sup>22</sup> have further postulated that when viewing the existing low-risk trial data in the aggregate, the generalizability of existing data to all populations remains limited, given the current lack of evaluable evidence outside the important limited parameters of the trials, and the durability of TAVR valves in younger patients remains unknown. Finally, although bicuspid valve intervention is beginning to be explored with equivocal results,<sup>23</sup> questions remain as to the relative impact of hypoattenuating leaflet thickening and microthrombosis on TAVR durability,<sup>24</sup> especially when the 5-year data on intermediate-risk patients now reveal that PVL, need for re-intervention, and longitudinal outcomes may begin to slightly favor SAVR over TAVR.<sup>25</sup>

Collectively, there exist several clinical situations in which data to inform the management of aortic valve disease is either lacking or equpositional. When facing a low-risk patient who falls out of the aforementioned clinical trial parameters, MDT members must keep longitudinal patient outcomes in mind. High-risk anatomic features for TAVR may include LVOT abnormalities, nonvertical coaxial alignment of the annulus that may impair deployment, and annular features of size and calcium burden that increase the risk of PVL, dislodgement, or disruption. In prohibitive-risk and high-risk populations, these findings require careful navigation for the purposes of procedural safety and patient counseling. In low-risk patients, one must be increasingly thoughtful, given that SAVR affords a well-established safe and durable solution.<sup>4</sup> Thus, existing gaps in the management of aortic valve disease may include the following: AI without annular calcification, bicuspid valve disease, age <65 years, low surgical risk, need for concomitant procedures or mechanical valve therapy, and higher-risk anatomy for TAVR, such as horizontal valve position and LVOT hypertrophy or calcification (Table 2). In the current rAVR experience, all but 1 patient fell into this evidentiary gray zone.

The current experience with rAVR, albeit quite early and needing multicenter validation, may help address many existing management gaps by providing a nonsternotomy minimally invasive option that has the potential to approximate the short-term results of TAVR while preserving the known longitudinal outcomes of SAVR. In the present cohort, all patients had a low STS risk of mortality, the majority had a depressed LVEF, one-half had bicuspid morphology, one-quarter had pure AI, and one-quarter



**TABLE 2. Existing management gaps for transcatheter versus surgical aortic valve replacement in aortic valve disease**

1. Aortic insufficiency without annular calcification
2. Bicuspid valve morphology
3. Low surgical risk
4. Age <65 y
5. Need for concomitant procedures
6. Outflow tract calcification
7. Horizontal annular position
8. Mechanical valve appropriateness
9. Low risk and abnormal ejection fraction

received a mechanical valve. A relative horizontal coaxial axis of the annulus, a risk factor for TAVR, is highly favored for a lateral thoracotomy robotic approach, because the anatomic position of the valve is often directly facing the working incision. In fact, given the early success of rAVR, our health system MDT has now independently positioned rAVR as the first-line therapy for young, low-risk AS patients and those with higher-risk TAVR features, including bicuspid disease.

The patient-level appeal and widespread availability of TAVR has set a consumer expectation of minimally invasive solutions with short hospital stays and rapid recovery. Although all MDT physicians evaluating low-risk patients would hopefully also focus on longitudinal outcome and surgical solutions, can we expect patients to always agree to sternotomy, mini-sternotomy, or RAT approaches to SAVR? Within the obvious clear limitations and caveats of this very early rAVR experience with results comparable to TAVR, it may be reasonable to expect that if robotic surgeons are able to reproduce these early results, rAVR may soon become an alternative option for low-risk patients with aortic valve disease.

### Conflict of Interest Statement

Drs Wei and Rankin serve as consultants for BioStable, Inc. All other authors reported no conflicts of interest.

The *Journal* policy requires editors and reviewers to disclose conflicts of interest and to decline handling or reviewing manuscripts for which they may have a conflict of interest. The editors and reviewers of this article have no conflicts of interest.

We thank Peter Carnegie for his assistance.

### References

- Leon MB, Smith CR, Mack MJ, Miller DC, Moses JW, Svensson LG, et al. Transcatheter aortic-valve implantation for aortic stenosis in patients who cannot undergo surgery. *N Engl J Med*. 2010;363:1597-607.
- Smith CR, Leon MB, Mack MJ, Miller DC, Moses JW, Svensson LG, et al. Transcatheter versus surgical aortic-valve replacement in high-risk patients. *N Engl J Med*. 2011;364:2187-98.
- Reardon MJ, Van Mieghem NM, Popma JJ, Kleiman NS, Søndergaard L, Mumtaz M, et al. Surgical or transcatheter aortic-valve replacement in intermediate-risk patients. *N Engl J Med*. 2017;376:1321-31.
- Bowdish ME, D'Agostino RS, Thourani VH, Desai N, Shahian DM, Fernandez FG, et al. The Society of Thoracic Surgeons adult cardiac surgery database: 2020 update on outcomes and research. *Ann Thorac Surg*. 2020;109:1646-55.
- Mack MJ, Leon MB, Thourani VH, Makkar R, Kodali SK, Russo M, et al. Transcatheter aortic-valve replacement with a balloon-expandable valve in low-risk patients. *N Engl J Med*. 2019;380:1695-705.
- Popma JJ, Deeb GM, Yakubov SJ, Mumtaz M, Gada H, O'Hair D, et al. Transcatheter aortic-valve replacement with a self-expanding valve in low-risk patients. *N Engl J Med*. 2019;380:1706-15.
- Kaul S. Raising the evidentiary bar for guideline recommendations for TAVR: JACC review topic of the week. *J Am Coll Cardiol*. 2020;76:985-91.
- Mack MJ, Adams DH. Regulatory approval and practice guidelines involving cardiovascular valve devices: determining the right evidentiary bar. *J Am Coll Cardiol*. 2020;76:992-5.
- Gilmanov D, Bevilacqua S, Murzi M, Cerillo AG, Gasbarri T, Kallushi E, et al. Minimally invasive and conventional aortic valve replacement: a propensity score analysis. *Ann Thorac Surg*. 2013;96:837-43.
- Nair SK, Sudarshan CD, Thorpe BS, Singh J, Pillay T, Catarino P, et al. Mini-Stern trial: a randomized trial comparing mini-sternotomy to full median sternotomy for aortic valve replacement. *J Thorac Cardiovasc Surg*. 2018;156:2124-32.e31.
- Yousuf Salmasi M, Hamilton H, Rahman I, Chien L, Rival P, Benedetto U, et al. Mini-sternotomy vs right anterior thoracotomy for aortic valve replacement. *J Card Surg*. 2020;35:1570-82.
- Andreas M, Berretta P, Solinas M, Santarpino G, Kappert U, Fiore A, et al. Minimally invasive access type related to outcomes of sutureless and rapid deployment valves. *Eur J Cardiothorac Surg*. 2020;58:1063-71.
- Folliquet TA, Vanhuyse F, Magnano D, Laborde F. Robotic aortic valve replacement: case report. *Heart Surg Forum*. 2004;7:E551-3.
- Folliquet TA, Vanhuyse F, Konstantinos Z, Laborde F. Early experience with robotic aortic valve replacement. *Eur J Cardiothorac Surg*. 2005;28:172-3.
- Suri RM, Burkhardt HM, Schaff HV. Robot-assisted aortic valve replacement using a novel sutureless bovine pericardial prosthesis: proof of concept as an alternative to percutaneous implantation. *Innovations (Phila)*. 2010;5:419-23.
- Balkhy HH, Lewis CTP, Kitahara H. Robot-assisted aortic valve surgery: state of the art and challenges for the future. *Int J Med Robot*. 2018;14:e1913.
- Balkhy HH, Kitahara H. First human totally endoscopic robotic-assisted sutureless aortic valve replacement. *Ann Thorac Surg*. 2020;109:e9-11.
- Nagoaka E, Gelinias J, Vola M, Kiai B. Early clinical experiences of robotic-assisted aortic valve replacement for aortic valve stenosis with sutureless aortic valve. *Innovations (Phila)*. 2020;15:88-92.
- Coyan G, Wei LM, Althouse A, Roberts HG, Schauble D, Murashita T, et al. Robotic mitral valve operations by experienced surgeons are cost-neutral and durable at 1 year. *J Thorac Cardiovasc Surg*. 2018;156:1040-7.
- Gammie JS, Chikwe J, Badhwar V, Thibault DP, Vemulapalli S, Thourani VH, et al. Isolated mitral valve surgery: the Society of Thoracic Surgeons adult cardiac surgery database analysis. *Ann Thorac Surg*. 2018;106:716-27.
- Thyregod HGH, Steinbrüchel DA, Ihlemann N, Nissen H, Kjeldsen BJ, Petursson P, et al. Transcatheter versus surgical aortic valve replacement in patients with severe aortic valve stenosis: 1-year results from the all-comers NOTION randomized clinical trial. *J Am Coll Cardiol*. 2015;65:2184-94.
- Wyler von Ballmoos MC, Reardon MJ. Commentary: what pooling data tells us, or not, about using TAVR in the population at low surgical risk for mortality. *Cardiovasc Revasc Med*. 2020;21:439-40.
- Forrest JK, Kaple RK, Ramlawi B, Gleason TG, Meduri CU, Yakubov SJ, et al. Transcatheter aortic valve replacement in bicuspid versus tricuspid aortic valves from the STS/ACC TVT Registry. *JACC Cardiovasc Interv*. 2020;13:1749-59.
- Blanke P, Leipsic JA, Popma JJ, Yakubov SJ, Deeb GM, Gada H, et al. Bioprosthetic aortic valve leaflet thickening in the Evolut Low Risk sub-study. *J Am Coll Cardiol*. 2020;75:2430-42.
- Makkar RR, Thourani VH, Mack MJ, Kodali SK, Kapadia S, Webb JG, et al. Five-year outcomes of transcatheter or surgical aortic-valve replacement. *N Engl J Med*. 2020;382:799-809.

**Key Words:** robotic cardiac surgery, aortic valve replacement, transcatheter