

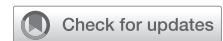leukocytosis with neutrophilia were more likely to be caused by bacterial pneumonia.⁷

Furthermore, the patient responded to antibiotic therapy with substantial clinical improvement after 1 week. Despite the positive SARS-CoV-2 swab, a bacterial pneumonia may be responsible for the clinical course. Bacterial pneumonia is frequently seen in children with COVID-19, as reported by the Wuhan Children's Hospital.⁶ We leave the final interpretation to you, and invite you to enjoy the reading to learn the difficulties they encountered. For us, the learning points missed in this case are (1) the importance of preoperative COVID-19 screening, especially in children, who usually contract the infection from family clusters,^{4,8} and (2) that in the presence of the COVID-19 pandemic, other possible causes of postoperative lung complications should not be neglected.

References

1. Freire Bazerra R, Meiken Franchi S, Khader H, Romero Liguori G, da Fonseca da Silva L, da Silva JP, et al. COVID-19 as a confounding factor in a child submitted to staged surgical palliation of hypoplastic left heart syndrome: one of the first reports of SARS-CoV-2 infection in patients with congenital heart disease. *J Thorac Cardiovasc Surg.* 2020.
2. Lu X, Zhang L, Du H, Zhang J, Li YY, Qu J, et al. Chinese Pediatric Novel Coronavirus Study Team. SARS-CoV-2 infection in children. *N Engl J Med.* 2020;382:1663-5.
3. Dong Y, Mo X, Hu Y, Qi X, Jiang F, Jiang Z, et al. Epidemiology of COVID-19 among children in China. *Pediatrics.* 2020;145:e20200702.
4. She J, Liu L, Liu W. COVID-19 epidemic: disease characteristics in children. *J Med Virol.* 2020;92:747-54.
5. Chang TH, Wu JL, Chang LY. Clinical characteristics and diagnostic challenges of pediatric COVID-19: a systematic review and meta-analysis. *J Formos Med Assoc.* 2020;119:982-9.
6. Xia W, Shao J, Guo Y, Peng X, Li Z, Hu D. Clinical and CT features in pediatric patients with COVID-19 infection: different points from adults. *Pediatr Pulmonol.* 2020;55:1169-74.
7. Cui X, Zhang T, Zheng J, Zhang J, Si P, Xu Y, et al. Children with coronavirus disease 2019: a review of demographic, clinical, laboratory and imaging features in 2597 pediatric patients. *J Med Virol.* 2021;161:e97-101.
8. American Society of Anesthesiologists and Anesthesia Patient Safety Foundation. The ASA and APSF joint statement on perioperative testing for the COVID-19 virus. April 28, 2020. Available at: <file:///C:/Users/Home/AppData/Local/Temp/ASA%20and%20APSF%20Statement%20on%20Perioperative%20Testing%20for%20the%20COVID-19%20Virus%20June%203,2020.pdf>. Accessed June 3, 2020.

See Article page e97.



Commentary: The importance of operative timing in the era of coronavirus disease 2019 (COVID-19)

John P. Costello, MD, and Victor T. Tsang, FRCS

The current worldwide coronavirus disease 2019 (COVID-19) pandemic has required all health care practitioners to consider the care of their patients in an entirely new light. This is especially paramount when determining the timing

From the Cardiothoracic Unit, Great Ormond Street Hospital for Children, London, United Kingdom.

Disclosures: The authors reported no conflicts of interest.

The *Journal* policy requires editors and reviewers to disclose conflicts of interest and to decline handling or reviewing manuscripts for which they may have a conflict of interest. The editors and reviewers of this article have no conflicts of interest.

Received for publication June 15, 2020; revisions received June 15, 2020; accepted for publication June 16, 2020; available ahead of print July 3, 2020.


Address for reprints: Victor T. Tsang, FRCS, Cardiothoracic Unit Great Ormond Street Hospital for Children, Great Ormond St, London WC1N 3JH, United Kingdom (E-mail: Victor.Tsang@gosh.nhs.uk).

J Thorac Cardiovasc Surg 2021;161:e105-6

0022-5223/\$36.00

Copyright © 2020 by The American Association for Thoracic Surgery

<https://doi.org/10.1016/j.jtcvs.2020.06.080>



John P. Costello, MD, and Victor T. Tsang, FRCS

CENTRAL MESSAGE

Providers must carefully consider testing and the true urgency of operative interventions in congenital heart disease patients with recent SARS-CoV-2 exposure, symptoms, or lack thereof.

for any medical procedure, as providers must now, more than ever, appreciate the importance of critically evaluating what procedures are truly urgent and cannot be deferred to an elective basis. Despite the initial focus of the COVID-19 pandemic being directed toward adult patients, pediatric

patients have also experienced a significant burden of this novel disease,^{1,2} and patients with congenital heart disease are certainly not exempt.³

In the current edition of the *Journal*, Bezerra and colleagues⁴ present an early report of a case of severe acute respiratory syndrome coronavirus 2 (SARS-CoV-2) infection complicating the postoperative care and recovery of a young pediatric patient following staged surgical palliation of single-ventricle congenital heart disease. We read this article with great interest both for its novelty and the timely lessons that can be learned from this patient's management. The authors' patient underwent an elective total cavopulmonary connection (TCPC) operation with DeVega tricuspid valve repair in March 2020 for continued management of hypoplastic left heart syndrome. Surgery was completed with intermittent atrioventricular dissociation, but in the following days, the patient developed cough, desaturation, abdominal pain, progressive pulmonary consolidations, and respiratory distress necessitating an escalation in supplemental oxygen therapy. SARS-CoV-2 infection was ultimately confirmed on polymerase chain reaction nasal swab testing on postoperative day 13. With supportive care, the patient slowly recovered and did not require invasive positive-pressure ventilation. In retrospect, the patient was exposed to both of his parents, who experienced "flu-like" symptoms 6 days before this TCPC operation.

Although certainly in need of completion TCPC, the timing of this operation certainly was elective in the present patient's case. Even in the absence of any symptoms, the significance of the potential damage of active SARS-CoV-2 infection and the cytokine interaction that it may produce cannot be underestimated,⁵ especially in patients undergoing surgery.⁶ With the emergence of SARS-CoV-2 infection causing significant morbidity from pediatric multisystem inflammatory syndrome,⁷ including profound impacts on

the heart, lungs, and other end organs in some patients,⁸ the danger of any underestimation of even an apparent asymptomatic SARS-CoV-2 infection, especially in a patient with congenital heart disease, could be very detrimental.

Although we acknowledge that the availability of testing and its implementation are not uniform around the world, we advocate that, until COVID-19 in children with congenital heart disease is better understood, preoperative testing for SARS-CoV-2 infection in all patients for congenital heart disease for time-sensitive cardiac interventions or surgeries should be mandatory. Elective cardiac procedures can be postponed to a later time.

References

1. Dong Y, Mo X, Hu Y, Qi X, Jiang F, Jiang Z, et al. Epidemiology of COVID-19 among children in China. *Pediatrics*. 2020;145:e20200702.
2. Cruz AT, Zeichner SL. COVID-19 in children: initial characterization of the pediatric disease. *Pediatrics*. 2020;145:e20200834.
3. Sanna G, Serrau G, Bassareo PP, Neroni P, Fanos V, Marcialis MA. Children's heart and COVID-19: up-to-date evidence in the form of a systematic review. *Eur J Pediatr*. 2020;30:1-9.
4. Bezerra RF, Franchi SM, Khader H, Castro RM, Liguori GR, da Silva LF, et al. COVID-19 as a confounding factor in a child submitted to staged surgical palliation of hypoplastic left heart syndrome: one of the first reports of SARS-CoV-2 infection in patients with congenital heart disease. *J Thorac Cardiovasc Surg*. 2021;161:e97-101.
5. Mehta P, McAuley DF, Brown M, Sanchez E, Tattersall RS, Manson JJ, et al. COVID-19: consider cytokine storm syndromes and immunosuppression. *Lancet*. 2020;395:1033-4.
6. COVIDSurg Collaborative. Mortality and pulmonary complications in patients undergoing surgery with perioperative SARS-CoV-2 infection: an international cohort study [published correction appears in *Lancet*. June 9, 2020, Epub ahead of print]. *Lancet*. 2020;396:27-38.
7. Royal College of Paediatrics and Child Health Guidance: Paediatric multisystem inflammatory syndrome temporally associated with COVID-19. Available at: <https://www.rcpch.ac.uk/sites/default/files/2020-05/COVID-19-Paediatric-multi-system-%20inflammatory%20syndrome-20200501.pdf>. Accessed June 12, 2020.
8. Verdoni L, Mazza A, Gervasoni A, Martelli L, Ruggeri M, Ciuffreda M, et al. An outbreak of severe Kawasaki-like disease at the Italian epicentre of the SARS-CoV-2 epidemic: an observational cohort study. *Lancet*. 2020;395:1771-8.