

OCT Risk Factors for 3-Year Development of Macular Complications in Eyes With “Resolved” Chronic Central Serous Chorioretinopathy



ENRICO BORRELLI, MARCO BATTISTA, RICCARDO SACCONI, FRANCESCO GELORMINI, LEA QUERQUES, DOMENICO GROSSO, GIOVANNA VELLA, FRANCESCO BANDELLO, AND GIUSEPPE QUERQUES

- **PURPOSE:** To assess the relationship between demographics, clinical characteristics, and structural optical coherence tomography (OCT) findings and the development of sight-threatening macular complications (choroidal neovascularization [CNV], large areas of retinal pigment epithelium [RPE] atrophy, and cystoid macular degeneration [CMD]) in a cohort of eyes with “resolved” chronic central serous chorioretinopathy (CSC) at study baseline.
- **DESIGN:** Retrospective cohort study.
- **METHODS:** In this study, a total of 71 eyes with “resolved” (absence of subretinal fluid) chronic CSC at baseline and 36 months of regular follow-up examinations were retrospectively enrolled. Structural OCT scans were reviewed. Baseline OCT qualitative features reflecting distress of the neuroretina, RPE, or choroid were assessed and included ellipsoid zone discontinuity, outer nuclear layer (ONL) thinning; presence of hyper-reflective intraretinal foci; dome-shaped pigment epithelium detachment (PED); hyper-reflective flat, irregular PED; hyporeflexive flat, irregular PED; and inner choroidal attenuation. OCT images obtained at follow-up visits were also reviewed for development of macular complications (CNV, large areas of RPE atrophy [at least 250 μm in diameter], and CMD). Main outcome measurements included incidence of macular complications and hazard ratio (HR) for demographics, clinical characteristics, and OCT risk factors.
- **RESULTS:** At month 36, 20 eyes (28.2%) developed macular complications. Nine eyes (12.7%) displayed CNV, 9 eyes (12.7%) had large areas of RPE atrophy, and 2 eyes (2.8%) developed cystoid macular degeneration. The following factors were associated with an increased risk of development of CNV: intraretinal hyper-reflective foci had an HR of 11.58 (95% confidence interval [CI]: 1.10-37.24; $P = .040$); inner choroidal attenuation had an HR of 9.66 (95% CI:

1.07-22.34; $P = .043$); and the presence of macular complications in the fellow eye had an HR of 20.17 (95% CI: 1.34-39.41; $P = .030$). Factors associated with the development of RPE atrophy were also identified: ONL thinning had an HR of 13.47 (95% CI: 1.10-39.86; $P = .042$); dome-shaped PED had an HR of 21.40 (95% CI: 1.50-41.10; $P = .031$); and inner choroidal attenuation had an HR of 13.20 (95% CI: 1.07-39.32; $P = .044$).

- **CONCLUSIONS:** OCT risk factors were identified for the development of macular complications in eyes with chronic CSC. Findings may help in the identification of high-risk patients. (Am J Ophthalmol 2021;223: 129–139. © 2020 Elsevier Inc. All rights reserved.)

CENTRAL SEROUS CHORIORETINOPATHY (CSC) IS A chorioretinal disease characterized by idiopathic accumulation of subretinal pigment epithelium (RPE) and subretinal fluid.^{1,2} Although CSC is a complex disease with multiple causes, there is strong evidence that this disease may be ultimately characterized by a dysfunction of the RPE and choroid complex.^{2,3} This disorder usually affects the working-age population, as initial manifestations occur between 20 and 50 years of age.^{2,4}

There is currently no clear consensus regarding the classification of CSC.^{2,5} As an example, presently there is no accepted agreement about the exact time scale to differentiate acute from chronic forms.^{2,5} In addition to the issue of classification, most clinicians and clinical trials consider the complete resolution of subretinal fluid as the primary aim of treatment in cases of CSC.⁶ Cases without subretinal fluid represent a subset of eyes that characterize the “resolved” (“healed” or “inactive”) stage of the disease.^{5,6} In detail, the term chronic “resolved” CSC is usually used for defining patients with a history of subretinal fluid accumulation attributed to 1 or more sites of leakage at the level of the RPE and lasting more than 6 months without evidence of subretinal fluid at the time of definition.

Even though chronic CSC has a relatively benign course, potential sight-threatening macular complications include choroidal neovascularization (CNV),⁷ cystoid macular degeneration (CMD),⁸ and large regions of RPE atrophy.^{9,10} Development of 1 of these complications is indeed significantly associated with worse visual prognosis,

Accepted for publication Oct 12, 2020.

From the Ophthalmology Department (E.B., M.B., R.S., F.G., L.Q., D.G., G.V., F.B., G.Q.), San Raffaele University Hospital, Milan, Italy; and the Ophthalmology (G.V.), Department of Surgical, Medical, Molecular Pathology, and Critical Area, University of Pisa, Pisa, Italy.

Inquiries to Giuseppe Querques, Department of Ophthalmology, University Vita-Salute San Raffaele, Via Olgettina 60, Milan, Italy; e-mails: giuseppe.querques@unir.it; giuseppe.querques@unir.it

and they are commonly observed in CSC patients.¹¹ Previous studies have demonstrated that anti-vascular endothelial growth factor (VEGF) treatment, eventually supplemented by one-half dose or one-half fluence photodynamic therapy (PDT) is the current standard of treatment in newly diagnosed CSC-associated exudative CNV.^{12–15} Early diagnosis and prompt intervention in eyes with CSC and active CNV has been demonstrated to ameliorate visual outcomes.¹⁶ Therefore, it is important to detect this complication at the earliest possible stage. Conversely, there is no effective treatment for CMD and macular RPE atrophy. However, it is hoped that effective treatments may be available in the near future. More importantly, identification of risk factors for the development of such complications may broaden our knowledge regarding their pathogenesis.

Structural optical coherence tomography (OCT) is a critical diagnostic tool for the assessment of patients with CSC because it provides anatomic information regarding the retinal and choroidal layers.¹⁷ Several previous reports have identified OCT findings associated with CSC. The choroid was demonstrated to be focally or diffusely thickened with pathologically dilated medium and larger choroidal vessels.^{18,19} Furthermore, the anterior displacement of these vessels was topographically associated with attenuation of the overlying inner choroid.^{20,21} RPE detachments (PEDs) are frequently observed in eyes with CSC and may appear either as dome-shaped or flat lesions.²² Structural damage of the ellipsoid zone (EZ) and thinning of the outer nuclear layer (ONL) may also be found in eyes with CSC.^{23–25} Finally, structural OCT scans can also be important in identifying intraretinal hyper-reflective foci in the neuroretina.^{26–28}

In this longitudinal study conducted over 3 years, the relationships among demographics, clinical characteristics, structural OCT findings, and development of macular complications (CNV, large areas of RPE atrophy, and CMD) were examined in a cohort of eyes with “resolved” chronic CSC at study baseline.

METHODS

THIS RETROSPECTIVE COHORT STUDY WAS APPROVED BY the San Raffaele Ethics Committee and adhered to the 1964 tenets of the Declaration of Helsinki and its later amendments. Informed consent was obtained from all participants included in the study.

• **SUBJECTS:** Subjects 18 years of age and older with “resolved” (absence of subretinal fluid) chronic CSC in at least 1 eye were identified from the medical records of a medical retina practice (Medical Retina and Imaging Unit) at the San Raffaele Scientific institute. In detail, subjects were included in the initial study cohort if they did not

have neurosensory detachment (ie, absence of subretinal fluid) in at least 1 follow-up visit, which was considered the inclusion or baseline visit in this study, and if there was documentation of previous subretinal fluid accumulation attributed to 1 or more sites of leakage at the level of the RPE and lasting more than 6 months (ie, “resolved” CSC), as previously described.¹¹ Finally, exclusion criteria at baseline visit included: i) prior treatment with PDT in the study eye fewer than 30 days before baseline; ii) history of previous ocular surgeries including anti-VEGF injections; and iii) history or evidence of other retinal and optic nerve disorders. The population fulfilling inclusion and exclusion criteria was the starting cohort for this analysis (329 of 457 chronic CSC patients in the database) (Figure 1).

To be included, patients were also required to have a minimum of 3 yearly retinal visits with OCT scans covering a study period of 36 months after the baseline visit. Of note, all patients at the authors’ clinic were instructed to attend visits urgently in the presence of changes in visual symptoms or visual loss. After this further evaluation, 108 subjects were included in the analysis (Figure 1).

Structural OCT imaging was performed using the HRA+OCT device (Spectralis; Heidelberg Engineering, Heidelberg, Germany). The OCT imaging session included 6 radial, linear spectral domain-OCT scans centered on the fovea, each composed by 25 averaged OCT B-scans (768 A-scans per line) at 30-degrees. A minimum signal strength of 25 was required for the OCT images to be included, as recommended by the manufacturer.²⁹ In addition, at each visit, enrolled patients underwent a complete ophthalmologic evaluation, including assessment of best-corrected visual acuity (BCVA), dilated fundus examination, blue fundus autofluorescence examination, and fluorescein or indocyanine dye angiography in cases with suspected CNV (ie, all cases with irregular, flat PEDs with heterogeneous internal reflectivity). The Spectralis HRA+OCT device (Heidelberg Engineering) was used to perform dye angiography. In selected cases OCT angiography (Plex Elite; Zeiss Meditec, Dublin, California, USA) also was performed in eyes with suspected CNV.

• **OCT GRADING:** Structural OCT images were first reviewed for eligibility (108 patients) by 2 independent and experienced readers (E.B. and M.B.). Eligible eyes (n = 71) (Figure 1) were independently assessed for qualitative features by the same readers who were masked as to the final eyes’ outcomes. Finally, follow-up visits were graded for development of macular complications (CNV, CMD, and RPE atrophy). Based on previous studies,³⁰ a lesion was graded as present if the reader was more than 90% confident that the lesion was recognizable in at least 1 B-scan. Graders later met to compare levels of agreement, and disagreements were resolved by further discussion and open adjudication to yield a single assessment for each case. In those cases in which the 2 graders did not agree on a single consensus result, the final decision was made by the

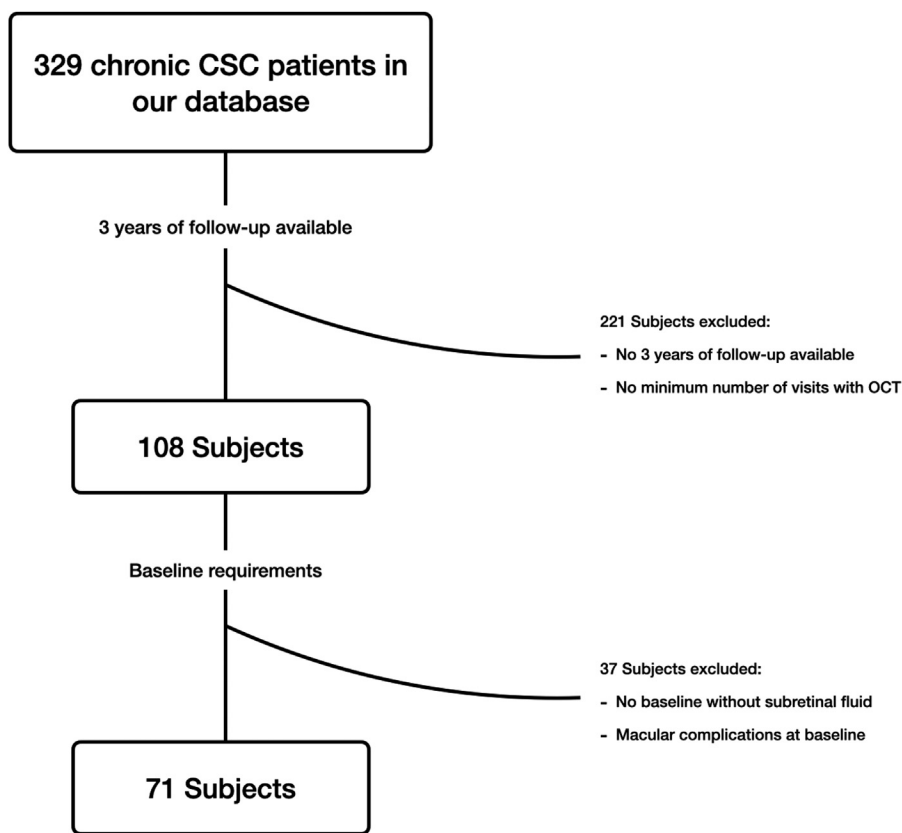


FIGURE 1. Flowchart diagram describes the selection process of eligible. Patients for this analysis. Among the initial cohort of 329 subjects with chronic CSC, only 108 subjects had complete data available for 3 years of follow-up. Among them, 37 subjects either did not have evidence of subretinal fluid resolution or their macular complications were graded at baseline. Hence, they were excluded from the final study cohort. Seventy-one patient were ultimately analyzed. CSC = central serous chorioretinopathy; OCT = optical coherence tomography.

director of the San Raffaele Medical Retina and Imaging Unit (G.Q.).

As explained earlier, OCT images at baseline were graded for eligibility according to the following protocol, and eyes with macular complications at baseline were excluded from the analysis:

- Presence of RPE atrophy was graded as present on the basis of the classification of atrophy meeting³¹ in cases with evidence of choroidal hypertransmission (at least 250 μm in diameter) associated with an RPE defect and thinning of the outer retina. The latter OCT classification was used to define areas of geographic atrophy in age-related macular degeneration. However, a recent study has demonstrated that similar large areas of RPE atrophy may be present in eyes with pachychoroid disease, including CSC.⁹
- Presence of CNV was diagnosed mainly by using multimodal imaging data.^{4,7,32,33} The 2 graders reviewed OCT images and, when available, dye-enhanced angiography and OCT angiography images to further exclude cases with CNV at baseline.

- Macular cystoid degeneration was graded as present in cases with cystoid spaces without evidence of associated CNV.⁸

Finally, cases with evidence of any other pathologic disorders involving the macula, such as high myopia, vitreoretinal affection, or retinal vascular disease, were excluded. After these criteria were applied, 71 subjects were eligible for further analysis (Figure 1).

In the final study cohort, the following OCT images obtained at baseline (Figure 2) were graded for qualitative features previously proposed that suggested neuroretina, RPE, or choroidal distress¹⁷:

- Structural alterations of the outer retina: the EZ and ONL bands were assessed for their integrity. The EZ was graded as discontinuous or intact.¹¹ The ONL was graded as thinned or unchanged.²³
- Hyperreflective intraretinal foci: OCT images were graded for the presence of discrete, well-circumscribed hyper-reflective lesions within the neuroretina.^{30,34,35} These lesions were required to

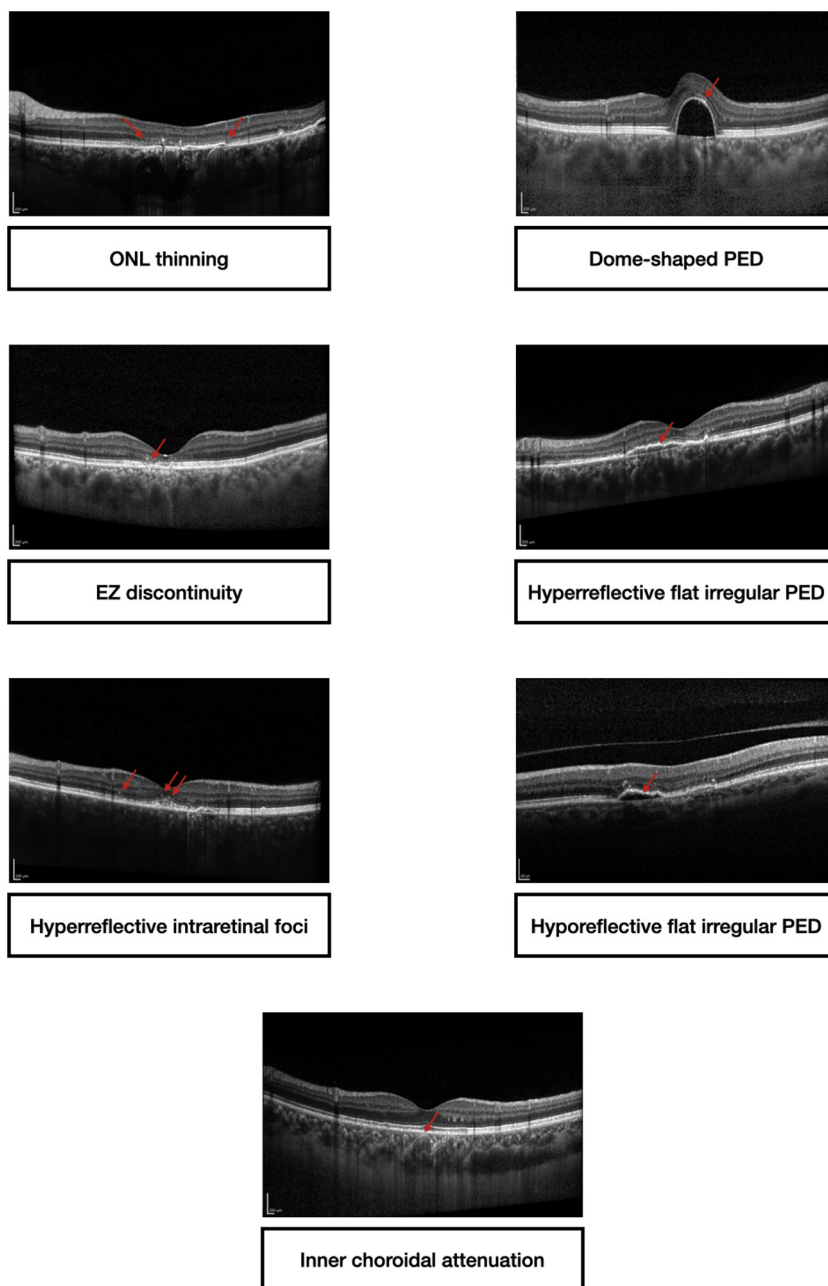


FIGURE 2. Clinical images show OCT features assessed at baseline. OCT images at baseline were graded for qualitative features previously proposed as signs of neuroretina, RPE, or choroidal distress. Red arrows highlight the OCT signs. OCT = optical coherence tomography; RPE = retinal pigment epithelium.

have a reflectivity equivalent or superior to that of the RPE layer.^{30,34,35}

- PED in the macula: OCT images were also reviewed for the presence of PEDs. A dome-shaped PED was defined as a sharply demarcated and protruding RPE.³⁶ Flat, irregular PEDs have an irregular RPE profile that is separated from Bruch's membrane.³⁷ Flat, irregular PEDs were also investigated for the presence of hyper-reflective material between RPE and Bruch's membrane; that analysis yielded 2 types of flat, irreg-

ular PEDs: hyper-reflective and hyporefective, as described in detail previously.³⁸

- Choroidal features: presence of inner choroidal attenuation was graded on the basis of previous OCT reports.¹⁷

- **STUDY OUTCOMES AND STATISTICAL ANALYSIS:** The primary outcome measurement was the development of macular complication, defined as the appearance of CNV

or CMD or large RPE atrophy at any of the follow-up visits. Assuming that eyes with CMD were frequently characterized by associated RPE atrophy, those cases were categorized as affected by CMD (and not RPE atrophy) if both complications were present. A multivariate Cox regression model was fitted to ascertain whether the baseline structural OCT characteristics in these eyes and other clinical or demographic characteristics (ie, age, sex, fellow eye status, previous PDT treatment) were risk factors for development of macular complications. Hazard ratios (HRs) and 95% confidence intervals (CIs) were computed. Patients with no macular complications detected throughout their follow-up visits were censored at the last assessment (36th month visit). The relationship between final visual acuity (considered a dependent variable) and development of macular complications was investigated using a linear regression analysis.

The unweighted κ statistic test³⁹ was performed to evaluate the agreement between graders in the assessment of OCT qualitative features at baseline and the study outcome of no evolution versus development of macular complications.

Statistical calculations were performed using SPSS version 20.0 software (SPSS, Chicago, Illinois, USA).

RESULTS

FROM THE COHORT OF 329 PARTICIPANTS INITIALLY included in the study, 71 were finally included in the analysis (Figure 1). The Table summarizes the demographics and clinical characteristics of this study cohort.

Among the cohort of 71 participants with “resolved” chronic CSC at baseline, 20 eyes (28.2%) developed macular complications within 36 months: 9 eyes (12.7%) developed CNV; 9 eyes (12.7%) had large RPE atrophy within 36 months; and 2 eyes (2.8%) developed CMD within the follow-up period (Table).

Overall, the BCVA was 0.14 ± 0.22 logMAR (Snellen VA of ~20/30) at baseline and 0.14 ± 0.20 logMAR (Snellen VA of ~20/30) at the last follow-up visit ($P = 1.0$ with paired sample t -test). The final BCVA was 0.10 ± 0.19 logMAR (Snellen VA of ~20/25) and 0.17 ± 0.25 logMAR (Snellen VA of ~20/30) in eyes without and with macular complications, respectively, at the last follow-up visit. The final BCVA was significantly associated with development of CNV ($R^2 = -.221$; $P = .045$) and large RPE atrophy ($R^2 = -.293$; $P = .014$).

• **BASELINE RISK FACTORS FOR DEVELOPMENT OF MACULAR COMPLICATIONS:** At the baseline visit, the ONL band was thinned in 28 eyes (39.4%), whereas the EZ band was discontinuous in 39 eyes (54.9%). A total of 26 eyes (36.6%) showed hyper-reflective intraretinal foci within the examined macular region. Dome-shaped PEDs

TABLE. Characteristics of Patients Included in the Analysis

Number of eyes enrolled (patients)	71 (71)
Mean \pm SD age, y	50.5 \pm 10.2
Sex	
M	45 (90%)
F	5 (10%)
BCVA (logMAR), mean (SD)	0.14 (0.22)
Previous Treatments	
PDT	22 (31.0%)
Laser	0 (0%)
Anti-VEGF	0 (0%)
Eplerenone	11 (15.5%)
Fellow eye status	
Chronic CSC	38 (53.5%)
Choroidal neovascularization	2 (2.8%)
RPE atrophy	4 (5.6%)
Cystoid macular degeneration	4 (5.6%)
Baseline characteristics, n (%)	
ONL thinning	28 (39.4%)
EZ discontinuity	39 (54.9%)
Hyperreflective intraretinal foci	26 (36.6%)
Dome-shaped PED	8 (12.3%)
Hyperreflective flat irregular PED	25 (35.2%)
Hyporefective flat irregular PED	20 (28.2%)
Inner choroidal attenuation	43 (60.6%)
Study outcomes, n (%)	
Macular complications (all types)	20 (28.2%)
Choroidal neovascularization	9 (12.7%)
RPE atrophy	9 (12.7%)
Cystoid macular degeneration	2 (2.8%)

BCVA = best corrected visual acuity (logMAR [logarithm of the minimum angle of resolution]); CSC = central serous chorioretinopathy; EZ = ellipsoid zone; n = number of eyes; ONL = outer nuclear layer; PDT = photodynamic therapy; PED = pigment epithelium detachment; RPE = retinal pigment epithelium; SD = standard deviation; VEGF = vascular endothelial growth factors.

were found in 8 eyes (11.3%); flat irregular PEDs with hyper-reflective material were evident in 25 eyes (35.2%), and 20 eyes (28.2%) demonstrated flat irregular PEDs with hyporefective material. Finally, an inner choroidal attenuation was graded as present in 43 eyes (60.6%). Figure 3 shows relative frequencies of each baseline OCT finding in the study cohort.

Figure 4 summarizes the results of the multivariate Cox regression analysis performed using the baseline OCT features, as well as using the demographic and clinical characteristics at baseline to determine the risk of macular complications’ development within 36 months. The following factors were associated with an increased risk of development of CNV: intraretinal hyper-reflective foci had an HR of 11.58 (95% CI: 1.10-37.24; $P = .040$); inner choroidal attenuation had an HR of 9.66 (95% CI: 1.07-22.34; $P = .043$); and the presence of macular complications

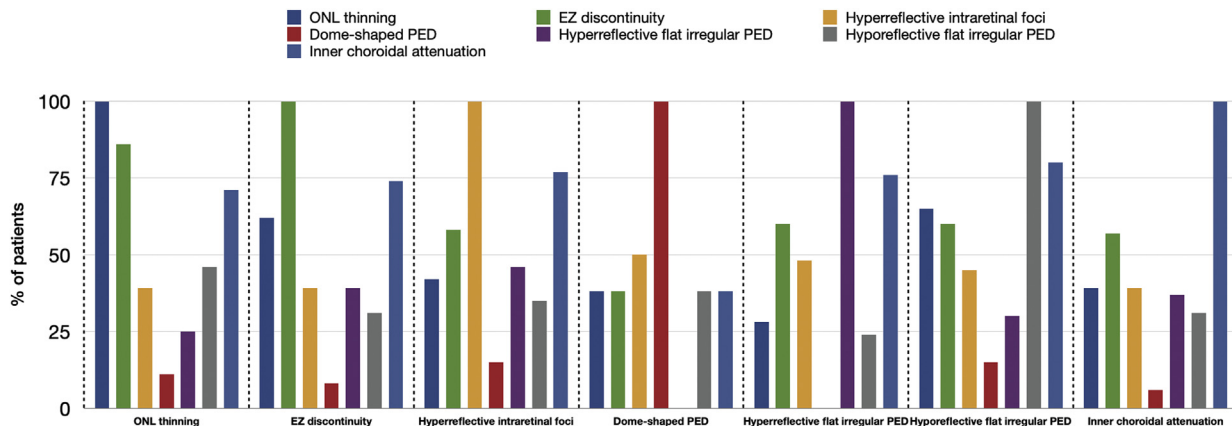


FIGURE 3. Grouped column chart shows the relative frequencies of OCT findings in the study cohort. The chart shows the relative frequencies of patients graded with a specific OCT finding. The relative frequencies are given as a percentage of patients with a specific characteristic in a distinct group. On the x-axis, columns are grouped on the basis of the presence of each OCT finding. OCT = optical coherence tomography.

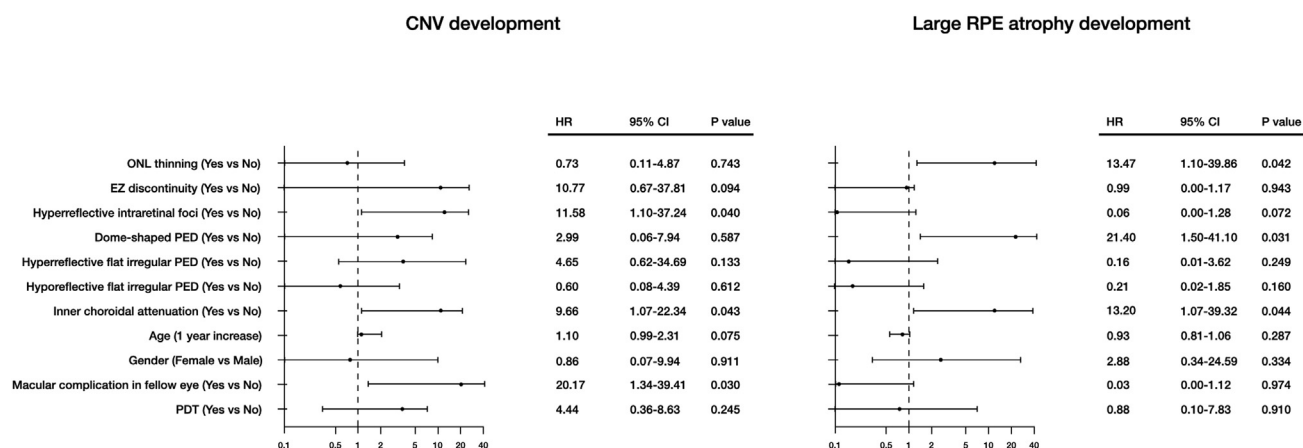


FIGURE 4. Graphs show the risk of development of CNV (left) or large areas of RPE atrophy (right). Graphs show the HR and 95% CI for the demographics (ie, age and sex), clinical characteristics (ie, previous treatment with PDT and fellow eye status), and baseline presence of OCT features. CI = confidence interval; CNV = choroidal neovascularization; EZ = ellipsoid zone; HR = hazard ratio; ONL = outer nuclear layer; PDT = photodynamic therapy; PED = pigment epithelium detachment; RPE = retinal pigment epithelium.

in the fellow eye had an HR of 20.17 (95% CI: 1.34-39.41; $P = .030$) (Figure 5). Factors associated with the development of large RPE atrophy were also identified: ONL thinning had an HR of 13.47 (95% CI: 1.10-39.86; $P = .042$); dome-shaped PED had an HR of 21.40 (95% CI: 1.50-41.10; $P = .031$); and inner choroidal attenuation had an HR of 13.20 (95% CI: 1.07-39.32; $P = .044$) (Figure 6). Other evaluated baseline factors were not significantly associated with development of CNV or large RPE atrophy at 3 years. Importantly, we were not able to identify risk factors associated with an increased risk of CMD developing within 3 years.

• **REPEATABILITY:** The unweighted k values for inter-grader repeatability were 0.91 (103 of 108) for eligibility criteria; 0.94 (69 of 71) for ONL thinning; 0.86 (66 of 71) for EZ discontinuity; 0.87 (67 of 71) for hyper-reflective intraretinal foci; 1.0 (71 of 71) for dome-shaped PED; 0.87 (67 of 71) for hyper-reflective flat, irregular PED; 0.93 (69 of 71) for hyporefective flat irregular PED; 0.86 (66 of 71) for inner choroidal attenuation; and 1.0 (71 of 71) for development of macular complications. Agreement was reached for all discrepancies after adjudication between graders.

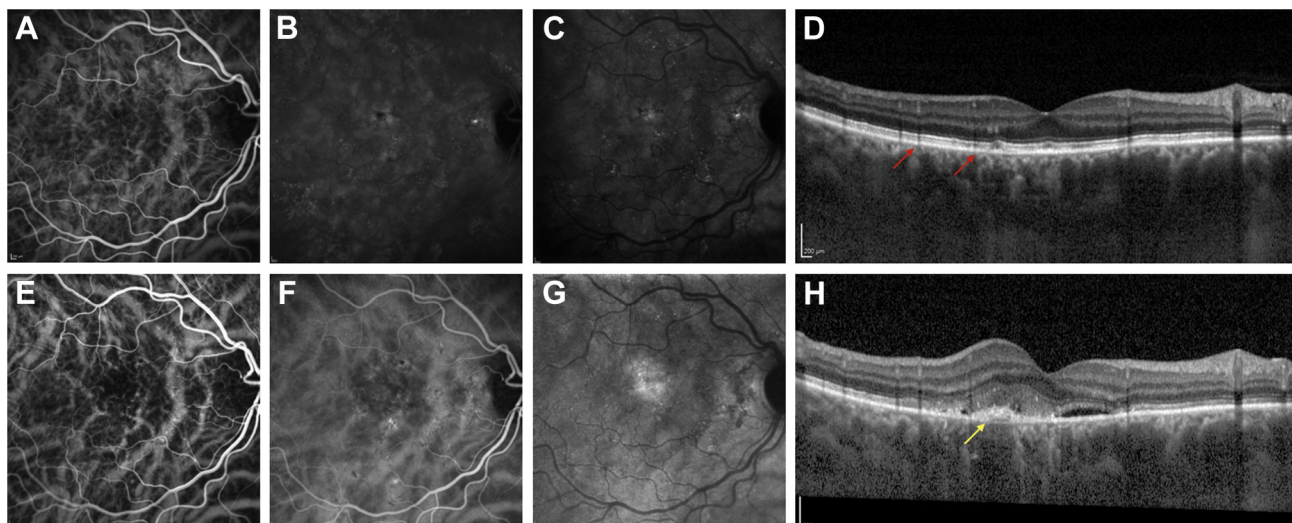


FIGURE 5. Multimodal imaging of a patient with “resolved” chronic central serous chorioretinopathy and developing type 1 CNV. (Top) Baseline. (Bottom) 18-month follow-up visit. (A, B, C) Early, mid-, and late-phase ICGA reveals choroidal hyperpermeability and absence of CNV. (D) Structural optical coherence tomography (OCT) image reveals the presence of baseline risk factors for CNV development, including inner choroidal attenuation (red arrows). At the 18-month follow-up visit, (E, F, G) early, mid- and late-phase ICGA displays a hyperfluorescent macular lesion. (H) Structural OCT confirms the presence of a type 1 CNV (yellow arrow) with subretinal hyper-reflective material and fluid. The location of the neovascularization on the structural OCT corresponds with the hyperfluorescent area on ICGA. CNV = choroidal neovascularization; ICGA = indocyanine green angiography; OCT = optical coherence tomography.

DISCUSSION

IN THIS LONGITUDINAL INVESTIGATION, BASELINE PREDICTORS of macular complications were explored in patients with “resolved” chronic CSC. Overall, novel OCT risk factors were reported for developing macular complications (eg, choroidal neovascularization and large RPE atrophy) within 36 months of follow-up. Furthermore, the fellow eyes of patients with CSC-associated macular complications in 1 eye were demonstrated to be at higher risk for development of CNV. Among the demographic and clinical factors, age, sex, and previous PDT exposure, did not significantly impact the 3-year progression to macular complications.

Choroidal neovascularization is a potential and well-characterized complication of CSC with an estimated prevalence ranging between 5.8% and 24.0%.^{4,11,37,40} Consistently, in this study cohort of eyes with “resolved” CSC at baseline, the CNV prevalence was approximately 13% at 3 years of follow-up. In agreement with previous studies, all these cases were complicated by the proliferation of type 1 CNV. In a previous important study by Mrejen and associates,¹¹ the occurrence of CNV was significantly associated with worse VA at the last visit. The current study confirms these previous findings, giving evidence that eyes developing CNV were characterized by a worse VA at the final visit. The latter aspect further highlights the importance of identifying potential risk factors for progression to CNV.

In this study, the presence of inner choroidal attenuation on structural OCT images was associated with a greater risk for progression to CNV. Several previous reports using structural OCT have demonstrated that eyes with CSC may be characterized by an attenuation of the inner choroid. This OCT finding was hypothesized to be secondary to a primary atrophy of the choriocapillaris or, alternatively, to occur because of mechanical compression from underlying enlarged vessels.^{20,21} In eyes with CSC, an attenuation of the inner choroid was suggested to culminate in raised VEGF levels in the sub-RPE compartment.⁴¹ Therefore, outer retinal ischemia has been proposed as the mechanism driving the development of CNV in CSC eyes.^{11,42} In this study’s analysis, the presence of inner choroidal attenuation was a consistent risk factor for progression to CNV in accordance with previous findings that choroidal ischemia may drive the emergence and growth of choroidal pathological vessels in these eyes.

In our analysis, the presence of intraretinal hyper-reflective foci was an additional baseline risk factor for development of CNV. In CSC eyes, even though their precise nature is not well understood, it has been hypothesized that the OCT findings may represent intraretinally migrated RPE cells.²⁷ As proposed in other chorioretinal disorders,⁴³ the current finding that the presence of hyper-reflective foci is a risk factor for CNV development may be related to migrated RPE cells producing angiogenic cytokines such as VEGF.

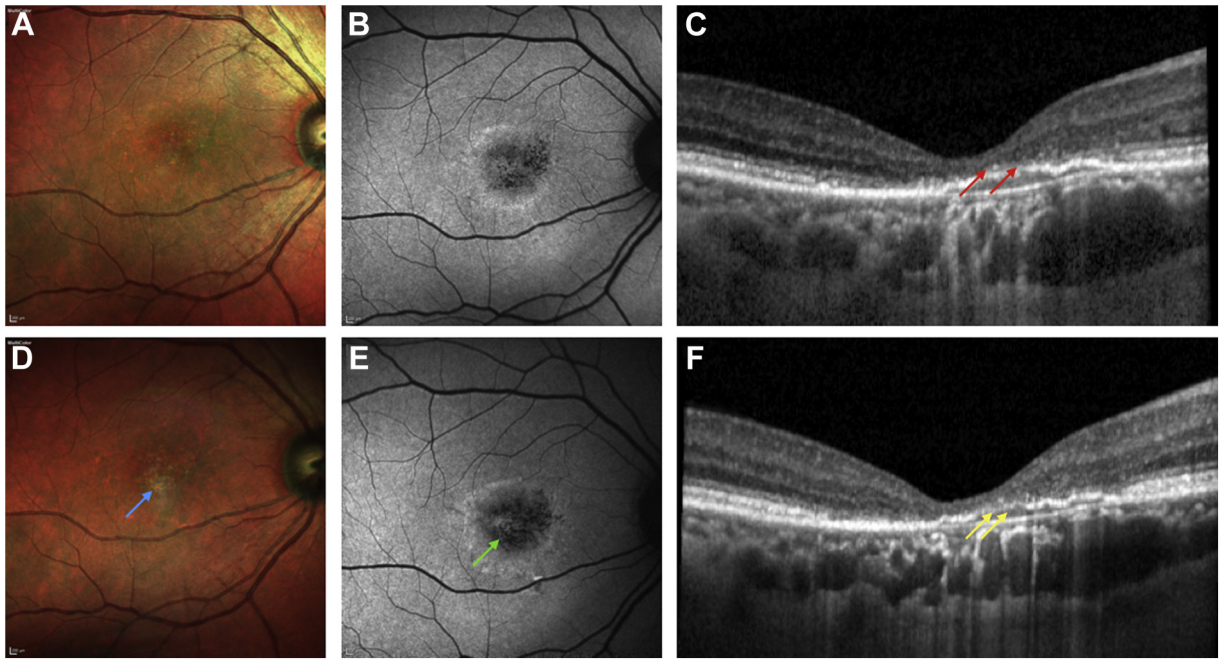


FIGURE 6. Multimodal imaging of a patient with “resolved” chronic central serous chorioretinopathy and developing a large area of RPE atrophy. (Top) Baseline. (Bottom) 22-month follow-up visit. (A) Multicolor image shows areas of RPE alteration and mottling in the macula. (B) Blue fundus autofluorescence demonstrates hypoautofluorescent pinpoint dots secondary to focal RPE defects. (C) Structural OCT image reveals the presence of baseline risk factors for large RPE atrophy development, including outer nuclear layer thinning (red arrows). At the 22-month follow-up visit, (D) multicolor image demonstrates a whitish region (blue arrow) that was hypoautofluorescent (green arrow) on the corresponding (E) blue fundus autofluorescence image. (F) The latter region corresponds to a large area of RPE atrophy (yellow arrows) that was graded as being present on the basis of the Classification of Atrophy Meeting³¹ in cases with evidence of choroidal hypertransmission (at least 250 μm in diameter) associated with a RPE defect and thinning of the outer retina. OCT = optical coherence tomography; RPE = retinal pigment epithelium.

It is noteworthy that 1 eye was included for each patient in order to investigate the fellow eye status as a risk factor for development of macular complications. In the current analysis using the multivariate model, baseline macular complication in the fellow eye was associated with a higher risk of CNV development within 3 years. These results may support the theory that CSC is a bilateral disorder with chorioretinal disturbances affecting either eye.⁴⁴⁻⁴⁶ Furthermore, considering that the fellow eyes of patients with unilateral late, age-related macular degeneration are known to be at a higher risk for development of the exudative neovascular form, these findings further suggest the presence of some overlap in the biological pathways involved in age-related macular degeneration and CSC.

We also investigated risk factors for development of macular, large RPE atrophy, which was defined as a region of defective RPE (at least 250 μm in diameter) associated with choroidal hypertransmission and thinning of the outer retina. Using multimodal imaging, Takahashi and associates⁹ recently performed a retrospective study with 92 eyes of 92 patients characterized by areas of geographic atrophy. The authors demonstrated that 21 patients (22.8%) were actually characterized by a “pachychoroid” phenotype, rather than an “age-related macular degeneration”

phenotype, and concluded also that eyes showing a pachychoroid spectrum (eg, CSC) may be complicated by the development of large regions of RPE atrophy. In the current study cohort, the prevalence of this macular complication was approximately 13%. Assuming that development of macular areas of RPE atrophy is a potentially sight-threatening evolution in CSC eyes,¹⁰ the identification of risk factors may be beneficial to prevent this complication and to better understand clinical pathways leading to its occurrence.

Our analysis revealed that the presence of inner choroidal attenuation, ONL thinning, and dome-shaped PED were risk factors for atrophy within 3 years. As noted above, an attenuation of the inner choroid may indicate an overall ischemia of the unit consisting of an outer retina, RPE, and choroid. Therefore, this OCT finding may be associated with further impairment of the RPE and a greater likelihood of atrophy. Assuming that OCT signs of choroidal ischemia were found to be longitudinally associated with both RPE atrophy and CNV development, the current findings support the hypothesis proposed by Grossniklaus and Green⁴² that a type 1 CNV may serve to nourish the outer retina and RPE. Similar to the latter findings, this study also demonstrates that an ONL thinning

was significantly associated with the development of large areas of RPE atrophy. Assuming that photoreceptors, RPE, Bruch's membrane, and inner choroid are collectively components of a tightly knit, symbiotic unit,³ a thinning of the ONL may also reflect damage of this unit, ultimately resulting in large regions of RPE atrophy.

Notably, the presence of dome-shaped PEDs was the most predictive of the 3 parameters. The development of dome-shaped PEDs is thought to be secondary to a sustained elevation of the hydrostatic pressure below the RPE.¹⁷ This may eventually result in PED's collapse and consequent RPE atrophy. This parallels the findings reported by Mudvari and associates,⁴⁷ who studied 34 patients with CSC and dome-shaped PED, who had undergone structural OCT imaging and had a mean follow-up of 49 months. That study demonstrated that the most common clinically observed outcome in these patients was complete resolution of dome-shaped PED with subsequent development of RPE atrophy. Recently, Asif and associates⁴⁸ showed that treatment with PDT may result in a regression of dome-shaped PEDs. Taking these findings together, the PDT treatment may be beneficial for preventing the development of RPE atrophy.

CMD represents a significant complication that may occur during the natural course of CSC and is significantly associated with worse VA in these patients.¹¹ The present analysis revealed that OCT imaging and demographic factors did not impact the 3-year progression to CMD. However, in the current study cohort, the event rate for CMD development was low as only 2 patients had this complication. Therefore, the present study may have been underpowered in the assessment of risk factors for development

of CMD. Future studies with a large sample and a longer prospective analysis may help to clarify this point.

The present study has limitations that must be taken into account. First, the cohort was not part of a large multicenter trial, and patients were not followed at regular intervals. However, only patients with at least 3 yearly follow-up visits over a period of 3 years were included, and this may have circumscribed this limitation. Second, as previously stated, our cohort consisted of patients with "resolved" CSC in at least 1 eye. Therefore, the analysis can be applied only to that group of participants and may differ in cases not obtaining fluid reabsorption. Conversely, predicting progression in eyes with "resolved" CSC may be remarkably relevant for the overall visual outcome of these patients and may assist the clinician to evaluate the pathologic features, to inform patients of the risks, and to define the best strategy for follow-up. Another limitation is that OCT angiography was not available for this retrospective analysis to confirm the presence or absence of CNV in cases with flat, irregular PEDs. However, as stated above, a multimodal imaging approach was part of the regular clinical practice in eyes with suspected CNV. This study also has strengths, including the use of standardized data accumulated over 3 years of follow-up and the use of 2 masked, independent, and experienced readers for each image.

In conclusion, this longitudinal study provides novel OCT imaging risk factors for development of macular complications in eyes with "resolved" CSC. Our findings may be used to guide clinical care of patients with this disorder and may be potentially important to select and randomize eyes for future intervention clinical trials.

ALL AUTHORS HAVE COMPLETED AND SUBMITTED THE ICMJE FORM FOR DISCLOSURE OF POTENTIAL CONFLICTS OF INTEREST and none were reported. F.B. is a consultant for Alcon, Alimera Sciences, Allergan, Farmila-Thea, Bayer, Schering-Pharma, Bausch and Lomb, Genentech, Hoffmann-LaRoche, Novagali Pharma, Novartis, Sanofi-Aventis, Thrombogenics, and Zeiss. G.Q. is a consultant for Alimera Sciences, Allergan, Amgen, Bayer Schering-Pharma, Heidelberg, KBH, LEH Pharma, Lumithera, Novartis, Sandoz, Sifi, Sooft-Fidea, and Zeiss. All other authors have reported that they have no relationships relevant to the contents of this paper to disclose.

REFERENCES

1. Gass JD. Pathogenesis of disciform detachment of the neuroepithelium. *Am J Ophthalmol* 1967;63(3):1-139.
2. Kaye R, Chandra S, Sheth J, Boon CJF, Sivaprasad S, Lotery A. Central serous chorioretinopathy: an update on risk factors, pathophysiology and imaging modalities. *Prog Retin Eye Res* 2020. Online ahead of print.
3. Borrelli E, Sarraf D, Freund KB, Sadda SR. OCT angiography and evaluation of the choroid and choroidal vascular disorders. *Prog Retin Eye Res* 2018;67:30-55.
4. Spaide RF, Campeas L, Haas A, et al. Central serous chorioretinopathy in younger and older adults. *Ophthalmology* 1996; 103(12):2070-2080.
5. Singh SR, Matet A, Van Dijk EHC, et al. Discrepancy in current central serous chorioretinopathy classification. *Br J Ophthalmol* 2019;103(6):737-742.
6. van Rijssen TJ, van Dijk EHC, Yzer S, et al. Central serous chorioretinopathy: towards an evidence-based treatment guideline. *Prog Retin Eye Res* 2019;73:100770.
7. Fung AT, Yannuzzi LA, Bailey Freund K. Type 1 (subretinal pigment epithelial) neovascularization in central serous chorioretinopathy masquerading as neovascular age-related macular degeneration. *Retina* 2012;32(9): 1829-1837.
8. Iida T, Yannuzzi LA, Spaide RF, Borodoker N, Carvalho CA, Negrão S. Cystoid macular degeneration in chronic central serous chorioretinopathy. *Retina* 2003;23(1):1-7.
9. Takahashi A, Ooto S, Yamashiro K, et al. Pachychoroid geographic atrophy: clinical and genetic characteristics. *Ophthalmol Retin* 2018;2(4):295-305.
10. Imamura Y, Fujiwara T, Spaide RF. Fundus autofluorescence and visual acuity in central serous chorioretinopathy. *Ophthalmology* 2011;118(4):700-705.

11. Mrejen S, Balaratnasingam C, Kaden TR, et al. Long-term visual outcomes and causes of vision loss in chronic central serous chorioretinopathy. *Ophthalmology* 2019;126(4):576–588.
12. Peiretti E, Caminiti G, Serra R, Querques L, Pertile R, Querques G. Anti-vascular endothelial growth factor therapy versus photodynamic therapy in the treatment of choroidal neovascularization secondary to central serous chorioretinopathy. *Retina* 2018;38(8):1526–1532.
13. Lai TYY, Staurengi G, Lanzetta P, et al. Efficacy and safety of ranibizumab for the treatment of choroidal neovascularization due to uncommon cause: twelve-month results of the MINERVA study. *Retina* 2017;38(8):1464–1477.
14. Chhablani J, Kozak I, Pichi F, et al. Outcomes of treatment of choroidal neovascularization associated with central serous chorioretinopathy with intravitreal antiangiogenic agents. *Retina* 2015;35(12):2489–2497.
15. Chhablani J, Pichi F, Silva R, et al. Antiangiogenics in choroidal neovascularization associated with laser in central serous chorioretinopathy. *Retina* 2016;36(5):901–908.
16. Lee G II, Kim AY, Kang SW, et al. Risk factors and outcomes of choroidal neovascularization secondary to central serous chorioretinopathy. *Sci Rep* 2019;9(1):3927.
17. Daruich A, Matet A, Dirani A, et al. Central serous chorioretinopathy: recent findings and new physiopathology hypothesis. *Prog Retin Eye Res* 2015;48:82–118.
18. Warrow DJ, Hoang QV, Freund KB. Pachychoroid pigment epitheliopathy. *Retina* 2013;33(8):1659–1672.
19. Ferrara D, Mohler KJ, Waheed N, et al. En face enhanced-depth swept-source optical coherence tomography features of chronic central serous chorioretinopathy. *Ophthalmology* 2014;121(3):719–726.
20. Dansingani KK, Balaratnasingam C, Naysan J, Freund KB. En face imaging of pachychoroid spectrum disorders with swept-source optical coherence tomography. *Retina* 2016;36(3):499–516.
21. Sakurada Y, Fragiotta S, Leong BCS, Parikh R, Hussnain SA, Freund KB. Relationship between choroidal vascular hyperpermeability, choriocapillaris flow density, and choroidal thickness in eyes with pachychoroid pigment epitheliopathy. *Retina* 2020;40(4):657–662.
22. Shin YU, Lee BR. Retro-mode imaging for retinal pigment epithelium alterations in central serous chorioretinopathy. *Am J Ophthalmol* 2012;154(1):155–163.
23. Matsumoto H, Sato T, Kishi S. Outer nuclear layer thickness at the fovea determines visual outcomes in resolved central serous chorioretinopathy. *Am J Ophthalmol* 2009;148(1):105–110.
24. Ojima Y, Hangai M, Sasahara M, et al. Three-dimensional imaging of the foveal photoreceptor layer in central serous chorioretinopathy using high-speed optical coherence tomography. *Ophthalmology* 2007;114(12):2197–2207.
25. Piccolino FC, De La Longrais RR, Ravera G, et al. The foveal photoreceptor layer and visual acuity loss in central serous chorioretinopathy. *Am J Ophthalmol* 2005;139(1):87–99.
26. Ahlers C, Geitzenauer W, Stock G, Golbaz I, Schmidt-Erfurth U, Prunte C. Alterations of intraretinal layers in acute central serous chorioretinopathy. *Acta Ophthalmol* 2009;87(5):511–516.
27. Kon Y, Iida T, Maruko I, Saito M. The optical coherence tomography–ophthalmoscope for examination of central serous chorioretinopathy with precipitates. *Retina* 2008;28(6):864–869.
28. Yalcinbayir O, Gelisken O, Akova-Budak B, Ozkaya G, Gorkem Cevik S, Yucel AA. Correlation of spectral domain optical coherence tomography findings and visual acuity in central serous chorioretinopathy. *Retina* 2014;34(4):705–712.
29. Huang Y, Gangaputra S, Lee KE, et al. Signal quality assessment of retinal optical coherence tomography images. *Invest Ophthalmol Vis Sci* 2012;53(4):2133–2141.
30. Nassisi M, Lei J, Abdelfattah NS, et al. OCT risk factors for development of late age-related macular degeneration in the fellow eyes of patients enrolled in the HARBOR study. *Ophthalmology* 2019;126(12):1667–1674.
31. Sadda SR, Guymer R, Holz FG, et al. Consensus definition for atrophy associated with age-related macular degeneration on OCT: classification of atrophy report 3. *Ophthalmology* 2018;125(4):537–548.
32. Spaide RF, Hall L, Haas A, et al. Indocyanine green videoangiography of older patients with central serous chorioretinopathy. *Retina* 1996;16(3):203–213.
33. Pang CE, Freund KB. Pachychoroid neovasculopathy. *Retina* 2015;35(1):1–9.
34. Nassisi M, Fan W, Shi Y, et al. Quantity of intraretinal hyperreflective foci in patients with intermediate age-related macular degeneration correlates with 1-year progression. *Invest Ophthalmol Vis Sci* 2018;59(8):3431–3439.
35. Borrelli E, Zuccaro B, Zucchiatti I, et al. Optical coherence tomography parameters as predictors of treatment response to eplerenone in central serous chorioretinopathy. *J Clin Med* 2019;8(9):1271.
36. Van Velthoven MEJ, Verbraak FD, Garcia PM, Schlingemann RO, Rosen RB, De Smet MD. Evaluation of central serous retinopathy with en face optical coherence tomography. *Br J Ophthalmol* 2005;89(11):1483–1488.
37. Hage R, Mrejen S, Krivosic V, Quentel G, Tadayoni R, Gaudric A. Flat irregular retinal pigment epithelium detachments in chronic central serous chorioretinopathy and choroidal neovascularization. *Am J Ophthalmol* 2015;159(5):890–903.
38. Bousquet E, Bonnin S, Mrejen S, Krivosic V, Tadayoni R, Gaudric A. Optical coherence tomography angiography of flat irregular pigment epithelium detachment in chronic central serous chorioretinopathy. *Retina* 2018;38(3):629–638.
39. Landis JR, Koch GG. The measurement of observer agreement for categorical data. *Biometrics* 1977;33(1):159–174.
40. Peiretti E, Ferrara DC, Caminiti G, Mura M, Hughes J. Choroidal neovascularization in caucasian patients with longstanding central serous chorioretinopathy. *Retina* 2015;35(7):1360–1367.
41. Bonini Filho MA, De Carlo TE, Ferrara D, et al. Association of choroidal neovascularization and central serous chorioretinopathy with optical coherence tomography angiography. *JAMA Ophthalmol* 2015;133(8):899–906.
42. Grossniklaus HE, Green WR. Choroidal neovascularization. *Am J Ophthalmol* 2004;137(3):496–503.
43. Spaide RF, Armstrong D, Browne R. Choroidal neovascularization in age-related macular degeneration—what is the cause? *Retina* 2003;23(5):595–614.
44. Guyer DR, Yannuzzi LA, Slakter JS, Sorenson JA, Ho A, Orlock D. Digital indocyanine green videoangiography of central serous chorioretinopathy. *Arch Ophthalmol* 1994;112(8):1057–1062.

45. Imamura Y, Fujiwara T, Margolis R, Spaide RF. Enhanced depth imaging optical coherence tomography of the choroid in central serous chorioretinopathy. *Retina* 2009;29(10):1469–1473.
46. Borrelli E, Battista M, Gelormini F, et al. Photoreceptor outer segment is expanded in the fellow eye of patients with unilateral central serous chorioretinopathy [Online ahead of print]. *Retina* 2020; <https://doi.org/10.1097/IAE.0000000000002846>.
47. Mudvari SS, Goff MJ, Fu AD, et al. The natural history of pigment epithelial detachment associated with central serous chorioretinopathy. *Retina* 2007;27(9):1168–1173.
48. Arif F, Pryds A, Larsen M. Isolated pigment epithelium detachment: evidence for relation to central serous chorioretinopathy and effect of photodynamic therapy. *Acta Ophthalmol* 2018;96(8):821–827.