



# Application of pamidronate disodium for the treatment of diffuse sclerosing osteomyelitis of the mandible: A clinical study

Xiaoli Li, MD, Kuankuan Jia, MB, Jingang An, MD, and Yi Zhang, MD

**Objective.** This study aimed to assess the clinical effectiveness of using pamidronate disodium to treat patients with diffuse sclerosing osteomyelitis of the mandible (DSOM).

**Study Design.** Patients with DSOM who were hospitalized in the Department of Oral and Maxillofacial Surgery, Peking University Hospital of Stomatology (Beijing, China), between March 2018 and March 2019 were included. All patients were treated with intravenous administration of pamidronate disodium for 3 days. Pain intensity, mouth opening, blood workup findings, imaging examination findings, and incidence of complications before and after treatment and during the follow-up period, were recorded and compared.

**Results.** Forty-three patients were treated with pamidronate disodium. Adverse reactions, including fever, hypocalcemia, hypokalemia, and diarrhea, were observed during treatment. Fourteen patients had moderate to severe pain before treatment, and the pain was markedly alleviated after days 2 and 3 of treatment. Pain and swelling were found to have disappeared at the 6-month follow-up in 39 patients (90.7%). Mean mouth opening increased from 28.5 mm to 38.1 mm. Imaging examinations showed that the bone mass in the affected area had markedly improved in 32 patients (74.4%).

**Conclusions.** Pamidronate disodium alleviated pain and swelling and improved mouth opening in patients with DSOM. Follow-up after 6 to 18 months demonstrated stable treatment effectiveness. (Oral Surg Oral Med Oral Pathol Oral Radiol 2020;130:616–624)

Diffuse sclerosing osteomyelitis of the mandible (DSOM) is a nonsuppurative osteomyelitis, which is mainly characterized by recurrent local mandibular swelling and pain, with restricted mouth opening.<sup>1-3</sup> The imaging characteristics of this disease include sclerosis of cancellous bone, destruction of cortical bone, and periosteal reaction in the lesion area. The etiology of this disease remains unclear, and symptoms are atypical; therefore, DSOM is frequently misdiagnosed as fibrous dysplasia of bone or suppurative osteomyelitis in clinical practice.

DSOM occurs not only in the mandible but also in the long bones of children and adolescents; therefore, it is also termed *chronic recurrent multifocal osteomyelitis* (CRMO).<sup>4</sup> It has been suggested that DSOM/CRMO is a manifestation of SAPHO (synovitis, acne, pustulosis, hyperostosis, and osteitis) syndrome.<sup>4,5</sup> The major characteristics of SAPHO syndrome, which is an autoimmune disease, include bone and joint damage, with or without skin damage.<sup>4,6</sup> SAPHO syndrome is a rare disease, with an incidence of about 1 in 10,000.<sup>6</sup>

Currently, there is no standard treatment for DSOM because of lack of studies with large sample sizes. The effectiveness of surgical treatments for

this disease remains uncertain, and the symptoms tend to recur. In some cases, surgical treatment might accelerate destruction of the jaws. In addition to surgical treatment, drug therapy is also commonly used to treat DSOM. However, the effectiveness of different drugs can be unsatisfactory. Antibiotics, nonsteroidal anti-inflammatory drugs (NSAIDs), and glucocorticoids could effectively alleviate the symptoms; however, their long-term effectiveness remains suboptimal, resulting in disease recurrence.<sup>2,7-9</sup> Disease-modifying antirheumatic drugs (e.g., methotrexate) have certain effectiveness in the treatment of DSOM; however, this effectiveness is mainly observed in patients with peripheral arthritis.<sup>10</sup> Biologic products, including anti-tumor necrosis factor drugs, are reported to have relatively high effectiveness in the treatment of DSOM, but only a few cases in which this drug was used have been reported to date.<sup>11</sup> The application of bisphosphonates to treat DSOM has shown some advantages, including rapid effectiveness and a low recurrence rate.<sup>12,13</sup> Hence, the present study aimed to summarize and analyze the clinical effectiveness of intravenous (IV) administration of pamidronate

Department of Oral and Maxillofacial Surgery, School and Hospital of Stomatology, Peking University, Beijing, PR China.

Received for publication Dec 20, 2019; returned for revision May 31, 2020; accepted for publication Jun 30, 2020.

© 2020 Elsevier Inc. All rights reserved.

2212-4403/\$-see front matter

<https://doi.org/10.1016/j.oooo.2020.06.023>

## Statement of Clinical Relevance

This report summarizes the clinical effectiveness and the evident advantages of treatment with pamidronate disodium in patients with diffuse sclerosing osteomyelitis (DSOM).

disodium, a nitrogen-containing bisphosphonate, in the treatment of DSOM.

**MATERIALS AND METHODS**

**Study patients**

The study included patients with DSOM who were hospitalized in the Department of Oral and Maxillofacial Surgery, Peking University Hospital of Stomatology (Beijing, China), between March 2018 and March 2019. All patients provided signed informed consent to undergo pamidronate infusions, and their pain levels before and after infusion were documented. Approval for the evaluation of the results from chart reviews and available information was provided by the local ethics committee (PKUSSIRB201838119).

The inclusion criteria were as follows: (1) male or female patients age greater than 5 years; (2) clinical diagnosis of DSOM, comprising recurrent swelling, pain, and restricted mouth opening in the mandible, but no suppurative manifestations; and imaging examination results (e.g., panoramic radiography, spiral computed tomography [CT], and whole body radioisotope scanning) suggesting DSOM; and (3) presence of pathologically confirmed histopathologic features of DSOM, such as irregular shape of the bone trabecula, formation of restorative and reactive bone trabeculae, and mild to moderate fibrosis of bone marrow with rich blood vessels. The exclusion criteria were as follows: (1) presence of systemic disorders not suitable for treatment with bisphosphonates; (2) being pregnant or lactating; (3) allergy to bisphosphonates; and (4) presence of pathologically confirmed tumors.

**Treatments**

Careful oral examination was conducted before initiating treatment. Teeth that could not be saved were extracted, and other affected teeth received composite resin filling treatment or root canal therapy. The visual analogue scale (VAS) was used to assess pain intensity in patients (Table I). The degree of mouth opening was recorded.

IV administration of bisphosphonates was conducted for 3 continuous days. The dose details are as follows:

- For patients age 5 to 12 years: 30 mg of pamidronate disodium dissolved in 500 mL of normal saline for IV administration (once per day) for 3 continuous days
- For patients age 12 to 18 years: 45 mg of pamidronate disodium dissolved in 500 mL of normal saline for IV administration (once per day) for 3 continuous days
- For patients age 18 to 60 years: 60 mg of pamidronate disodium dissolved in 500 mL of normal saline for IV administration (once per day) for 3 continuous days;
- For patients age greater than 60 years: 45 mg of pamidronate disodium dissolved in 500 mL of normal saline for IV administration (once per day) for 3 continuous days

Changes in parameters, such as body temperature, routine blood values, and electrolytes, were monitored during drug therapy, and adverse responses during treatment were also observed, recorded, and treated in a timely manner. The patients were hospitalized for 1 additional day after treatment completion to monitor for any further adverse responses. Pain intensity and mouth opening were also recorded. Patients with no evident adverse responses were discharged, and regular re-examinations were conducted.

The study patients were followed up at 1, 3, and 6 months after drug therapy, and the following items were included during re-examination at follow-up: (1) for patients with pain re-appearance, VAS classification was used to record the pain intensity; (2) the degree of mouth opening was recorded; (3) panoramic radiography and CT images were obtained to assess changes in the mandibular region; (4) routine blood values, liver and renal functions, and electrolytes were evaluated; and (5) any other patient discomforts were also recorded.

**RESULTS**

**General characteristics**

In total, 43 patients (including 13 males [30.2%] and 30 females [69.8%]) were included in this study. The

**Table I.** VAS scores of patients with DSOM of the mandible before and after treatment

	No pain	Mild pain			Moderate pain			Severe pain				Total
	0	1	2	3	4	5	6	7	8	9	10	
Before treatment	0	0	0	4	5	2	7	9	16	0	0	43
After treatment	32	2	3	2	3	0	0	1	0	0	0	43
At 1 month	29	2	4	3	0	2	0	0	0	0	0	40
At 3 months	29	0	1	0	2	0	2	0	0	0	0	34
> 6 months	39	0	1	0	0	0	1	2	0	0	0	43

DSOM, diffuse sclerosing osteomyelitis; VAS, visual analogue scale.

mean age of the patients was 25.7 years (range 6–73 years), and 19 patients (44.2%) patients were younger than 18 years of age. Most of the patients had moderate to severe pain (VAS score > 4). The total time that the patients had suffered from DSOM ranged from 6 months to 18 years (mean 35.1 months). Previous treatments did not have any positive effects. In terms of surgical treatments, 38 patients (88.4%) underwent curettage or decortication, but pain and swelling in the mandibular region reappeared after 1 to 5 months. Three of the remaining 5 patients underwent biopsy, and 2 did not undergo surgery to avoid the significant morbidity resulting from surgery. In terms of dental therapies, 19 patients (44.2%) were treated with tooth extraction and root canal therapy; however, their symptoms were not alleviated. In terms of drug treatment histories, 36 patients (83.7%) were treated with antibiotics; 32 patients (74.4%) were treated with NSAIDs; 25 patients (58.1%) were treated with both antibiotics and NSAIDs; and 5 patients (11.6%) were treated with steroids. In all patients, symptoms were alleviated after receiving drug therapy but recurred when the drug therapy stopped. The patients' general characteristics are summarized in [Table II](#).

### Treatments

All 43 patients were treated with IV administration of pamidronate disodium for 3 continuous days, with a dose of 30 to 60 mg per day. Moderate to severe pain was present in 14 patients before undergoing treatment, and alleviation was evident on day 2 and day 3 after treatment.

During treatment, 39 patients (90.7%) developed a fever, and the patients' highest body temperatures ranged from 38.3°C to 40.2°C. The body temperature mostly started to increase 18 to 30 hours after initiation of drug therapy. The fever was alleviated markedly after treatment with physical cooling and/or use of NSAIDs, and the temperature returned to normal after the drug therapy ceased. The body temperatures during treatment are shown in [Figure 1](#), in which the fold line represents the trend line of the average body temperature. The adverse responses that occurred during drug therapy are presented in [Table III](#).

During treatment, 33 patients (76.7%) developed hypocalcemia (blood calcium level < 2.15 mmol/L), which mainly occurred on day 2 of treatment (in 20 patients; 60.6%). The lowest blood calcium level ranged from 1.78 to 2.10 mmol/L. IV calcium supplementation (1 g/day) was used to treat these patients, and their blood calcium levels were measured daily. Oral administration of calcium supplement was continued in these patients after discharge, and their blood calcium levels were re-evaluated at 1 month after treatment. The changes in blood calcium levels in patients

during treatment and at the 1-month follow-up are shown in [Figure 2](#).

Six patients (14%) developed hypokalemia when undergoing treatment; of these, in 4 patients, the condition developed on day 3 of treatment, and their lowest blood potassium level ranged from 2.9 to 3.1 mmol/L. For these patients, oral potassium supplementation (2 g/day) was provided as treatment. The blood potassium level of all 6 patients had returned to normal before discharge. Diarrhea occurred in 3 patients (7%) and was alleviated after drug therapy with berberine.

### Follow-up

All 43 patients were followed up for 6 to 18 months, and the follow-up rate was 100%. The VAS classification of pain in the patients is shown in [Table I](#). Pain disappeared in 39 patients (90.7%), and swelling and restricted mouth opening continued to decrease in them. In the remaining 4 patients (9.3%), treatment effectiveness was not evident, or pain and swelling recurred after treatment. Swelling and pain recurred at 4 months after treatment in 1 patient and recurred at 5 months after treatment in 1 patient. Both these patients were treated by secondary IV administration of pamidronate disodium, with identical initial doses. Symptoms were alleviated after treatment in 1 patient; however, mild to moderate pain appeared again at 1 month after treatment. In another patient also, symptoms were alleviated, but re-examination at 6 months after treatment showed persisting moderate pain. The other 2 patients reported slight improvement after treatment; however, re-examination at 6 months after treatment showed severe pain. These 2 patients were further treated with NSAIDs for short-term symptom relief, but symptoms recurred after therapy with NSAIDs ended.

The mean mouth opening of patients before treatment was 28.5 mm and was observed to have increased to 38.1 mm during re-examination at 6 months after treatment. These findings showed that mouth opening had evidently improved compared with the pretreatment level. The mouth opening values during the follow-up period are shown in [Figure 3](#).

Panoramic radiography and CT images were obtained to assess bone structural changes in the lesion area. The findings showed local bone swelling at the mandibular region, evident cortical bone destruction, and an unclear boundary between the cortical bone and the medullary substance in 32 patients before treatment. However, imaging examinations showed bone reconstruction and remodeling at 1 month after treatment. The bone structures showed evident reconstruction and remodeling at 6 to 12 months after treatment. During this period, bone mass in some patients had

**Table II.** General characteristics of the study patients

	Gender	Age (years)	Course time (months)	Previous treatments			Pamidronate treatment	
				Curettage or decortication (n)	Previous dental therapies	Previous medicines	Number of treatments (n)	Cumulative dose (mg)
1	M	19	15	1	EXT	Antibiotic, steroid	1	180
2	F	11	8	1	RCT	Antibiotic	1	90
3	F	8	216	1	No	NSAIDs, Chinese medicine	1	90
4	F	53	60	1	No	Antibiotic, NSAIDs	1	180
5	F	29	12	1	No	Antibiotic, NSAIDs	1	180
6	F	57	54	0	No	Antibiotic, NSAIDs	1	180
7	M	23	17	1	No	Antibiotic	1	180
8	F	22	11	2	No	Antibiotic, NSAIDs	1	180
9	F	73	41	7	EXT, RCT	Antibiotic, steroid	1	180
10	M	12	36	1	No	Antibiotic	1	135
11	F	64	36	1	No	Antibiotic, NSAIDs	1	135
12	M	11	14	1	No	Antibiotic	1	90
13	M	8	30	1	No	Antibiotic, NSAIDs	1	90
14	M	24	96	1	EXT	Antibiotic, NSAIDs	1	180
15	M	35	48	2	No	Antibiotic, NSAIDs	1	180
16	M	30	42	1	EXT, RCT	Antibiotic, NSAIDs	1	180
17	F	35	42	1	EXT, RCT	Antibiotic, NSAIDs	1	180
18	M	21	12	1	RCT	Antibiotic, NSAIDs	1	180
19	F	34	60	1	No	Antibiotic, NSAIDs	1	180
20	F	9	48	1	No	Antibiotic	1	90
21	F	34	102	1	EXT, RCT	Antibiotic, NSAIDs, steroid	2	360
22	F	9	7	1	RCT	Antibiotic	1	90
23	F	12	12	1	RCT	Antibiotic, NSAIDs	1	90
24	F	70	10	0	No	Antibiotic, NSAIDs	1	180
25	F	13	18	1	No	NSAIDs	1	135
26	M	12	30	1	No	NSAIDs, Chinese medicine	1	90
27	F	6	13	1	No	Antibiotic, NSAIDs	1	90
28	M	18	25	2	EXT	Antibiotic, NSAIDs	1	135
29	F	26	66	1	EXT	NSAIDs, anti-rheumatoid drug	1	180
30	F	8	18	1	No	NSAIDs, steroid	1	90
31	F	9	24	1	No	Antibiotic, NSAIDs	1	90
32	F	53	13	0	EXT	Antibiotic, NSAIDs	1	180
33	F	12	11	1	EXT	Antibiotic, NSAIDs	1	90
34	F	52	42	0	No	Biological agent, NSAIDs	1	180
35	F	11	24	4	EXT	Antibiotic, NSAIDs	1	90
36	F	7	6	0	No	Antibiotic, NSAIDs	1	90
37	M	6	7	1	No	NSAIDs	1	90
38	F	7	15	1	No	Antibiotic, NSAIDs	1	90
39	M	8	6	1	EXT	Antibiotic, steroid	1	90
40	F	47	9	1	No	Antibiotic, NSAIDs	2	360
41	F	51	15	2	EXT	Antibiotic	1	180
42	F	23	17	1	EXT, RCT	Antibiotic, biological agent	1	180
43	F	35	120	1	EXT, RCT	Antibiotic, NSAIDs	1	180

EXT, tooth extraction; F, female; M, male; NSAID, nonsteroidal anti-inflammatory drug; RCT, root canal therapy.

returned to the normal level, and there was evident reduction in the volume of the swollen area of the mandible. Sclerosis of the cancellous bone was seen in 11 patients, but no cortical bone destruction or bone swelling at the mandibular region, and their bone structures showed slightly improvement at 6 to 12 months after treatment.

Routine blood values; renal and liver functions; and the blood levels of calcium, potassium, and chlorine were all normal during follow-up.

**Presentation of a typical case**

A 13-year-old boy was admitted to our hospital because of recurrent swelling and pain in the left mandibular region for 18 months. The boy had undergone scaling for osteomyelitis in another hospital 5 months previously. However, the swelling and pain reappeared 4 months after treatment. Thereafter, the boy was treated with NSAIDs and antibiotics, without evident effectiveness, with symptoms recurring once a month. Clinical examination revealed swelling of the

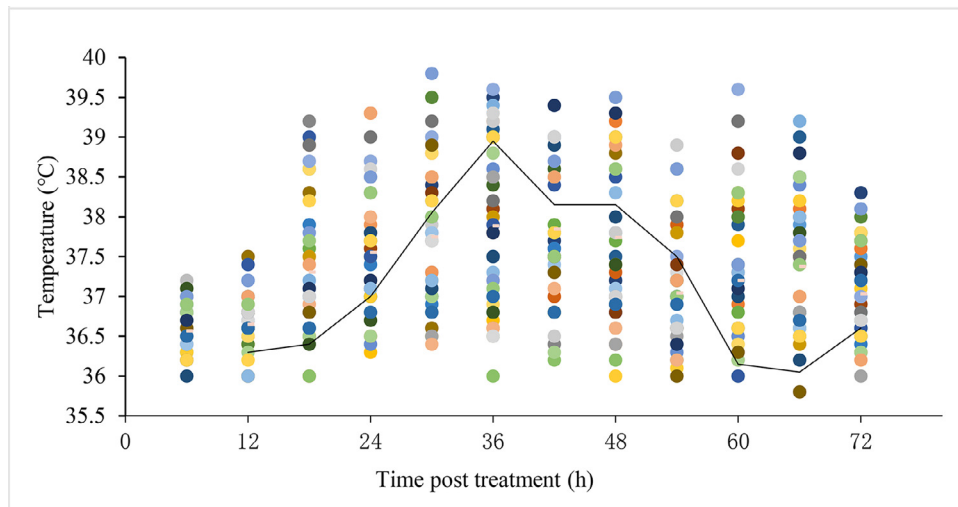


Fig. 1. The highest body temperature in patients post treatment with pamidronate disodium. (Different colored dots represent different patients.)

mandible, slight reddening of the skin, a slight increase in skin temperature, and tenderness in the anterior mandible. Imaging examination showed swelling and deformation of the mandible, the surface of the mandible was coarse, and the normal structures of the cortical bone and cancellous bone had disappeared (Figure 4). Routine blood examination revealed an increase in the white blood cell count, erythrocyte sedimentation rate, and high-sensitivity C-reactive protein levels.

Before treatment, the patient’s VAS score was 8, and his mouth opening was 24 mm. The boy was then treated with IV administration of pamidronate disodium (45 mg) for 3 consecutive days. The patient’s pain was markedly alleviated by day 2 of treatment (VAS score of 2) and disappeared after day 3 of treatment (VAS score of 0). Three days of treatment, his mouth opening was 28 mm.

Re-examination at 3 months after treatment showed reduced swelling of the mandible, the VAS score remained at 0, and mouth opening was 39 mm. Imaging examination showed that the surface of the mandible had evidently recovered, but sclerosis of the cancellous

bone still existed (Figure 5). Re-examination at 12 months after treatment showed that the VAS score was 0, and mouth opening was 49 mm. Imaging examination showed that the surface of the mandible remained smooth, and the appearance, volume, and structure of bone were almost normal (Figure 6).

**DISCUSSION**

DSOM, a rare, chronic, and recurrent nonsuppurative osteomyelitis of the jaws, occurs mainly in the ascending ramus and in body of the mandible. Generally, DSOM occurs on one side and manifests mainly as local pain, swelling, and restricted mouth opening. DSOM was first reported by Marzola et al.<sup>1</sup> in 1969, who named it “chronic diffuse sclerosing osteomyelitis of the jaws.” In 1980, Jacobsson et al.<sup>2</sup> summarized the results of their treatment of 21 patients with DSOM, and cortisone showed some effectiveness in treating this disease, whereas NSAIDs, antibiotics, high-pressure oxygen, and surgery were ineffective. In 1990, Merkesteyn et al.<sup>3</sup> described the clinical manifestations of DSOM as “recurrent pain, swelling, and trismus, by radiographic findings such as localized osteolysis, and by scintigraphic findings such as an increased uptake of radiopharmakon.”

The etiologies and pathogenesis of DSOM are still unclear. Previous studies have suggested that DSOM is a type of SAPHO syndrome, and thus, its treatment is similar to the treatment for SAHPO syndrome.<sup>4,5</sup> Currently, the most commonly used methods to treat DSOM include surgery, occlusal splint therapy, hyperbaric oxygen therapy, and drug therapy.<sup>2,12,14-16</sup>

In the surgical treatment of DSOM, such as curettage for osteomyelitis and decortication, achieving good long-term effectiveness remains difficult, and the

**Table III.** Adverse reactions during treatment

Adverse reactions	First day	Second day	Third day
Fever (> 38.5°C)	3	37	39
Muscle soreness	0	10	14
Anorexia	0	16	20
Vomiting	0	2	3
Diarrhea	0	2	3
Hypocalcemia (< 2.15 mmol/L)	10	16	33
Hypokalemia (< 3.5 mmol/L)	2	3	6

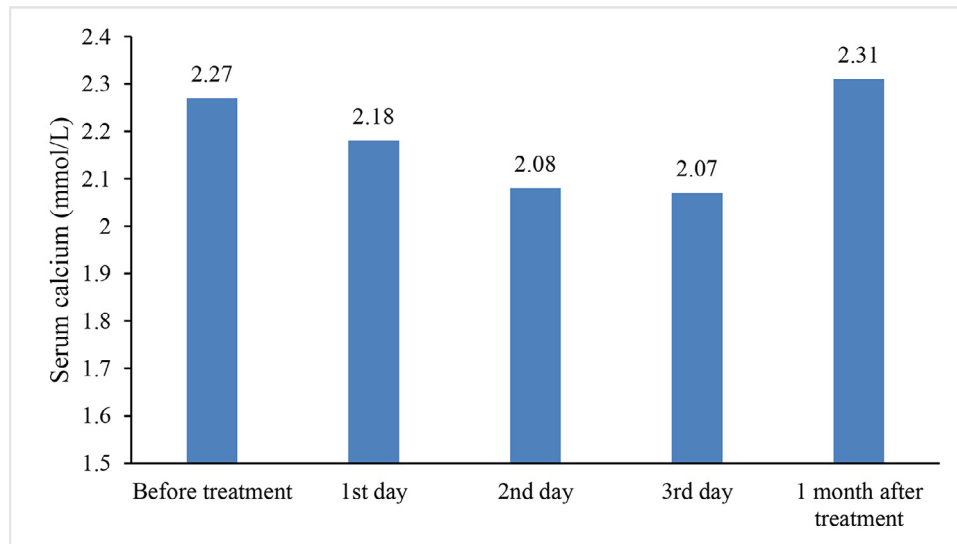


Fig. 2. Blood calcium levels in patients during and at 1-month follow-up after treatment with pamidronate disodium.

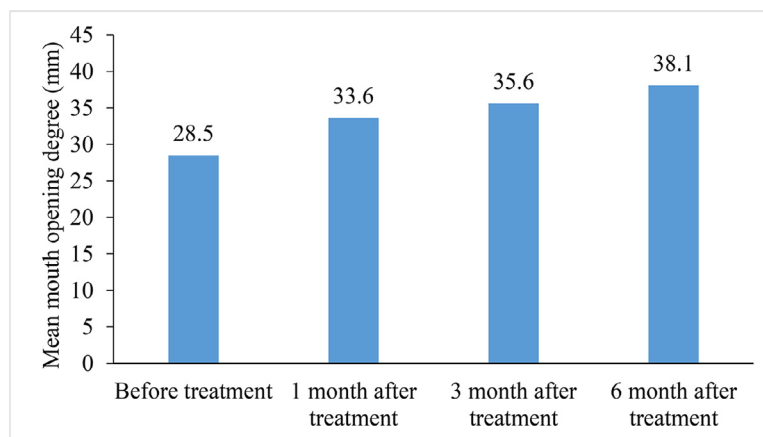


Fig. 3. Mouth opening in diffuse sclerosing osteomyelitis (DSOM) of the mandible before and after treatment, as well as during the follow-up period.

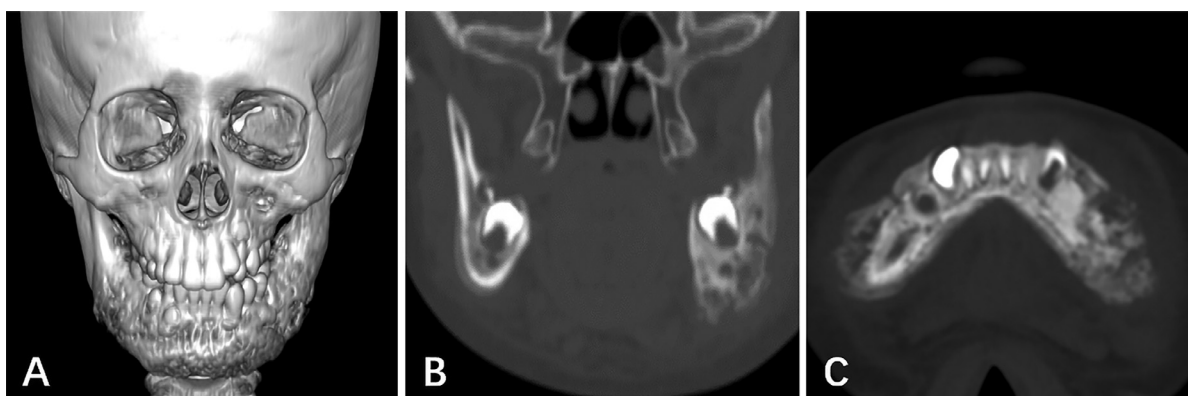


Fig. 4. Computed tomography (CT) images before drug therapy, showing hypertrophy and deformity of the mandible, as well as coarse bone cortex and sclerosis of the cancellous substance.

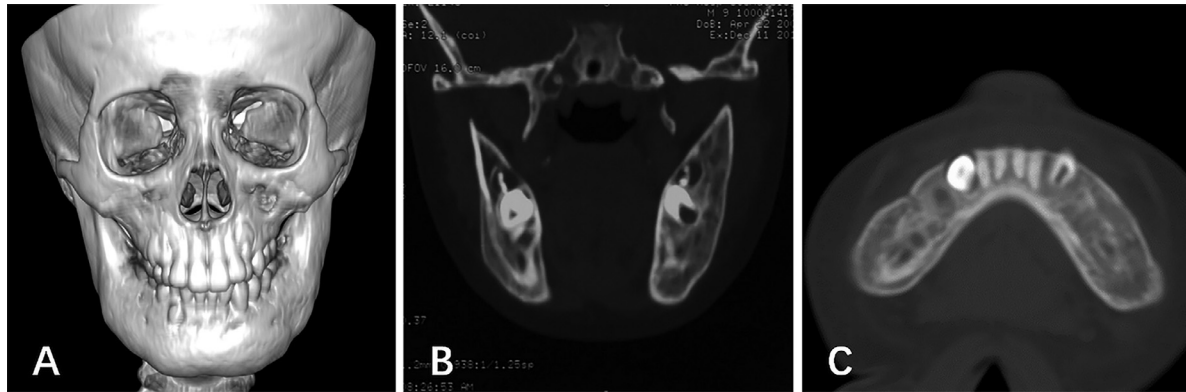


Fig. 5. Computed tomography (CT) images at 3 months after treatment, showing evident bone cortex reconstruction, but sclerosis of the cancellous substance are still present.

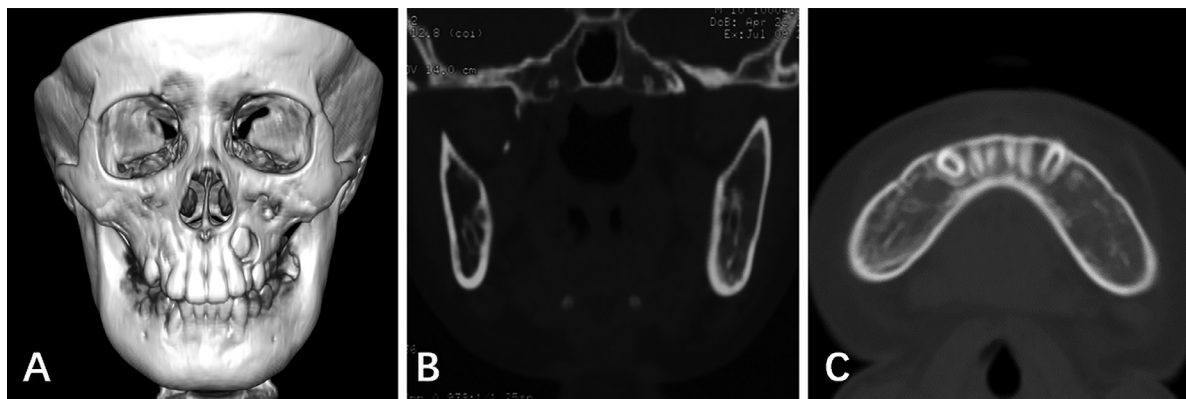


Fig. 6. Computed tomography (CT) images at 12 months after treatment, showing a smooth mandibular surface and decreased volume of the affected mandibular region. The bone cortex and the cancellous substance of the mandible are almost normal.

disease tends to recur.<sup>2,14</sup> In the present study, 38 patients (88.4%) underwent curettage or decortication; however, pain and swelling in the mandibular region reappeared after 1 to 5 months. Some researchers have used segmental mandibulectomy to remove the lesion, followed by fibular flap for reconstruction. However, new lesions still appeared in other mandibular regions, and ultimately, total mandibulectomy, fibular flap reconstruction, and bilateral total joint prostheses reconstructions were conducted.<sup>15</sup>

DSOM occurs mainly at the ascending ramus and in the body of the mandible and is accompanied by edema and hypertrophy of the surrounding soft tissue. Therefore, some researchers have proposed the “chronic tendoperiostitis” hypothesis.<sup>3</sup> On the basis of this hypothesis, occlusal splint has been used to adjust the occlusion to alleviate chronic tendoperiostitis, correct the occlusal disorder, and, thus, treat DSOM.<sup>3,16</sup> Occlusal splints have several advantages, including fewer adverse effects, minimal invasion, and easy patient acceptance. The symptoms in 55% of patients showed marked improvement after treatment with occlusal splints.<sup>16</sup> However, this hypothesis could not

explain the disease occurring in edentulous patients or its recurrence in patients who underwent surgical resection of the mandible and occlusal reconstruction.<sup>15</sup>

According to another hypothesis, this disease is caused by microbial infection, and thus, antibiotics and hyperbaric oxygen therapy were used by some researchers as treatments; however, there was no evident improvement in symptoms after treatment.<sup>7</sup> Some researchers have reported that long-term treatment with antibiotics, especially tetracycline and/or macrolides, could alleviate the symptoms of DSOM.<sup>17</sup>

According to the autoimmune disease hypothesis, some researchers have used disease-modifying anti-rheumatic drugs for treatment. For instance, methotrexate and salazosulfapyridine have been used to treat DSOM; however, these drugs were not particularly effective.<sup>10</sup>

Bisphosphonates have been used to treat various diseases, such as Paget disease, multiple myeloma, malignant metastatic bone cancers, and osteoporosis; therefore, some researchers have used these drugs to treat DSOM, with some success.<sup>12,13,18,19</sup> Colina et al.<sup>13</sup> used IV administration of second- or third-

generation bisphosphonates for 3 continuous days to treat SAPHO syndrome, and the patients' pain was effectively alleviated. Urade et al.<sup>20</sup> used IV pamidronate for 3 continuous days to treat DSOM, and it effectively alleviated the patients' pain during days 1 to 3 of treatment.

During and after treatment with bisphosphonates, possible adverse reactions mainly include adverse systemic responses and bisphosphonate-related osteonecrosis of the jaw (BRONJ).<sup>21</sup> In the present study, the adverse drug responses during treatment included increased body temperature, decreased blood calcium, decreased blood potassium, and diarrhea. Appropriate treatments were provided, and all these adverse responses disappeared after completion of the drug therapy. BRONJ mainly occurred in patients who received repeated or long-term treatment with bisphosphonates and necrosis occurred in association with the dose and time of bisphosphonates treatment, the systemic condition of the patient, and the existence of odontogenic infection.<sup>22</sup> According to a previous study conducted in 504 patients, BRONJ did not appear until the bisphosphonate dose reached 480 mg.<sup>23</sup> In the present study, the pamidronate disodium dose was relatively low, and the treatment time was short; therefore, theoretically, osteonecrosis should not recur. However, the condition of patients' teeth should be examined carefully before drug therapy to ensure safety. For patients who require dental therapy or tooth extraction, bisphosphonates treatment should be conducted after systemic treatment, and the patients should be advised to pay continuous attention to oral hygiene after drug therapy.

## CONCLUSIONS

According to the treatment effectiveness and follow-up findings of this study, IV administration of pamidronate disodium was effective in treating patients with DSOM, with reduction in swelling and pain and improved mouth opening. Compared with surgical treatments or other drug therapies, the treatment used in this study offered several advantages, such as rapid effect and low risk of disease recurrence, with relatively mild and controllable complications. Imaging examinations at 6 and 12 months after treatment showed improvement in bone mass structure or even restoration of the normal structure in some patients. These findings demonstrate that pamidronate disodium offers advantages in treating DSOM, with cure achieved in some patients. However, the follow-up time of this study was relatively short, so further studies are warranted to investigate the long-term effectiveness of pamidronate sodium.

## REFERENCES

1. Marzola C. Chronic diffuse sclerosing osteomyelitis of the jaws. *Coop Dent (B Aires)*. 1969;36:21-23.
2. Jacobsson S, Hollender L. Treatment and prognosis of diffuse sclerosing osteomyelitis (DSO) of the mandible. *Oral Surg Oral Med Oral Path*. 1980;49:7-14.
3. van Merkesteyn JP, Groot RH, Bras J, McCarroll RS, Bakker DJ. Diffuse sclerosing osteomyelitis of the mandible: a new concept of its etiology. *Oral Surg Oral Med Oral Path*. 1990;70:414-419.
4. Kahn MF, Hayem F, Hayem G, Grossin M. Is diffuse sclerosing osteomyelitis of the mandible part of the synovitis, acne, pustulosis, hyperostosis, osteitis (SAPHO) syndrome? Analysis of seven cases. *Oral Surg Oral Med Oral Path*. 1994;78:594-598.
5. Malmstrom M, Fyhrquist F, Kosunen TU, Tasanen A. Immunological features of patients with chronic sclerosing osteomyelitis of the mandible. *Int J Oral Surg*. 1983;12:6-13.
6. Nguyen MT, Borchers A, Selmi C, Naguwa SM, Cheema G, Gershwin ME. The SAPHO syndrome. *Semin Arthritis Rheum*. 2012;42:254-265.
7. Hayem G, Bouchaud-Chabot A, Benali K, et al. SAPHO syndrome: a long-term follow-up study of 120 cases. *Semin Arthritis Rheum*. 1999;29:159-171.
8. Kotilainen P, Merilahti-Palo R, Lehtonen OP, et al. Propionibacterium acnes isolated from sternal osteitis in a patient with SAPHO syndrome. *J Rheumatol*. 1996;23:1302-1304.
9. Utumi ER, Oliveira Sales MA, Shinohara EH, et al. SAPHO syndrome with temporomandibular joint ankylosis: clinical, radiological, histopathological, and therapeutical correlations. *Oral Surg Oral Med Oral Pathol Oral Radiol Endod*. 2008;105:E67-E72.
10. Müller-Richter UD, Roldán JC, Mörtl M, Behr M, Reichert TE, Driemel O. SAPHO syndrome with ankylosis of the temporomandibular joint. *Int J Oral Maxillofac Surg*. 2009;38:1335-1341.
11. Marí A, Morla A, Melero M, Schiavone R, Rodriguez J. Diffuse sclerosing osteomyelitis (DSO) of the mandible in SAPHO syndrome: a novel approach with anti-TNF therapy. Systematic review. *J Craniomaxillofac Surg*. 2014;42:1990-1996.
12. Otto S, Troeltzsch M, Burian E, et al. Ibandronate treatment of diffuse sclerosing osteomyelitis of the mandible: pain relief and insight into pathogenesis. *J Craniomaxillofac Surg*. 2015;43:1837-1842.
13. Colina M, La Corte R, Trotta F. Sustained remission of SAPHO syndrome with pamidronate: a follow-up of fourteen cases and a review of the literature. *Clin Exp Rheumatol*. 2009;27:112-115.
14. Montonen M, Iizuka T, Hallikainen D, Lindqvist C. Decortication in the treatment of diffuse sclerosing osteomyelitis of the mandible. Retrospective analysis of 41 cases between 1969 and 1990. *Oral Surg Oral Med Oral Pathol*. 1993;75:5-11.
15. Rustemeyer J, Siegmund BJ, Okcu Y, Busch A. Total mandibular reconstruction following diffuse sclerosing osteomyelitis. *Oral Maxillofac Surg*. 2019;23:95-99.
16. van de Meent MM, Meshkini H, Fiocco M, Wetselaar-Glas MJM, Appelman-Dijkstra NM, van Merkesteyn JPR. Conservative treatment of children with chronic diffuse sclerosing osteomyelitis/tendoperiostitis of the mandible. *J Craniomaxillofac Surg*. 2017;45:1938-1943.
17. Yoshii T, Nishimura H, Yoshikawa T, et al. Therapeutic possibilities of long-term roxithromycin treatment for chronic diffuse sclerosing osteomyelitis of the mandible. *J Antimicrob Chemother*. 2001;47:631-637.
18. Kuijpers SCC, de Jong E, Hamdy NAT, van Merkesteyn RJP. Initial results of the treatment of diffuse sclerosing osteomyelitis



- of the mandible with bisphosphonates. *J Craniomaxillofac Surg.* 2011;39(1):65-68.
19. Roderick M, Shah R, Finn A, Ramanan AV. Efficacy of pamidronate therapy in children with chronic non-bacterial osteitis: disease activity assessment by whole body magnetic resonance imaging. *Rheumatology.* 2014;53:1973-1976.
  20. Urade M, Noguchi K, Takaoka K, Moridera K, Kishimoto H. Diffuse sclerosing osteomyelitis of the mandible successfully treated with pamidronate: a long-term follow-up report. *Oral Surg Oral Med Oral Pathol Oral Radiol.* 2012;114:e9-e12.
  21. Simm PJ, Biggin A, Zacharin MR, et al. Consensus guidelines on the use of bisphosphonate therapy in children and adolescents. *J Paediatr Child Health.* 2018;54:223-233.
  22. Watters AL, Hansen HJ, Williams T, et al. Intravenous bisphosphonate-related osteonecrosis of the jaw: long-term follow-up of 109 patients. *Oral Surg Oral Med Oral Pathol Oral Radiol.* 2013;115:192-200.
  23. Gimsing P, Carlson K, Turesson I, et al. Effect of pamidronate 30 mg versus 90 mg on physical function in patients with newly diagnosed multiple myeloma (Nordic Myeloma Study Group): a double-blind, randomised controlled trial. *Lancet Oncol.* 2010;11:973-982.

*Reprint requests:*

Jingang An  
Department of Oral and Maxillofacial Surgery  
Peking University School and Hospital of Stomatology  
22 Zhongguancun Nandajie  
Haidian district  
Beijing 100081  
PR  
China.  
anjingang@126.com