



# Stenosis and stenosis-like lesions in the submandibular duct: Detailed clinical and sialendoscopy-based analysis and proposal for a classification

Michael Koch, MD,<sup>a</sup> Johannes Zenk, MD,<sup>b</sup> and Heinrich Iro, MD<sup>a</sup>

**Objective.** The aim of this study was to perform a detailed analysis of submandibular duct stenoses and propose a classification for them.

**Study Design.** This retrospective study covering the period 2001–2019 included 314 patients with 370 submandibular duct stenoses, assessed sialendoscopically for number, grade of narrowing, length, tissue type, and underlying main cause/associated diseases.

**Results.** In the included patients, 58.9% of the stenoses were at the papilla, 89.2% were short, and 61.6% were of high grade. Predominantly inflammatory stenoses (type 1) differed from fibrotic stenoses (type 2). Detailed analysis identified stenosis-like lesions caused by anatomic duct narrowing and/or duct variations (type 3), differing significantly from type 2 stenoses in location, length, and bilaterality (each  $P = .0001$ ) and from type 1 stenoses in location ( $P = .0001$ ). Compared with type 2, type 1 stenoses were bilateral significantly more often and shorter (each  $P = .0001$ ). Frequencies of the main causes of stenosis—atomic narrowness/duct variation and chronic sialadenitis—differed significantly in the different locations ( $P = .0001$ ). There were no significant differences in frequencies of associated diseases/conditions for the different stenosis types.

**Conclusions.** Three types of stenosis/stenosis-like lesions were distinguished. In view of these results and the findings from a review of the literature, the location and type of stenoses were found to be more important parameters, whereas number, grade, and length were less important. The underlying cause may be useful for assessing the prognosis. (Oral Surg Oral Med Oral Pathol Oral Radiol 2020;130:486–495)

Salivary duct stenoses are the second most frequent cause of obstructions in the salivary glands. Around 25% to 30% of such obstructions are located in the submandibular duct system, and 3% to 10% of all obstructions of the submandibular gland (SMG) are caused by stenoses.<sup>1–5</sup> An association between ductal stenosis and sialolithiasis has been noted in greater than 15% of cases.<sup>6,7</sup>

Submandibular duct stenosis is diagnosed by using ultrasonography, magnetic resonance sialography, and conventional sialography,<sup>1,8–12</sup> as well as sialendoscopy, which allows direct visualization of the stenosis.<sup>7,8,12–17</sup> There have been occasional publications describing submandibular stenoses and attempts to develop classifications of them by using radiographic<sup>1,5</sup> and/or sialendoscopic methods.<sup>12,16</sup>

Recent publications have distinguished between inflammatory and fibrotic stenoses in all of the major salivary glands. Eighty-seven percent of stenoses in the SMG show predominantly fibrotic tissue.<sup>6,15,18</sup> Two reports have shown that allergic and autoimmune diseases are the pathologic conditions most frequently associated with stenoses.<sup>6,7</sup> In 1 publication detailing a case series, a dental prosthesis was described as causing a papillary stenosis of the submandibular duct system.<sup>19</sup> To date, however, submandibular duct stenoses have not been precisely

characterized or classified in the same way as has been done for parotid duct stenoses.<sup>16,20</sup>

Therefore, the aim of the present study was to carry out a detailed analysis of stenoses of the SMG in relation to their location, grade, length, number, and tissue quality in the stenotic area, also taking into account possible causative factors and associated conditions. The data are presented here to enhance our understanding of the pathogenesis of these stenoses and to support their clinical management.

## MATERIALS AND METHODS

This retrospective study was carried out in the Department of Otorhinolaryngology, Head and Neck Surgery at the Friedrich Alexander University of Erlangen–Nuremberg, Germany. The study was conducted in accordance with the tenets of the Helsinki Declaration; approval was obtained from the local institutional review board, and all of the study participants provided informed consent.

In total, 314 patients who presented with a suspected diagnosis of obstructive sialopathy of the SMG between January 2001 and December 2019 were evaluated retrospectively. Among them, 138 patients with

## Statement of Clinical Relevance

A detailed analysis and classification of submandibular duct stenoses according to type, location, grade, length, number, side, cause, and associated conditions revealed some significant differences that are potentially relevant to the clinical management of the stenoses.

<sup>a</sup>Department of Otorhinolaryngology, Head and Neck Surgery, Friedrich Alexander University of Erlangen–Nuremberg, Germany.

<sup>b</sup>Department of Otorhinolaryngology, Head and Neck Surgery, University of Augsburg, Germany.

Received for publication Feb 11, 2020; returned for revision Apr 8, 2020; accepted for publication May 25, 2020.

© 2020 Elsevier Inc. All rights reserved.

2212-4403/\$-see front matter

<https://doi.org/10.1016/j.oooo.2020.05.015>

153 stenoses had been included in a previous study on the management of submandibular duct stenoses.<sup>6</sup> In-depth analysis of patient histories and surgical reports was performed, and all relevant patient history data were noted. The number of stenoses (unilateral or bilateral) and their type, localization, length, and grade were assessed clinically by using ultrasonography and sialendoscopy. The type of stenosis in each case was defined by analyzing the tissue in the stenotic area, particularly in relation to the presence of any inflammatory reaction and/or fibrosis, or any other duct variations or specific characteristics. The criteria used in earlier reports by our group were taken into consideration.<sup>6,20</sup> Because of their frequency, papillary stenoses were differentiated from those of the distal duct system, in contrast to an earlier publication.<sup>6</sup>

All of the conditions or diseases associated with the stenoses, as well as all causes with a potential impact on the development of the stenoses, were evaluated. The most obvious or appropriate main cause, among all of the possible causes, was recorded. Chronic sialadenitis was suspected as the cause if inflammation of the duct system (sialodochitis) was observed during sialendoscopy and no other obvious cause was detected. If any other significant cause (e.g., stone, postoperative scar, etc.) was noted at presentation or in the patient's short-term history (approximately 1 year), it was counted as the predominant underlying cause. Signs of sialolithiasis as the main cause included a positive history (e.g., a report of spontaneous washing-out of a stone) and/or location of a stone in front of the stenosis or impacted within it. Stenoses in patients who had undergone surgery of the floor of the mouth, with massive scarring tissue visible, were considered post-traumatic. Although the procedures were performed because of the presence of sialolithiasis, it was the surgery itself, rather than the stone, that was the cause in these stenoses. Inflammatory or fibrotic tissue in a stenosis was considered the main cause if there was no obvious alternative and no other associated conditions were found at presentation. The presence of any autoimmune diseases with a direct impact on the duct system, status post radiotherapy for head and neck carcinoma, or status post radioiodine therapy for thyroid carcinoma or any tumorous lesion, were also included as causes. If neither inflammation or fibrosis was observed but there was anatomic narrowness of the connective tissue in the stenotic duct system—accompanied by anatomic variations of the duct system or anatomic variations causing the stenosis itself—then these changes were regarded as the main cause, and this also had an impact on the classification of stenosis types (see below).

Because the location and type of the stenoses proved to be most important for their management,<sup>6</sup> specific

analysis of this parameter was carried out. In case of long or diffuse stenoses, the location at which the stenosis started was chosen for categorization. The type of stenosis was also stratified relative to number, location, grade, and length.<sup>20</sup>

Statistical analysis was performed by using SPSS Statistics for Windows, version 25.0 (IBM Corporation, Armonk, NY). Data are given as means plus or minus standard error of the mean, median values, and ranges. Differences in the frequencies of categorical variables between 2 different groups were calculated by using the Mann-Whitney U test. Comparisons between several different groups were conducted by using analysis of variance (ANOVA) and least significant difference, Bonferroni, and Kruskal-Wallis tests. In all of the tests, significance was indicated by a 2-sided  $\alpha$  level of 0.05.

## RESULTS

In total, 314 patients were included in the study; 38% (119 of 313) were males and 62% (194 of 313) were females (mean age  $49.57 \pm 0.87$  years; median 50 years; range 12–89 years).

### General data on all stenoses

In total, 370 stenoses were identified. The numbers of stenoses per patient, independently of type, were as follows: 1 in 264 patients (84.07%); 2 in 44 patients (14.01%); and 3 in 6 patients (1.91%); and 26 patients had bilateral stenoses.

A predominantly inflammatory reaction was observed in 42 stenoses (11.35%, type 1). No inflammation, or no significant inflammation, was noted in 328 stenoses (88.64%). A predominantly fibrous reaction was seen in 67.37% of these stenoses ( $n = 221$ ) and in 59.72% of all stenoses, type 2). A significant fibrous reaction was not observed in the remainder of these stenoses; instead, it was anatomic narrowness of the duct and/or anatomic variations in the duct system that were causing the stenosis ( $n = 107$  of 328; 28.91%). After a detailed analysis, it was decided that these represented “functional stenosis,” and they were classified as an additional type (type 3, see below).

In general, the stenoses were most often located at the papilla ( $n = 218$ ; 58.92%); 19.97% ( $n = 48$ ) were located in the distal duct system, 9.72% ( $n = 36$ ) in the middle duct system, and 18.37% ( $n = 68$ ) in the proximal to posthilar duct system. With regard to length, 89.19% ( $n = 330$ ) were short ( $\leq 1$  cm); 6.48% ( $n = 24$ ) were long ( $> 1$  cm to  $< 3$  cm); and 4.32% ( $n = 16$ ) were diffuse stenoses (length  $> 3$  cm). The luminal narrowing present represented grade 1 in 3.24% of the stenoses ( $n = 12$ ); grade 2 in 35.16% ( $n = 130$ ); grade 3 in 45.94% ( $n = 170$ ); and grade 4 in 15.68% of the stenoses ( $n = 58$ ).<sup>20</sup>

**Associated conditions and causes of stenosis**

The associated conditions most often observed that had a possible impact on the inflammation, fibrosis, and/or salivary flow in the patients (n = 314) were allergic disease (n = 86; 27.38%) and asthma (n = 8; 2.55%). Sialolithiasis was present in the same gland or any other gland in 77 patients (24.52%), as indicated by patient history. Various autoimmune diseases were associated with the condition in 5.41% of the patients (n = 17): immunoglobulin G4 (IgG4)—associated disease (n = 4; 1.27%); Sjögren disease (n = 5; 1.59%); Hashimoto disease (n = 3; 0.95%); rheumatoid arthritis/primary chronic polyarthritis (n = 3; 0.95%); psoriasis (n = 2; 0.64%); and temporal arteritis, lipoid proteinosis, or Wegener granulomatosis (1 each; 0.32%). The frequency of the associated conditions did not differ significantly among the different types of stenosis (Table I).

Analysis of the 370 stenoses showed that chronic sialadenitis was most often the main cause, in 32.70% (n = 121) (Figures 1A and 1B). Status post trauma was identified in 13.24% (n = 49). Sialolithiasis was present in 25 (6.75%)—subsequently in 3 (0.81%) and simultaneously in 22 (6.20%)—and fibrosis resulting from a dental prosthesis was observed in 3.24% (n = 12). Inflammatory or fibrotic tissue within a stenosis was the main cause in 10.54% of the stenoses (n = 40; 97.5% were located at the papilla) (Figure 2A). Status post radiotherapy (n = 2; 0.54%) or radioiodine therapy (n = 7; 1.89%), insufficient gland function, minimally invasive carcinoma at the papilla (Figure 2B), and autoimmune disease (lipoid proteinosis) in 1 patient each (0.27%) were rare causes. The main causes, stratified according to the different types of stenosis, are listed in Table II.

Natural narrowness of the duct system, caused by or combined with any anatomic variation of the system,

was the obvious cause in 28.91% of all stenoses (n = 107) (Figures 2C and 2D). These were all clinically noninflammatory and nonfibrotic, and histologic examination of some of them also did not reveal any fibrosis. In view of these differences, these stenoses were classified as type 3 (see sections below). The mean age of these patients was 47 years (median 49 years; range 12–75 years). Of the 107 stenoses, 28.04% (n = 30; 8.10% of all 370 stenoses) were associated with other anomalies or additional stenoses. These included variations in the course of the major sublingual duct (Bartholin duct) and its branching into the submandibular duct (Wharton duct), resulting in stenoses caused by the structure of the connective tissue in 8 patients (7.4%) (see Figure 2D). Stenoses associated with a megaduct (Figures 3A and 3B) or with a pelvis-like hilar duct anomaly (Figures 3C and 3D; for details, see Table III) were also noted; 95.33% of these were short, and 60.74% were low-grade ones, at grades 1–2 (Table IV).

**Types of stenosis**

*Definition of the different types of stenoses based on tissue characteristics.* Distinguishing between the inflammatory and fibrotic types of stenosis has been described as an important parameter for treatment.<sup>6</sup> However, it was not possible to sustain this binary distinction after in-depth analysis of all the stenoses, particularly in relation to the obvious main causes. Anatomic narrowness of the duct and duct variations were only found to be the causes in noninflammatory stenoses. As a result of the observation that these were also not really fibrotic stenoses and were evidently caused by anatomic changes that had stenotic effects,

**Table I.** Distribution of associated diseases/conditions in patients (n = 314) stratified according to the different types of submandibular duct stenosis

Disease/condition	Type		
	Predominantly inflammatory (type 1, n = 36)	Predominantly fibrotic (type 2, n = 190)	Anatomic duct narrowness ± duct variation, noninflammatory and nonfibrotic (type 3, n = 88)
Allergy	26.19% (n = 11)	23.42% (n = 52)	22.42% (n = 24)
Asthma	2.38% (n = 1)	3.60% (n = 8)	2.80% (n = 3)
Autoimmune disease	2.38% (n = 5)	3.60% (n = 8)	3.73% (n = 4)
Status post radiotherapy	—	4.95% (n = 11)	—
CMD/bruxism	7.14% (n = 3)	4.05% (n = 9)	0.93% (n = 1)
Psychiatric disorder	2.38% (n = 1)	4.05% (n = 9)	0.93% (n = 1)
Hypertension	7.14% (n = 3)	13.06% (n = 29)	10.28% (n = 11)
Hypothyroidism	7.14% (n = 3)	7.20% (n = 16)	3.73% (n = 4)
Amyloidosis	2.38% (n = 1)	—	—
Xerostomia	—	—	1.87% (n = 2)
Ranula	2.38% (n = 1)	—	—
Sarcoidosis	—	—	1.87% (n = 2)

CMD, craniomandibular dysfunction.

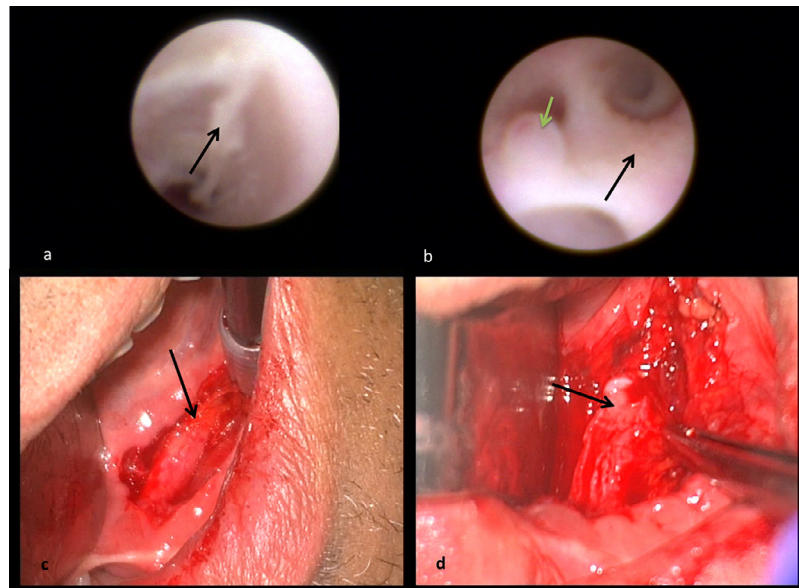


Fig. 1. Inflammatory stenosis of the papilla/prepapilla (not shown) and chronic sialadenitis with sialodochitis (as the main cause). **A, B**, First case. Thickened duct wall with discharge and plaques (**A**, black arrow), cobblestone-like mucosa (**B**, black arrow), and a polyp-like lesion at the duct wall (**B**, green arrow) in a patient with immunoglobulin G4 (IgG4)-associated disease (as an associated condition). **C, D**, Second case. Sialodochitis with a thickened duct wall (black arrow, **C**) and fibrotic stenosis at the proximal duct after transoral duct surgery (black arrow, **D**).

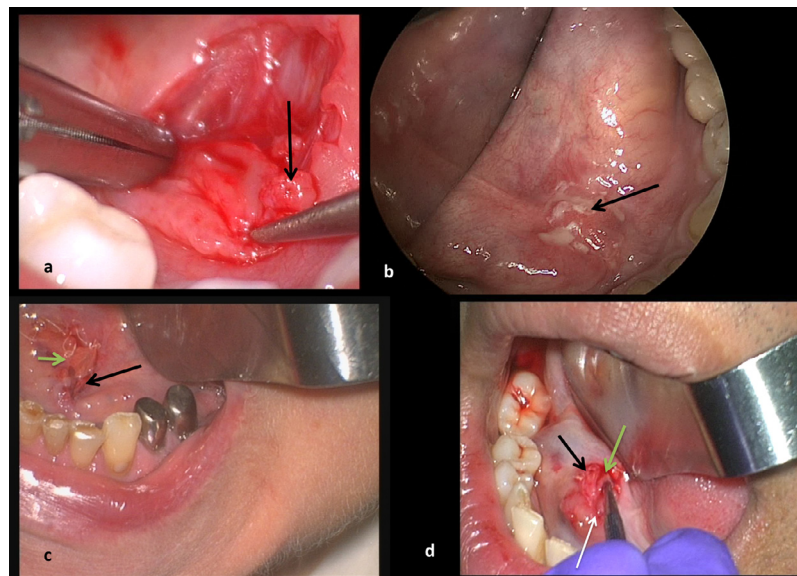


Fig. 2. Papillary stenoses of various causes. **A**, Papillary fibrosis (arrow) with no further pathology after papillotomy. **B**, Inflammation, edema, and fibrinoid changes (arrow) on the mucosa in carcinoma in situ. **C**, Anatomic narrowness with resulting stenosis (black arrow) and significant widening of the distal duct (green arrow). **D**, Common branching of the Bartholin duct (black arrow) and the Wharton duct (green arrow), with a resulting stenosis (white arrow).

they were classified as a separate type 3 (“stenosis-like lesions”) and analyzed separately.

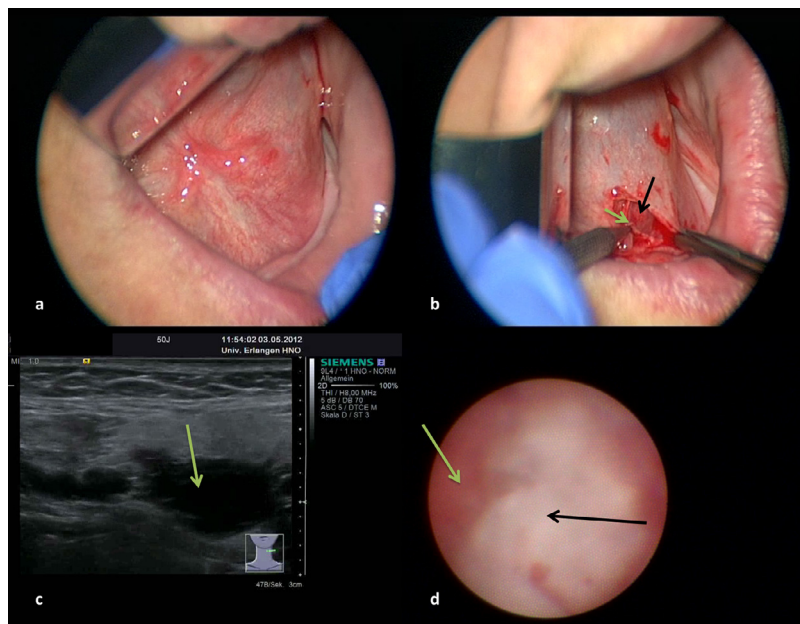
*Distribution of location, laterality, length, grade and number in the different stenoses.* Significant additional differences were noted after comparison of the groups.

In comparison with types 1 and 2, type 3 stenoses showed significant differences with regard to location ( $P = .001$ ). In comparison with type 1, type 3 stenoses were bilateral significantly more often ( $P = .0001$ ), and in comparison with type 2 they were shorter significantly more often ( $P = .0001$ ) and of low grade

**Table II.** Distribution of obvious main causes in the different types of submandibular duct stenosis (n = 370)

Main factor or cause	Type			ANOVA (type vs cause)
	Predominantly inflammatory (type 1, n = 36)	Predominantly fibrotic (type 2, n = 190)	Anatomic duct narrowness ± duct variation, noninflammatory and nonfibrotic (type 3, n = 88)	
Chronic sialadenitis	71.42% (n = 31)	40.72% (n = 90)	—	0.0001
Anatomic cause/variation	—	—	32.52% (n = 107)	0.0001
Inflammation/fibrosis with no associated main cause at presentation	9.52% (n = 4)	16.29% (n = 36)	—	n.s.
— Papilla	9.52% (n = 4)	15.84% (n = 35)	—	
— Other location	—	0.45% (n = 1)	—	
Trauma/postoperative	4.76% (n = 2)	21.26% (n = 47)	—	n.s.
Dental prosthesis	4.76% (n = 2)	4.52% (n = 10)	—	n.s.
Foreign body	2.38% (n = 1)	0.45% (n = 1)	—	n.s.
Tumor	0.32% (n = 1)	—	—	—
Sialolithiasis	2.38% (n = 1)	10.86% (n = 24)	—	n.s.
Autoimmune disease	—	0.45% (n = 1)	—	—
Status post radiotherapy	—	4.98% (n = 11)	—	—
Gland insufficiency	—	0.45% (n = 1)	—	—
Total	100% (n = 42)	100% (n = 221)	100% (n = 107)	—

ANOVA, analysis of variance; n.s., not significant.



**Fig. 3.** Anatomic narrowness of the papilla, with associated duct variations. **A, B, First case.** The papilla before papillotomy (**A**) and after (**B**). A stenotic area (green arrow, **B**) and megaduct (black arrow, **B**) are seen. **C, D, Second case.** A hilar pelvis-like anomaly of the duct system is visible on ultrasonography (green arrow, **C**) and sialendoscopy (green arrow, **D**).

( $P = .008$ ; see [Table IV](#)). Type 1 stenoses were bilateral ( $P = .0001$ ) and shorter ( $P = .0001$ ) significantly more often in comparison with type 2 stenoses (see [Table IV](#)). Only 2 patients with more than 1 stenosis had different types of stenosis (the first had type 1 in the distal duct and type 3 in the middle duct, unilateral; the second had type 1 in the distal duct and type 2 in the hilum, bilateral). When patients with more than one

stenosis were analyzed depending on the type, 37 were found to have more than one additional stenosis (31 patients with 2 stenoses; 6 patients with 3 stenoses). Of these, 23 had bilateral stenoses (all with 2 stenoses) and 3 had bilateral stenoses and an additional stenosis on one side (all with 3 stenoses), with no significant differences observable among the different types (see [Table IV](#)).

**Table III.** Detailed data on submandibular duct stenosis caused by anatomic narrowness with or without duct variations (n = 107)

<i>Specific characteristics, variations</i>	<i>Anatomic duct narrowness ± duct variation, noninflammatory and nonfibrotic (type 3) 107 stenoses/88 patients</i>	<i>Location</i>
All (n = 107)	100% (n = 107)	Papilla: 85.98% (n = 92) Distal: 5.61% (n = 6) Middle: 4.67% (n = 5) Hilum: 2.80% (n = 4)
Anatomic duct narrowness without inflammation or fibrosis and without combination with any other duct anomalies (n = 77)	71.96% (n = 77)	Papilla: 90.90% (n = 70) Distal: 2.59% (n = 2) Middle: 5.19% (n = 4) Hilum: 1.29% (n = 1)
Anatomic narrowness of the papilla in combination with any stenosis in another location (n = 3 patients, 6 stenoses)	5.60% (n = 6)	Papilla + hilum: 100% (n = 6)
Length of anatomic narrowing of the duct system > 1 cm, originating at the papilla	4.62% (n = 5)	Papilla: 100% (n = 5)*
Anatomic narrowness caused by variations in the course and/or branching of Wharton duct and Bartholin duct	100% (n = 8)	Papilla: 87.5% (n = 7) Distal: 12.5% (n = 1)
Combination of anatomic duct narrowness and mega-duct (n = 4)	100% (n = 4)	Papilla: 50% (n = 2) Distal: 25% (n = 1)† Middle: 25% (n = 1)†
Combination of anatomic duct narrowness with duct kinking (n = 5)	100% (n = 5)	Papilla: 80% (n = 4) Distal: 20% (n = 1)*
Combination of anatomic duct narrowness and duct webs (n = 1)	0.93% (n = 1)	Distal: 100% (n = 1)
Combination of anatomic duct narrowness with pelvic-like duct variation in the hilum (n = 1)	0.93% (n = 1)	Papilla: 100% (n = 1)
Total no. of stenoses (n = 107)	100% (n = 107)	

\*One case with additional kinking in the middle duct.

†Two stenoses in one ductal system.

*Interrelation between main causes, associated diseases, and the different types of stenoses.* There was no statistically significant association between other associated diseases or conditions and the different types of stenoses (see [Tables I and II](#)). Some rare causes, such as status post radiotherapy; autoimmune disease (both with a predominantly fibrotic type); or tumor (with a predominantly inflammatory type), were observed in only one type. If causes were noted for more than one type, no significant differences were observed except for chronic sialadenitis, which was found to be significantly more often the cause in type 1 stenoses in comparison with type 2 ( $P = .0001$ ) and was not present at all in type 3 (see [Table II](#)).

**Analysis in consideration of the location of the stenosis**

When the stenoses were stratified relative to location, no significant differences were observed in relation to type, length, or grade ([Table V](#)). Some rare or very rare causes were observed only in distinct regions (e.g., dental prosthesis: papilla; posttraumatic stenosis: distal duct/papilla), whereas some others were found in every region (e.g., chronic sialadenitis, anatomic narrowness/

variations, sialolithiasis; [Table VI](#)). The frequency of chronic sialadenitis, which was the main cause, increased significantly from the papilla to the hilum/post hilar duct system ( $P = .0001$ ). The frequency of anatomic narrowness and/or variations decreased significantly from the peripheral to the central duct system ( $P = .0001$ ; see [Table VI](#)).

A detailed analysis of papillary stenoses (n = 218) was carried out in view of their frequency and variable causes. Bilateral stenoses were present in 13 patients, all of which were located at the papilla, making up 11.93% of all papilla stenosis (26 of 218; see [Tables IV to VI](#)). The cause most often observed was anatomic narrowness and/or variation (92 of 218 [42.20%]). Anatomic narrowness of the papilla without significant inflammation or fibrosis was noted in 32.11% of stenoses (70 of 218; see [Figure 2C](#)), and an association with other anomalies or additional stenoses in 11.46% (25 of 218; see [Figure 2D](#) and [Table III](#)). By contrast, pronounced inflammation with a markedly thickened/swollen, reddish papilla, or with whitish induration and fibrosis of the papilla, was observed in 17.89% of stenoses (39 of 218; see [Figure 2A](#)). No other obvious cause or associated disease/condition and, in particular,

**Table IV.** Location, grade, length, side, and numbers of stenosis types in patients (n = 314) with submandibular duct stenoses (n = 370) and results after comparison of the frequencies of the different parameters across the different groups using the Mann-Whitney U test (MWU)

Parameters	Predominantly inflammatory (type 1) 42 stenoses/36 patients	Predominantly fibrotic (type 2) 221 stenoses/190 patients	Anatomic duct narrowness ± duct variation, noninflammatory and nonfibrotic (type 3) 107 stenoses/88 patients	MWU (types 1–3, parameter)
<b>Location</b> (No. of stenoses)				
Papilla	52.38% (n = 22)	47.05% (n = 104)	85.98% (n = 92)	1 versus 2: n.s.
Distal	30.95% (n = 13)	13.12% (n = 29)	5.61% (n = 6)	1 versus 3: 0.0001
Middle/proximal	7.14% (n = 3)	12.67% (n = 28)	4.67% (n = 5)	2 versus 3: 0.0001
Hilar/posthilar	9.52% (n = 4)	27.14% (n = 60)	3.73% (n = 4)	
<b>Grade</b> (No. of stenoses)				
I	2.38% (n = 1)	1.81% (n = 4)	6.54% (n = 7)	1 versus 2: n.s.
II	47.62% (n = 20)	23.52% (n = 52)	54.20% (n = 58)	1 versus 3: n.s.
III	42.86% (n = 18)	50.22% (n = 111)	38.31% (n = 41)	2 versus 3: 0.008
IV	7.14% (n = 3)	24.43% (n = 54)	0.93% (n = 1)	
<b>Length</b> (No. of stenoses)				
< 1 cm	92.86% (n = 39)	85.06% (n = 188)	96.26% (n = 103)	1 versus 2: 0.0001
> 1 to < 3 cm	4.76% (n = 2)	9.04% (n = 20)	1.87% (n = 2)	1 versus 3: n.s.
> 3 cm	2.38% (n = 1)	5.88% (n = 13)	1.87% (n = 2)	2 versus 3: 0.0001
<b>Bilateral</b> (No. of stenoses)				
	28.57% (n = 12)	6.33% (n = 14)	22.43% (n = 26)	1 versus 2: 0.0001 1 versus 3: n.s. 2 versus 3: 0.0001
<b>Total stenoses (n)</b>	<b>n = 42</b>	<b>n = 221</b>	<b>n = 107</b>	
<b>No. of stenoses</b> (No. of patients)*				
n = 1	83.33% (n = 30)	87.36% (n = 166)	79.54% (n = 70)	1 versus 2: n.s.
n = 2	16.67% (n = 6)	4.73% (n = 9)	18.18% (n = 16)	1 versus 3: n.s.
n = 3	0% (n = 0)	2.63% (n = 5)	1.14% (n = 1)	2 versus 3: n.s.
Total patients (n)	n = 36	n = 190	n = 88	

n.s., not significant.

\*Stratified according to the same type of stenosis (unilateral and bilateral).

**Table V.** Type, length, and grade of submandibular duct stenoses (n = 370), stratified relative to location

Location	Type (1, 2, 3) (No. of stenoses)	Length (No. of stenoses)	Grade (I–IV) (No. of stenoses)
Papilla (n = 218)	1: 10.13% (n = 22) 2: 47.70% (n = 104) 3: 42.20% (n = 92)	< 1 cm: 89.44% (n = 195) > 1 to < 3 cm: 4.61% (n = 10) > 3 cm: 5.96% (n = 13)	I: 3.21% (n = 7) II: 39.90% (n = 87) III: 38.99% (n = 85) IV: 17.89% (n = 39)
Distal (n = 48)	1: 27.08% (n = 13) 2: 60.41% (n = 29) 3: 12.50% (n = 6)	< 1 cm: 83.33% (n = 40) > 1 to < 3 cm: 10.42% (n = 5) > 3 cm: 6.25% (n = 3)	I: 2.08% (n = 1) II: 22.92% (n = 11) III: 62.50% (n = 30) IV: 12.50% (n = 6)
Middle to proximal (n = 36)	1: 8.33% (n = 3) 2: 77.78% (n = 28) 3: 13.89% (n = 5)	< 1 cm: 80.56% (n = 29) > 1 to < 3 cm: 19.44% (n = 7) > 3 cm: – (n = 0)	I: 5.55% (n = 2) II: 47.22% (n = 17) III: 25.0% (n = 9) IV: 22.22% (n = 8)
Hilar/posthilar (n = 68)	1: 5.89% (n = 4) 2: 94.11% (n = 60) 3: 5.88% (n = 4)	< 1 cm: 97.05% (n = 66) > 1 to < 3 cm: 2.95% (n = 2) > 3 cm: – (n = 0)	I: 2.95% (n = 2) II: 22.05% (n = 15) III: 67.64% (n = 46) IV: 7.35% (n = 5)

no history or signs of sialolithiasis or inflammation of the more proximal duct, were recognizable in these patients, most of whom were females (64.1%) and of younger age (mean age 51.9 ± 2.3 years; median 50

years; range 22–80 years). Chronic sialadenitis (31 of 218 [14.22%]; see Figure 1) was noted less often as the main cause (see discussion above). Trauma (30 of 218 [13.76%]) and scarring, with or without inflammation

**Table VI.** Frequency of the obvious main causes relative to location in submandibular duct stenoses (n = 370)

Cause	Location					Mann-Whitney U (location vs cause)
	Papilla (n = 218)	Distal (n = 48)	Middle (n = 36)	Proximal (n = 68)	All (n = 370)	
Chronic sialadenitis	14.22% (n = 31)	47.91% (n = 23)	58.33% (n = 21)	67.64% (n = 46)	32.70% (n = 121)	0.0001
Anatomic cause/ variation	42.20% (n = 92)	12.20% (n = 6)	13.89% (n = 5)	5.88% (n = 4)	28.91% (n = 107)	0.0001
Inflammation/fibrosis without associated main cause at presentation					10.81% (n = 40)	–
– Papilla	17.88% (n = 39)	–	–	–		
– Other location	–	2.08% (n = 1)	–	–		
Trauma/postoperative	13.76% (n = 30)	29.17% (n = 14)	11.11% (n = 4)	1.47% (n = 1)	13.24% (n = 49)	n.s.
Dental prosthesis	5.50% (n = 12)	–	–	–	3.24% (n = 12)	–
Foreign body	–	–	–	2.94% (n = 2)	0.54% (n = 2)	–
Tumor	0.46% (n = 1)	–	–	–	0.27% (n = 1)	–
Sialolithiasis	4.13% (n = 9)	4.17% (n = 2)	13.89% (n = 5)	13.23% (n = 9)	6.75% (n = 25)	n.s.
Autoimmune disease	–	2.08% (n = 1)	–	–	0.27% (n = 1)	–
Status post radiotherapy	1.83% (n = 4)	2.08% (n = 1)	2.78% (n = 1)	7.35% (n = 5)	2.97% (n = 11)	n.s.
Gland insufficiency	–	–	–	1.47% (n = 1)	0.27% (n = 1)	–
<b>Total</b>	<b>100% (n = 218)</b>	<b>100% (n = 48)</b>	<b>100% (n = 36)</b>	<b>100% (n = 68)</b>	<b>100% (n = 370)</b>	–

n.s., not significant.

resulting from visible contact with a dental prosthesis (12 of 218 [5.50%]), were additional important causes. The latter was only seen in older patients (mean age 74.42 ± 2.9 years; median 74 years; range 56–89 years). Surprisingly, sialolithiasis was the obvious main cause in only 4.12% (9 of 218; see Table VI).

**DISCUSSION**

This analysis of submandibular duct stenoses confirms the existence of the inflammatory and fibrotic types of stenosis.<sup>6</sup> In addition to these, a nonfibrotic, noninflammatory type with real stenotic effects was also identified, representing 28.97% of all stenoses. These stenosis-like lesions showed sometimes significant differences from the others in relation to bilaterality, grade, length, and location (see Tables I through IV). Nearly 60% of these stenotic lesions (classified as type 3) were located at the papilla, emphasizing the importance of location as a parameter. Chronic sialadenitis was most often noted as the obvious main cause, and its frequency increased significantly from the papilla to the hilum (P = .0001). Conversely, when anatomic narrowness and/or variation was the main cause, the frequency significantly decreased from the papilla to the hilum (P = .0001).

To the best of our knowledge, only a few publications have analyzed submandibular duct stenoses,<sup>6,7,21</sup> with some reports including rough data on the epidemiology or frequency of stenoses in the major salivary glands.<sup>1-5</sup> The rest of the literature mainly deals with therapy,<sup>6,7,13,15,18,21</sup> although a few studies conducted by

our own research group have considered the differences between fibrotic and inflammatory stenoses.<sup>6,15,18,21</sup> However, a more detailed analysis or classification of the type presented here has not previously been available in the literature.

It has been shown in earlier studies<sup>6,15,18</sup> that in addition to type, the location of submandibular stenoses, in particular, had the greatest impact on their treatment. In contrast to our recent reports, the duct system is now stratified into 4 locations instead of 3.<sup>6,15,18,21</sup> This reflects the fact that the papilla was affected in nearly 60% of stenoses analyzed in this study. All stenoses in this area are accessible for transoral duct surgery (TDS). A previous study by our group found that TDS was the most important surgical technique because of the accessibility of the duct system as far as the proximal duct (60% of all stenoses). However, it was also clear that the more centrally the stenosis was located (e.g., from proximal to post hilar), the more important sialendoscopy was. Twenty-seven percent of all stenoses that were located in the hilar to intraparenchymal areas were successfully treated with sialendoscopy.<sup>6</sup>

In contrast to the parameters mentioned above, the number, grade, and length of stenoses appear to be of minor importance. Interestingly, no significant associations between the parameters “location” and “main cause” were observed. TDS can be carried out in stenoses of any number, grade or length, but not in any location. In long stenoses that do not extend beyond the proximal duct system, TDS may be the only promising



treatment modality. In diffuse stenosis, conservative therapy appears to be the only reasonable modality for gland-preserving treatment. The grade and length of any stenosis not only may develop as a result of inadequate glandular function but can also cause it.<sup>6,20</sup>

The type of stenosis has a major impact on the treatment, but it also needs to be evaluated in context with the location. If a stenosis is predominantly inflammatory, then conservative therapy (e.g., irrigation with cortisone) can be carried out independently of the location. TDS or sialendoscopy can generally be used in all types of stenosis, unless the location is unfavorable. This is particularly the case for stenoses caused by anatomic narrowness and/or variation because according to the data presented here, 95.4% of these were short and 97.2% of them were located in the duct system, which is well accessible for TDS, and they were associated with good glandular function.

Taking the underlying cause into account helped better define differences among stenoses and provided information about the expected prognosis before and after treatment. The various causes observed (see Table II) include expected causes (e.g., sialolithiasis at 4.2% and chronic sialadenitis at 14.48%) and also unexpected causes, such

as isolated inflammation/fibrosis at the papilla and the effects of dental prostheses.<sup>19</sup> Accompanying autoimmune disease or status post radiotherapy may indicate a poorer prognosis. Anatomic narrowness in the duct without fibrosis and/or other ductal variations (e.g., the relationship between the Bartholin duct and the Wharton duct, presence of webs or kinking, or megaduct (see Table III) were the cause in 28.84% of all duct stenoses, representing a spectrum of stenosis-like lesions that have not previously been described in the literature. The stenotic effect was not explainable by inflammation or fibrosis but, rather, by specific anatomic features involving the connective tissue and architecture of the duct system that evidently led to (recurrent) duct obstruction. Lack of an inflammatory or fibrotic reaction and observation of a clear fluid salivary flow may also help differentiate these stenoses from the other types.

The frequency of stenoses decreased significantly from the papilla to the hilum ( $P = .0001$ ; see Tables III and IV). If the papilla was involved, dilation was, at the least, very difficult, if not impossible, and it was only possible to insert a sialendoscope after papillotomy. Surgical treatment (e.g., papillotomy) in the corresponding region improved symptoms, and no further

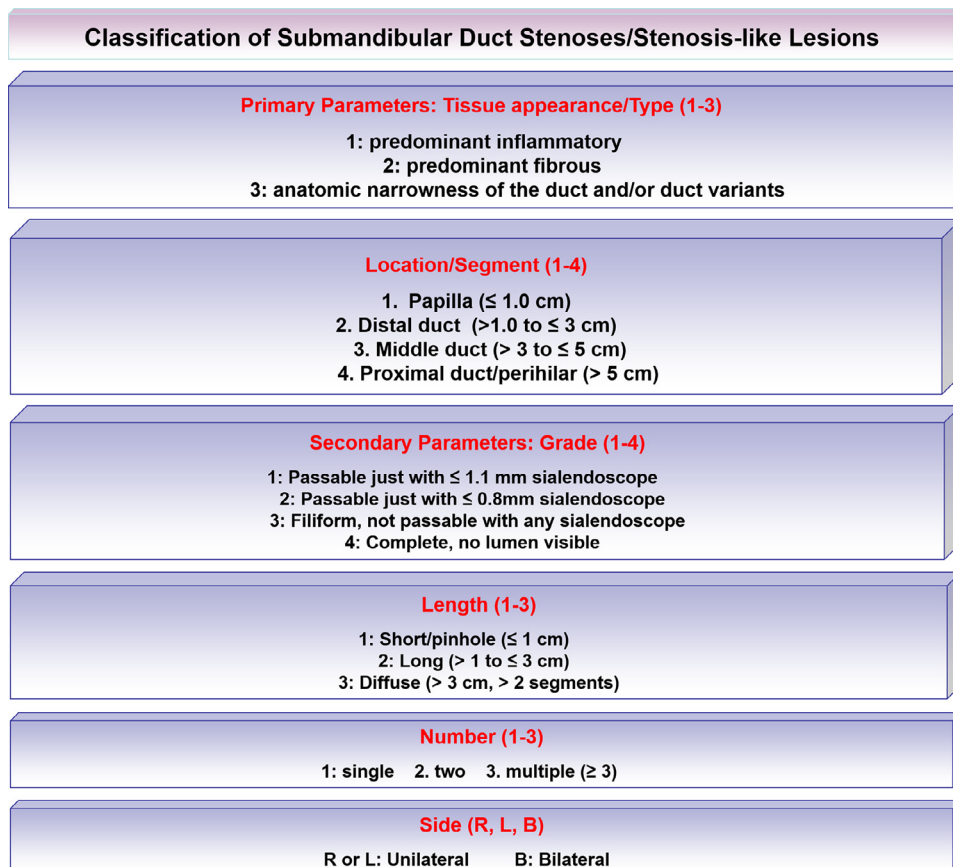

Fig. 4. Classification of submandibular stenoses based on parameters of primary importance (type, location) and secondary importance (grade, length, number, side).

pathology in the residual duct system was observed. Interestingly, this type of stenosis was short in 95.33%, with a lower grade in 61.74%, and it was bilateral significantly more often in comparison with the other types ( $P = .0001$ ). In view of its noninflammatory and nonfibrotic nature, this type of stenosis does not fit into the published definitions of stenoses.<sup>6,15,16,18</sup> It definitely had a stenotic effect, however, and can be regarded as a stenotic lesion or at least a stenosis-like lesion. A proposal for a classification including and weighing up all of the parameters investigated is presented in Figure 4.

## CONCLUSIONS

For any classification with a possible impact on the management, the location and type of stenoses should be regarded as primary classification parameters. A detailed analysis of submandibular stenosis showed that in addition to a predominantly inflammatory and a predominantly fibrotic type of lesion, a new noninflammatory and nonfibrotic stenosis or stenosis-like lesion can be distinguished. The number, grade, length, and cause of stenoses are secondary parameters (see Figure 4). The underlying cause is important for the definition of a new type of stenosis and is also useful for obtaining information regarding the expected prognosis.

## REFERENCES

1. Ngu RK, Brown JE, Whaites EJ, Drage NA, Ng SY, Makdissi J. Salivary duct strictures: nature and incidence in benign salivary obstruction. *Dentomaxillofac Radiol*. 2007;36:63-67.
2. Koch M, Zenk J, Iro H. Diagnostic and interventional sialoscopy in obstructive diseases of the salivary glands. *HNO*. 2008;56:139-144. [in German].
3. Yu C, Yang C, Zheng L, Wu D. Endoscopic observation and strategic management of obstructive submandibular sialadenitis. *J Oral Maxillofac Surg*. 2010;68:1770-1775.
4. Chuangqi Y, Chi Y, Lingyan Z. Sialendoscopic findings in patients with obstructive sialadenitis: long-term experience. *Br J Oral Maxillofac Surg*. 2013;51:337-341.
5. Lee LIT, Pawar RR, Whitley S, Makdissi J. Incidence of different causes of benign obstruction of the salivary glands: retrospective analysis of 493 cases using fluoroscopy and digital subtraction sialography. *Br J Oral Maxillofac Surg*. 2015;53:54-57.
6. Koch M, Iro H, Künzel J, Psychogios G, Bozzato A, Zenk J. Diagnosis and gland-preserving minimally invasive therapy for Wharton's duct stenoses. *Laryngoscope*. 2012;122:552-558.
7. Kopeć T, Szyfter W, Wierzbicka M, Nealis J. Stenoses of the salivary ducts—sialendoscopy based diagnosis and treatment. *Br J Oral Maxillofac Surg*. 2013;51:e174-e177.
8. Yuasa K, Nakhyama E, Ban S, et al. Submandibular gland duct endoscopy. Diagnostic value for salivary duct disorders in comparison to conventional radiography, sialography, and ultrasonography. *Oral Surg Oral Med Oral Pathol Oral Radiol Endod*. 1997;84:578-581.
9. Capaccio P, Cuccarini V, Ottaviani F, et al. Comparative ultrasonographic, magnetic resonance sialographic, and videoendoscopic assessment of salivary duct disorders. *Ann Otol Rhinol Laryngol*. 2008;117:245-252.
10. Zenk J, Iro H, Klintworth N, Lell M. Diagnostic imaging in sialadenitis. *Oral Maxillofac Surg Clin North Am*. 2009;21:275-292.
11. Karaca Erdoğan N, Altay C, Ozenler N, et al. Magnetic resonance sialography findings of submandibular ducts imaging. *Biomed Res Int*. 2013;2013:417052.
12. Choi J-S, Choi Y-G, Kim Y-M, Lim J-Y. Clinical outcomes and prognostic factors of sialendoscopy in salivary duct stenosis. *Laryngoscope*. 2018;128:878-884.
13. Nahlieli O, Shacham R, Yoffe B, Eliav E. Diagnosis and treatment of strictures and kinks in salivary gland ducts. *J Oral Maxillofac Surg*. 2001;59:484-490. discussion, 490-492.
14. Koch M, Zenk J, Bozzato A, Bumm K, Iro H. Sialoscopy in cases of unclear swelling of the major salivary glands. *Otolaryngol Head Neck Surg*. 2005;133:863-868.
15. Koch M, Iro H, Zenk J. Role of sialoscopy in the treatment of Stensen's duct strictures. *Ann Otol Rhinol Laryngol*. 2008;117:271-278.
16. Marchal F, Chossegros C, Faure F, et al. Salivary stones and stenosis. A comprehensive classification. *Rev Stomatol Chir Maxillofac*. 2008;109:233-236.
17. Vashishta R, Gillespie MB. Salivary endoscopy for idiopathic chronic sialadenitis. *Laryngoscope*. 2013;123:3016-3020.
18. Koch M, Iro H, Zenk J. Sialendoscopy-based diagnosis and classification of parotid duct stenoses. *Laryngoscope*. 2009;119:1696-1703.
19. Schapher M, Goncalves M, Mantsopoulos K, Iro H, Koch M. Papillary stenosis of the submandibular gland caused by dental prostheses. *Oral Surg Oral Med Oral Pathol Oral Radiol*. 2020; S2212-4403:31537-31538.
20. Koch M, Iro H. Extended and treatment-oriented classification of parotid duct stenosis. *Laryngoscope*. 2017;127:366-371.
21. Koch M, Iro H. Salivary duct stenosis: diagnosis and treatment. *Acta Otorhinolaryngol Ital*. 2017;37:132-141.

### Reprint requests:

Michael Koch  
Department of Otorhinolaryngology  
Head and Neck Surgery  
Friedrich Alexander University of Erlangen–Nuremberg  
Waldstrasse 1  
D-91054 Erlangen  
Germany.  
Michael.Koch@uk-erlangen.de