



Improved identification of unstable acromioclavicular joint injuries in a clinical population using the acromial center line to dorsal clavicle radiographic measurement

Orestis Karargyris, MD^a, Richard J. Murphy, MBChB, MA, DPhil, FRCS(Orth)^{b,*}, Antonio Arenas, MD^a, Lilianna Bolliger, MSc, ETH^a, Matthias A. Zumstein, MD^{b,c,*}

^a*Inselspital, Department of Orthopaedic Surgery and Traumatology, Shoulder, Elbow and Orthopaedic Sports Medicine, Bern University Hospital, University of Bern, Bern, Switzerland*

^b*Shoulder, Elbow and Orthopaedic Sports Medicine, Orthopaedics Sonnenhof, Bern, Switzerland*

^c*Stiftung Lindenhof I Campus SLB, Swiss Institute for Translational and Entrepreneurial Medicine, Bern, Switzerland*

Background: Accurate classification and subsequent management of acromioclavicular (AC) joint injuries remains a contentious topic. The updated Rockwood classification acknowledges “stable IIIA” and “unstable IIIB” injuries, a watershed accepted by ISAKOS and important in guiding clinical management. Traditionally, the coracoclavicular distance is used to classify these injuries, despite well-documented limitations. This study aimed to evaluate displacement in AC joint injuries by measuring both coracoclavicular (CC) distance and the newly proposed acromial center line to dorsal clavicle (AC-DC) distance, in a cohort of patients, and correlate the results between the 2 measurements and relationship to Rockwood grade.

Materials and Methods: Ninety consecutive cases of AC joint injury were evaluated radiographically for Rockwood classification, CC distance on anteroposterior radiographs, and AC-DC distance on Alexander view radiographs. Inter- and intraobserver reliability for each measurement was calculated as well as correlation between the 2 measurement types and the degree to which each measurement accurately represented the Rockwood classification.

Results: Although both CC and AC-DC measurements showed very high inter- and intraobserver reliability, the CC distance systematically underestimated the degree of AC joint displacement when compared with the AC-DC measurement as the severity of injury increased, particularly in the presence of posterior horizontal displacement such as that seen in Rockwood IV injuries.

Conclusion: The AC-DC measurement and use of the Alexander view provides the clinician with a more realistic appreciation of true AC joint displacement, especially in defining watershed cases (ie, IIIA/IIIB/IV) and may better inform the decision-making process regarding management options and recommendations.

Level of evidence: Basic Science Study; Development of Classification System

© 2019 The Author(s). This is an open access article under the CC BY-NC-ND license (<http://creativecommons.org/licenses/by-nc-nd/4.0/>).

Keywords: Acromioclavicular joint; Rockwood; CC distance; radiographic measurement; shoulder; AC joint; injury

Institutional review board approval was received July 14, 2015, from Kantonale Ethikkommission Bern (no. 154/14).

*Reprint requests: Matthias A. Zumstein, MD, or Richard J. Murphy, MBChB, MA, DPhil, FRCS(Orth), Shoulder, Elbow and Orthopaedic Sports Medicine, Orthopaedics Sonnenhof, 3006 Bern, Switzerland.

E-mail addresses: matthiaszumstein@sonnenhof.ch (M.A. Zumstein); richardjamesmurphy@icloud.com (R.J. Murphy).

Treatment of the dislocated, unstable acromioclavicular (AC) joint is still considered a topic of debate, particularly in Rockwood type III injuries with disruption of both the coracoclavicular (CC) and acromioclavicular ligaments. The commonly used Rockwood classification published in 1984 relies on plain radiographs to evaluate the CC distance relative to the unaffected side. The ISAKOS consensus group has recently further expanded this classification by suggesting the addition of subgroups IIIA (stable) and IIIB (unstable) in an effort to provide effective guidance in the management of this group of injuries.² The rationale for this subclassification is largely clinical, with the unstable type IIIB lesions presenting with continuous pain, rotator cuff weakness, diminished abduction range of motion, and scapular dyskinesis. However, special radiographic views might be used to provide the necessary, objective information regarding horizontal translation. In lateral cross-body stress views (Alexander view) the clavicle can be seen overriding the acromion in cases of unstable type IIIB injuries as well as more severe types IV and V. Thus, horizontal displacement may be underappreciated when simply relying on anteroposterior (AP) views. This in turn could affect injury classification and potentially lead to poor treatment decisions.

The majority of radiographic parameters assessing horizontal instability that have been described in the literature are semi-quantitative or subject to inaccuracies,^{4,11,17} while assessment of vertical displacement may be affected by projection variability.¹³ In a previously published in vitro study, which was based on sawbone models, a new set of radiographic parameters were described that are relatively independent of projection variability. The study demonstrated excellent validity for 2 new measurements: the acromial center line to dorsal clavicle (AC-DC) and glenoid center line to posterior clavicle (GC-PC) distances, measured on lateral Alexander shoulder views. These 2 radiographic parameters were proposed for assessing vertical and horizontal displacement, respectively²⁰; however, the analysis did not consider the accuracy of these measurements in the assessment of total displacement distance of the AC joint and whether these measurements might evaluate a composite of both horizontal and vertical displacement. In addition, this was a laboratory study performed using sawbone models, and the physiological variation in bony anatomy was, therefore, not taken into account.

The CC distance has long been used as a measure of AC joint instability, although it has been questioned regularly as a useful tool because of its lack of tolerance for projectional variation. The AC-DC measurement was originally designed to evaluate superior displacement of the distal clavicle from a lateral view and has been shown to tolerate projectional variation well in terms of effect on measurement accuracy.²⁰

The aim of the current study was to evaluate AC joint displacement at the time of presentation in a series of clinical cases by comparison of both the CC distance and

the newly proposed AC-DC distance in addition to their relationship with Rockwood grade.

Materials and methods

In this study of diagnostic test evaluation, we retrospectively reviewed all patients treated for AC joint injuries in our institution from 2014-2017. All adult patients with a documented AC joint injury and a complete series of anterior Zanca stress views and bilateral Alexander shoulder views on admission were included in the study. Polytrauma patients, patients with a previous history of contralateral AC joint injury, and patients with incomplete and/or poor-quality admission radiographs were excluded from the study. The local Ethics Committee approved the protocol (154/14), and the study was carried out in accordance with the Guidelines for Good Clinical Practice.

Rockwood classification was performed in accordance with the ISAKOS description in a qualitative manner by reviewing the Zanca and Alexander views. Type II injuries were identified by 50% superior displacement of the distal clavicle on Zanca stress view. Type III injuries were identified by 100% superior displacement of the distal clavicle, whereas type IV injuries were identified by additional posterior displacement of the distal clavicle observed on the cross-body adduction Alexander view. Type V injuries were graded as an exaggeration of type III injuries with 100%-300% superior displacement of the distal clavicle. The radiographs were independently evaluated by 2 board-certified orthopedic surgeons, and final decision for classification was based on agreement or consensus.

Lateral shoulder Alexander views were obtained with the patient standing as for a shoulder Y-view at a 45° angle to the detector, although the injured arm cross-adducted in front of the chest with the hand resting in the contralateral axilla.^{1,19} The following measurements were performed bilaterally on admission radiographs: CC distance in AP Zanca view and AC-DC in lateral Alexander views (Fig. 1).²⁰ The CC distance was measured from the top of the coracoid to the undersurface of the distal clavicle on AP Zanca views, whereas the AC-DC was measured from the middle acromial axis to the dorsal clavicle surface on the lateral Alexander views. All measurements were obtained using picture archiving and communication software (PACS) and presented in millimeters as the difference between the unaffected and injured shoulders.

The measurements were taken by 2 senior orthopedic surgeons (O.K., M.Z.) to assess interobserver reliability. Each examiner was blinded and independent to the other measurements. One examiner (O.K.) assessed the measurements twice at an interval of 6 weeks to determine intraobserver reliability.

Inter- and intraobserver reliability was determined by using a 2-way random intraclass correlation coefficient (ICC) assuming single measurement and absolute agreement, that is, ICC (2, 1), and presented with a 95% confidence interval. Interpretation followed the Munro classification (low: 0.26-0.49; moderate: 0.5-0.69; high: 0.7-0.89; very high: 0.9-1.0).⁸ Correlation analysis was performed using a linear Pearson correlation coefficient. The degree of correlation defined less than 0.2 as poor, 0.2-0.4 as low, 0.4-0.6 as moderate, 0.6-0.8 as good, and greater than 0.8 as excellent. Agreement between the 2 measurements was assessed with Bland-Altman analysis by plotting the difference between CC and AC-DC against their mean. Potential bias and the limit of agreement were

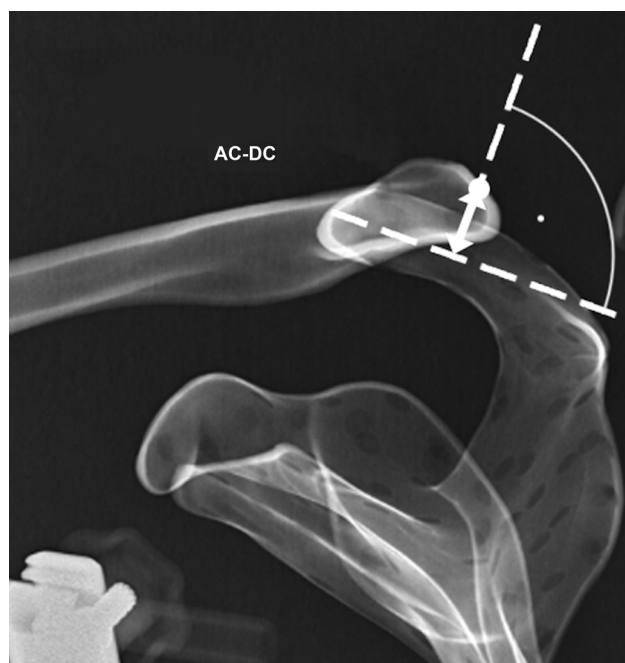

Figure 1 The midacromial to dorsal clavicle (AC-DC) distance as measured in the lateral Alexander view of the left shoulder taken from a sawbone model used in our original validation study.

estimated to determine whether the 2 measurements may be used interchangeably. Following Kolmogorov-Smirnov normality testing, average values for CC distance and AC-DC by Rockwood group were compared using a 1-way analysis of variance with intergroup comparison of CC distance vs. AC-DC in each Rockwood grade. A Bonferroni correction was employed to account for multiple comparisons.

Statistical analyses were performed with the use of R statistical software (R Core Team, Vienna, Austria) and graphs generated with the use of GraphPad Prism, version 8.2.1, for mac OS (GraphPad Software, La Jolla, CA, USA).

Results

Ninety patients (78 male, 12 female) treated for AC joint injuries met our inclusion criteria and were included in the study. Mean patient age was 43 years (range 18-82 years). Following initial diagnosis, 29 patients were treated conservatively, whereas 61 patients were treated surgically. The study cohort comprised 10 patients (11%) with type II injuries, 37 patients (41%) with type III injuries, 8 patients (9%) with type IV injuries, and 35 patients (39%) with type V injuries.

Inter- and intraobserver reliability was very high for both CC distance and AC-DC (Table I), which demonstrated good reproducibility for this new measurement method. Median difference between the 2 observers was 2 mm (SD 1.6 mm) for AC-DC and 1 mm (SD 1.0 mm) for CC distance.

Table I Interobserver and intraobserver reliability for CC distance and AC-DC

	CC distance		AC-DC	
	ICC (2,1)	95% CI	ICC (2,1)	95% CI
Interobserver	0.97	0.95, 0.98	0.95	0.83, 0.98
Intraobserver	0.97	0.95, 0.98	0.96	0.93, 0.98

CC, coracoclavicular; AC-DC, acromial center line to dorsal clavicle; ICC, intraclass correlation coefficient; CI, confidence interval.

The calculated difference between healthy and injured shoulder was on average 10 mm (SD 4.3 mm) according to CC distance and 13 mm (SD 6.0 mm) according to AC-DC. Correlation between the 2 measurements was moderate as demonstrated by the Pearson correlation coefficient r of 0.57 ($P < .001$) (Fig. 2).

Bland-Altman analysis demonstrated a mean difference of -3.9 mm (95% confidence interval: $-4.9, 2.8$) between the pairs of measurements, indicating that a systematic bias is present with lower values for CC distance compared with AC-DC (Fig. 3). The limit of agreement between the measurement pairs ranged from -13.7 mm to 6.0 mm, with a critical difference of ± 9.8 mm. The differences between the 2 measurements showed low negative correlation (Pearson $r = -0.38, P < .001$) to their averages. This implies that the difference was not random, and the bias is dependent on the amount of AC joint displacement. Although displacement lower than 10 mm presented acceptable agreement, the disagreement increased with displacement above 10 mm.

Bland-Altman analysis by Rockwood grade confirmed the dependence of the disagreement (Fig. 3). All Rockwood IV injuries had greater AC-DC values when compared with CC distance. Overall, increasing divergence between the 2 values with increasing Rockwood grade was measured.

Figure 4 shows a comparison of mean CC distance and AC-DC by Rockwood grade. Intergroup analysis as part of a 1-way analysis of variance with Bonferroni correction demonstrated a significant difference between CC distance and AC-DC for injuries graded as Rockwood III ($P = .0013$), Rockwood IV ($P = .0003$), and Rockwood V ($P = .0020$). There was no significant difference between values for Rockwood II injuries ($P = .6016$).

Discussion

Classification of AC joint injuries is based on the work of Tossy and Rockwood.^{13,18} As originally presented by Rockwood in 1984, a 6-part classification system describes AC joint separations in a sequential progression of soft tissue injury beginning with the AC ligaments, followed by coracoclavicular ligaments and ending with disruption of deltatrapezial fascia. The classification was based on evaluation of plain radiographs from patients treated over a period of years.

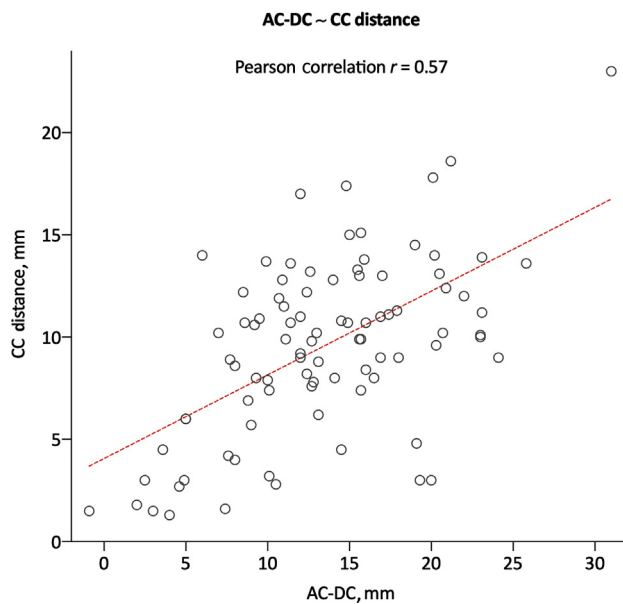


Figure 2 CC distance vs. AC-DC, demonstrating moderate correlation between the 2 measurements (Pearson correlation $r = 0.57$). CC, coracoclavicular; AC-DC, acromial center line to dorsal clavicle.

Later studies attempted to assess the reliability of this classification system. Kraeutler et al⁶ discovered that interobserver reliability between 8 shoulder surgeons who recommended patient treatment based on examination of AP and axial radiographs, was only moderate, with an intraclass correlation coefficient of 0.602.

As the level of surgeon experience was thought to increase reliability, Cho et al³ recruited 10 experienced shoulder surgeons (average 11.2 years of practice) to assess AC joint separations on plain radiographs. By means of the k correlation coefficient, inter- and intraobserver reliability was found to be fair ($k = 0.214$) and moderate ($k = 0.474$), respectively.

Additional studies based on simple radiographs also demonstrated an overall limited reliability and consistency of the Rockwood classification.^{9,10} The attempt to better define Rockwood's classification by combining 3D computed tomography (CT) with radiographs did not yield increased inter- and intraobserver reliability.³ Thus, there is no clear evidence for the utility of CT.

Some authors have proposed the use of magnetic resonance imaging to assess soft tissue injury. Schaefer et al¹⁴ reported the use of magnetic resonance imaging to aid differentiation between type II and III injuries, based on observed coracoclavicular ligament integrity; however, the clinical relevance of magnetic resonance imaging to patient treatment outcomes has yet to be proven.

Assessing and classifying vertical instability using plain Zanca AP radiographs is known to be influenced by

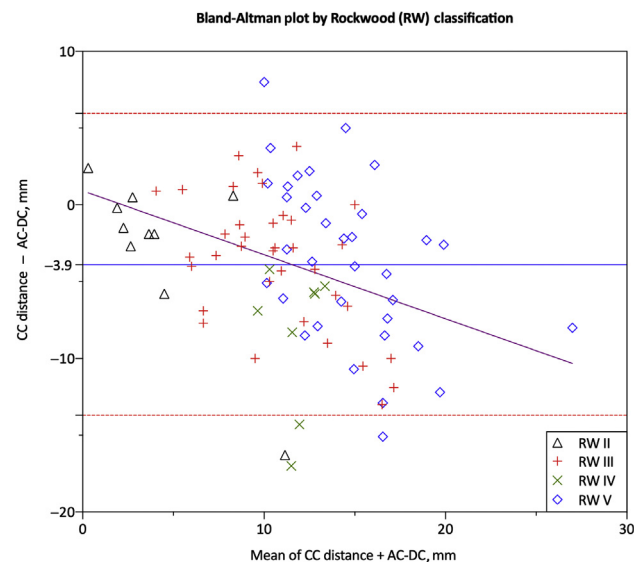


Figure 3 Bland-Altman analysis plot showing the difference between CC distance and AC-DC against the mean of the 2 measurements. The plot shows a bias of -3.9 mm (—) and a 95% limit of agreement from -13.7 to 6 mm (---). The — shows linear regression between the differences and means from the 2 measurements and demonstrates that as the values for CC and AC-DC distance increase, so does the difference between the 2 measurement methods. The Rockwood Classification (RW) for each measurement is shown; of note, all Rockwood IV injuries demonstrated a lower CC distance than AC-DC. CC, coracoclavicular; AC-DC, acromial center line to dorsal clavicle.

projectional variation.¹³ Horizontal displacement is even more difficult to estimate and is not usually taken into account. It has been shown that the classic axillary views may not be suitable to assess posterior clavicle translation.^{5,12} The lateral Alexander view may be more appropriate for semiquantitative assessment.^{15,19}

In a previously published in vitro study, we demonstrated that the measured AC-DC distance in lateral Alexander views showed excellent interobserver reliability, as well as higher correlation with CT-measured vertical displacement, when compared with the CC distance.²⁰ An omission from that study was assessment of the accuracy of AC-DC in measuring the total AC joint displacement, that is, the vector magnitude of combined vertical and horizontal displacement. Although AC-DC showed excellent correlation with CT-measured vertical displacement, while allowing for 20° of variation in projection in 3 dimensions ($r = 0.939$), further analysis of the data since that publication demonstrated even higher correlation between AC-DC and the total vector of displacement ($r = 0.972$). This finding confirms that AC-DC, although excellent at measuring vertical AC joint displacement, actually measures a component of both vertical and horizontal displacement and is more accurate at measuring the

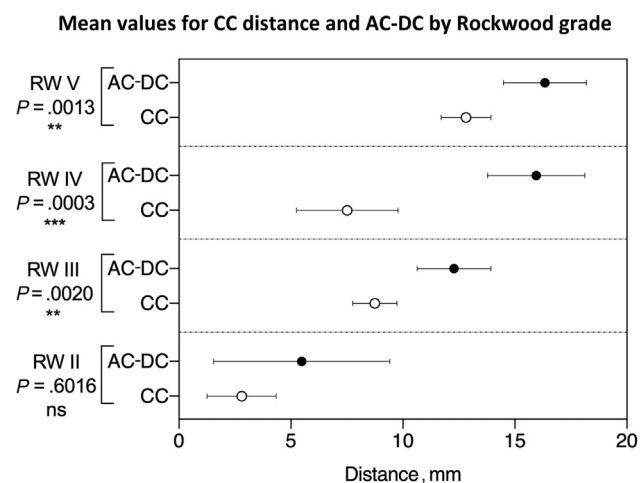


Figure 4 Mean values with 95% confidence intervals for CC distance and AC-DC by Rockwood grade, including results of intergroup analysis following 1-way analysis of variance with Bonferroni correction. CC, coracoclavicular; AC-DC, acromial center line to dorsal clavicle.

composite total AC joint displacement than the vertical component in isolation. This characteristic of AC-DC makes the measurement more versatile than initially thought as it potentially allows a single measurement to take account of both planes of AC joint displacement, a feature confirmed by the findings of this study.

In the present retrospective study, we evaluated the correlation between these 2 measurements in a relatively large population of patients. The 2 measurements demonstrated moderate correlation with each other, as shown by a Pearson correlation coefficient r of 0.57. In the injured AC joints studied, the CC distance demonstrated lower values compared with the AC-DC distance, with a mean difference of -3.9 mm, as indicated by the Bland-Altman plot (Fig. 3). The 95% limit of agreement of the 2 measurements was statistically significant at ± 9.8 mm (-13.7 to 6.0 mm); however, this is too large an interval to have any meaningful usefulness in the clinical context. Thus, the 2 measurement methods cannot be used interchangeably.

Of particular interest was that in Rockwood grade IV injuries, the CC distance was always lower than the AC-DC distance (Fig. 3). This further demonstrates the utility of the AC-DC measurement in evaluating total displacement of the AC joint by including horizontal as well as vertical displacement, a feature that is absent when using CC distance alone. Figure 4 illustrates this point as the greatest discrepancy between CC distance and AC-DC occurred in the Rockwood IV group, within which horizontal displacement accounts for a greater proportion of total displacement than in the other Rockwood groups. Intergroup comparison of CC distance and AC-DC by Rockwood grade also supported this finding as there was no significant difference between the mean measurements for

Rockwood II injuries, which consisted purely of vertical displacement, although the mean values for Rockwood III, IV, and V injuries showed a significant difference between CC distance and AC-DC. Each of these injury groups are likely to include a degree of horizontal displacement that cannot be by CC distance alone. A low CC distance may therefore mask an underlying element of posterior horizontal displacement. Furthermore, the negative slope of correlation between the values in the Bland-Altman plot (purple line, Fig. 3) indicates that the difference between the 2 measurements tends to increase with increasing AC joint displacement. The common result in these analyses is that the CC values appear to lag compared with the AC-DC distance in higher Rockwood grades, especially in the presence of posterior horizontal displacement. Because there is only a moderate correlation between the 2 radiographic parameters, these findings may suggest that the CC distance, and thus the Rockwood system, may underestimate the severity of AC disruption. Previous studies have also highlighted the danger of underestimating and under-treating these injuries based on this classification system.^{7,16}

Figure 5 shows a clinical case from this series demonstrating the degree to which AC joint instability can be underestimated on an AP Zanca view and by measurement of CC distance, even when using a panoramic projection to compare the injured to the uninjured side. The radiographs show a Rockwood IV injury although an AP review measured a difference in CC distance of only 3 mm. On this occasion, the unstable Rockwood IV injury is clearly visible on the Alexander view and showed an AC-DC measurement of 20 mm, far more representative of the degree of instability than the CC distance. Certainly, using CC distance alone in this case could falsely lead the clinician to underestimate the severity of the injury and possibly discharge the patient earlier than would be appropriate following a nonoperative treatment path when following the ISAKOS algorithm.

It should be noted that the present study is based on retrospective evaluation of radiographic parameters with no other additional clinical input. The Bland-Altman analysis may only be applied to demonstrate the relationship between 2 measurement methods and cannot predict which method is more reliable for the problem in question. It is a limitation of this study that because of its retrospective nature, the actual AC joint disruption in both planes cannot be known in absolute terms, that is, by means of CT. Thus, it is not possible to compare the 2 methods against isolated vertical or combined total displacement to evaluate which one is more accurate. It was beyond the scope of this study to define a scale for categorization of injury or development of a new algorithm for AC joint injury management, although, given the utility of AC-DC over CC distance in discriminating the degree of total displacement, this will form the stage in the research process. A well-designed prospective study would be necessary to decide which

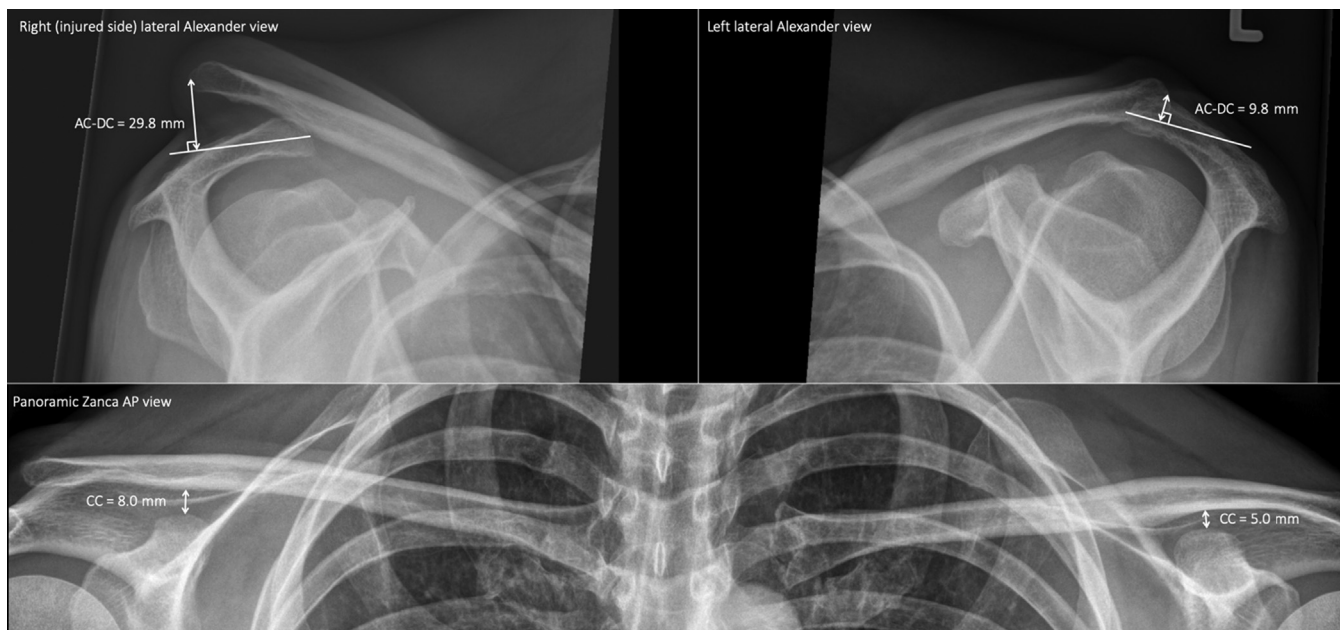


Figure 5 Clinical case radiographs: panoramic Zanca AP view and lateral Alexander views of the injured right side and uninjured left side. It was subjectively judged as Rockwood IV. Difference between left and right CC distance = 3 mm and AC-DC = 20 mm. AC-DC, acromial center line to dorsal clavicle; AP, anteroposterior; CC, coracoclavicular.

radiographic measurement should be the gold standard and whether the currently used classification system can be reliably used to predict the severity of AC joint disruption.

Conclusion

The AC-DC measurement and use of the Alexander view, particularly in the presence of more extensive instability and displacement in the horizontal plane, provides the clinician with a more realistic appreciation of the magnitude of injury sustained and would better inform the decision-making process in discussion with the patient regarding management options and recommendations. Use of the AC-DC measurement, in combination with comprehensive clinical assessment and patient counseling, may help to direct clinic management of AC joint injuries more appropriately in the early stages through better identification of unstable injuries and reduce the number of cases where AC joint instability is underestimated, possibly leading to poorly informed patient management.

Disclaimer

This study was supported by an EFORT visiting fellowship grant (OK and RM).

The authors, their immediate families, and any research foundations with which they are affiliated have not received any financial payments or other benefits from any commercial entity related to the subject of this article.

References

- Alexander OM. Radiography of the acromioclavicular articulation. *Med Radiogr Photogr* 1954;30:34-9.
- Beitzel K, Mazzocca AD, Bak K, Itoi E, Kibler WB, Mirzayan R, et al. ISAKOS Upper Extremity Committee consensus statement on the need for diversification of the Rockwood classification for acromioclavicular joint injuries. *Arthroscopy* 2014;30:271-8. <https://doi.org/10.1016/j.arthro.2013.11.005>
- Cho CH, Hwang I, Seo JS, Choi CH, Ko SH, Park HB, et al. Reliability of the classification and treatment of dislocations of the acromioclavicular joint. *J Shoulder Elbow Surg* 2014;23:665-70. <https://doi.org/10.1016/j.jse.2014.02.005>
- Cisneros LN, Reiriz JS. Prevalence of remaining horizontal instability in high-grade acromioclavicular joint injuries surgically managed. *Eur J Orthop Surg Traumatol* 2017;27:323-33. <https://doi.org/10.1007/s00590-016-1898-0>
- Gastaud O, Raynier JL, Duparc F, Baverel L, Andrieu K, Tarissi N, et al. Reliability of radiographic measurements for acromioclavicular joint separations. *Orthop Traumatol Surg Res* 2015;101(8 Suppl):S291-5. <https://doi.org/10.1016/j.otsr.2015.09.010>
- Kraeutler MJ, Williams GR, Cohen SB, Ciccotti MG, Tucker BS, Dines JS, et al. Inter- and intraobserver reliability of the radiographic diagnosis and treatment of acromioclavicular joint separations. *Orthopedics* 2012;35:e1483-7. <https://doi.org/10.3928/01477447-20120919-16>

7. Mouhsine E, Garofalo R, Crevoisier X, Farron A. Grade I and II acromioclavicular dislocations: results of conservative treatment. *J Shoulder Elbow Surg* 2003;12:599-602. [https://doi.org/10.1016/S1058-2746\(03\)00215-5](https://doi.org/10.1016/S1058-2746(03)00215-5)
8. Munro BH. *Statistical methods for health care research*. Philadelphia, PA: Lippincott Williams & Wilkins; 2005.
9. Ng CY, Smith EK, Funk L. Reliability of the traditional classification systems for acromioclavicular joint injuries by radiography. *Shoulder Elbow* 2012;4:266-9. <https://doi.org/10.1111/j.1758-5740.2012.00202.x>
10. Pifer M, Ashfaq K, Maerz T, Jackson A, Baker K, Anderson K. Intra- and interdisciplinary agreement in the rating of acromioclavicular joint dislocations. *Phys Sportsmed* 2013;41:25-32. <https://doi.org/10.3810/psm.2013.11.2033>
11. Pogorzelski J, Beitzel K, Ranuccio F, Wörtler K, Imhoff AB, Millett PJ, et al. The acutely injured acromioclavicular joint—which imaging modalities should be used for accurate diagnosis? A systematic review. *BMC Musculoskelet Disord* 2017;18:515. <https://doi.org/10.1186/s12891-017-1864-y>
12. Rahm S, Wieser K, Spross C, Vich M, Gerber C, Meyer DC. Standard axillary radiographs of the shoulder may mimic posterior subluxation of the lateral end of the clavicle. *J Orthop Trauma* 2013;27:622-6. <https://doi.org/10.1097/BOT.0b013e31828f912c>
13. Rockwood CA, Green DP. *Fractures in adults*. Philadelphia, PA: Lippincott; 1984.
14. Schaefer FK, Schaefer PJ, Brossmann J, Hilgert RE, Heller M, Jahnke T. Experimental and clinical evaluation of acromioclavicular joint structures with new scan orientations in MRI. *Eur Radiol* 2006;16:1488-93. <https://doi.org/10.1007/s00330-005-0093-1>
15. Scheibel M, Dröschel S, Gerhardt C, Kraus N. Arthroscopically assisted stabilization of acute high-grade acromioclavicular joint separations. *Am J Sports Med* 2011;39:1507-16. <https://doi.org/10.1177/0363546511399379>
16. Schlegel TF, Burks RT, Marcus RL, Dunn HK. A prospective evaluation of untreated acute grade III acromioclavicular separations. *Am J Sports Med* 2001;29:699-703.
17. Tauber M, Koller H, Hitzl W, Resch H. Dynamic radiologic evaluation of horizontal instability in acute acromioclavicular joint dislocations. *Am J Sports Med* 2010;38:1188-95. <https://doi.org/10.1177/0363546510361951>
18. Tossy JD, Mead NC, Sigmond HM. Acromioclavicular separations: useful and practical classification for treatment. *Clin Orthop Relat Res* 1963;28:111-9.
19. Waldrop JJ, Norwood LA, Alvarez RG. Lateral roentgenographic projections of the acromioclavicular joint. *Am J Sports Med* 1981;9:337-41.
20. Zumstein MA, Schiessl P, Ambuehl B, Bolliger L, Weihs J, Maurer MH, et al. New quantitative radiographic parameters for vertical and horizontal instability in acromioclavicular joint dislocations. *Knee Surg Sports Traumatol Arthrosc* 2018;26:125-35. <https://doi.org/10.1007/s00167-017-4579-6>