



Remplissage for anterior shoulder instability with Hill-Sachs lesions: a systematic review and meta-analysis

Eoghan T. Hurley, MB, BCh, MCh^{a,b,*}, James P. Toale, MB, BCh^{a,b},
Martin S. Davey, MB, BCh, MCh^{a,b}, Christopher A. Colasanti, MD^c,
Leo Pauzenberger, MD^a, Eric J. Strauss, MD^c,
Hannan Mullett, MCh, FRCSI (Tr & Orth)^a

^aSports Surgery Clinic, Dublin, Ireland

^bDepartment of Trauma & Orthopaedic Surgery, Royal College of Surgeons in Ireland, Dublin, Ireland

^cNew York University Langone Medical Center, New York, NY, USA

Background: The purpose of this study was to perform a systematic review and meta-analysis of the current evidence in the literature to determine how arthroscopic Bankart repair (ABR) and remplissage compare with ABR alone and the open Latarjet procedure for anterior shoulder instability in patients with concomitant Hill-Sachs lesions.

Methods: A literature search was performed based on the PRISMA (Preferred Reporting Items for Systematic Reviews and Meta-analyses) guidelines. Studies comparing ABR and remplissage vs. ABR alone or the Latarjet procedure for anterior shoulder instability in patients with Hill-Sachs lesions were included. Clinical outcomes were compared, with all statistical analysis performed using Review Manager (version 5.3). $P < .05$ was considered statistically significant.

Results: Twelve clinical trials were included. There was a significant difference between ABR plus remplissage and ABR alone in total recurrence rate (3.2% vs. 16.8%, $P < .05$) but not the rate of revision due to recurrence (1.7% vs. 8.5%, $P = .06$). There was no significant difference between the Latarjet procedure and ABR plus remplissage in total recurrence rate (7.0% vs. 9.8%, $P = .39$), total revision rate (3.7% vs. 5.7%, $P = .41$), and rate of revision due to recurrence (1.6% vs. 2.1%, $P = .79$). There was a significantly lower rate of complications with ABR and remplissage compared with the Latarjet procedure (0.5% vs. 8.6%, $P = .003$).

Conclusion: In patients with Hill-Sachs lesions and subcritical glenoid bone loss, ABR with remplissage resulted in lower rates of recurrent instability compared with ABR alone while resulting in similar recurrence rates, as well as similar patient-reported outcomes, with lower morbidity and fewer complications, compared with the Latarjet procedure.

Level of evidence: Level III; Systematic Review

© 2020 Journal of Shoulder and Elbow Surgery Board of Trustees. All rights reserved.

Keywords: Bankart; remplissage; Latarjet; anterior shoulder instability; arthroscopy; systematic review

Institutional review board approval was not required for this systematic review.

*Reprint requests: Eoghan T. Hurley, MB, BCh, Sports Surgery Clinic, Northwood Avenue, Santry, Santry Demesne, Dublin 9, Ireland.

E-mail address: eoghanhurley@rcsi.ie (E.T. Hurley).

Anterior shoulder instability is a common clinical pathology, with an incidence in the United States of 23.9 per 100,000 person-years, and recurrent shoulder instability subsequently develops in 14%-100% of first-time dislocators.^{6,41} A high percentage of first-time dislocators have evidence of both detachment of the anteroinferior labrum

(Bankart lesion) and a concomitant impression fracture of the posterosuperior humeral head (Hill-Sachs lesion). In the United States, arthroscopic Bankart repair (ABR) is currently the most widely used shoulder stabilization procedure.³⁷ However, in the setting of an off-track Hill-Sachs lesion, ABR has been shown to have a high failure rate.^{12,34} Thus, the Latarjet procedure is often indicated as the procedure of choice for patients with recurrent shoulder instability, engaging Hill-Sachs defects, and glenoid bone loss.⁷ The Latarjet procedure is considered to provide stability that translates into a lower recurrence rate; however, there are concerns over the complication rate and morbidity of this procedure.^{18,22}

In search of the optimal surgical management in this specific setting, Purchase et al³⁶ originally described the remplissage procedure, which involves a capsulo-tenodesis in which the infraspinatus tendon and posterior capsule fill the Hill-Sachs lesion to prevent it from engaging with the glenoid. The remplissage procedure is performed alongside an ABR and has drawn increasing interest over the years owing to its focused treatment of Hill-Sachs lesions.^{2,28,30} In comparison to ABR alone, this procedure has the potential to reduce recurrent instability rates. The main concern with the procedure has been possible impairment of postoperative range of motion due to the tenodesis effect of the remplissage.

Currently, there is no meta-analysis in the literature comparing the outcomes of ABR and remplissage with those of other widely used surgical techniques for anterior glenohumeral instability without significant glenoid bone loss in the presence of a concomitant Hill-Sachs lesion.^{2,8,28,30} The purpose of this study was to perform a systematic review and meta-analysis of the current evidence in the literature to determine how ABR and remplissage compare with ABR alone and the open Latarjet procedure for anterior shoulder instability in patients with concomitant Hill-Sachs lesions. We hypothesized that ABR and remplissage would result in lower recurrence rates than ABR alone while resulting in less morbidity and fewer complications than the Latarjet procedure.

Methods

Search strategy

A systematic review of the literature was performed using the MEDLINE, Embase, and Cochrane Library databases in accordance with the PRISMA (Preferred Reporting Items for Systematic Reviews and Meta-analyses) guidelines and predefined eligibility criteria.²⁹ The search term “remplissage” was queried as of July 1, 2019. Abstracts published in the English language were reviewed in detail by the first and second authors; any disagreements were arbitrated by the senior author for the final decision. Articles included were clinical studies comparing remplissage with ABR and/or the open Latarjet procedure. The exclusion criteria for our meta-analysis were as follows: abstract only, case series, review studies, biomechanical studies, and cadaveric studies.

Study design, level of evidence, methodologic quality of evidence (MQOE), and follow-up time were documented for each included study. MQOE was assessed using the Newcastle-Ottawa scale, which grade studies as unsatisfactory (0-3), satisfactory (4), good (5-6), or very good (7-9).¹¹ The outcome measures focused on were modeled on a previous model for a meta-analysis evaluating the treatment of anterior shoulder instability²³: (1) Rowe score; (2) shoulder stability, comprising total recurrent instability (including all incidences of recurrent dislocation or subluxation), recurrent dislocation (ie, complete dislocation rather than subluxation), and revision due to recurrence; (3) return to play; (4) complications (total revisions and total complications); and (5) range of motion (forward flexion, external rotation, and internal rotation). Authors were contacted for clarification when clarity was required pertaining to information included or not included in the text.

Statistical analysis

Statistical analyses were performed using Review Manager (Rev-Man for Macintosh, version 5.3 [2014]; Nordic Cochrane Centre–The Cochrane Collaboration, Copenhagen, Denmark). The I^2 statistic was used to quantify heterogeneity between studies.¹⁹ Random-effects models were used when the I^2 value was > 50%; otherwise, fixed-effects models were used. The methods outlined by Hozo et al²⁰ were used to calculate the standard deviation when the range was provided instead. Results were presented as risk ratio (RR) for dichotomous outcomes and mean difference (MD) for continuous outcomes. A confidence interval (CI) of 95% was used, and statistical significance was represented by $P < .05$.

Results

Literature search

The initial literature search resulted in 592 total studies (Fig. 1). After duplicate removal, a total of 311 full texts were evaluated and assessed for eligibility. Twelve studies containing 740 patients were included in the final review.

Study characteristics and patient demographic characteristics

In 8 of the 12 studies, including 361 patients, ABR with remplissage was compared with ABR alone (Table I).^{1,3,5,9,10,15,16,21,27,33,35,40} The remaining 4 studies, including 379 patients, compared ABR with remplissage vs. the open Latarjet procedure. Baseline age, sex, and reported instability measures of patients were similar between the cohorts in all studies.

ABR vs. ABR with remplissage

Rowe score

The Rowe score was reported in 4 studies, comprising 123 ABR procedures alone and 114 procedures that included remplissage. The average Rowe score was 84.2 after the

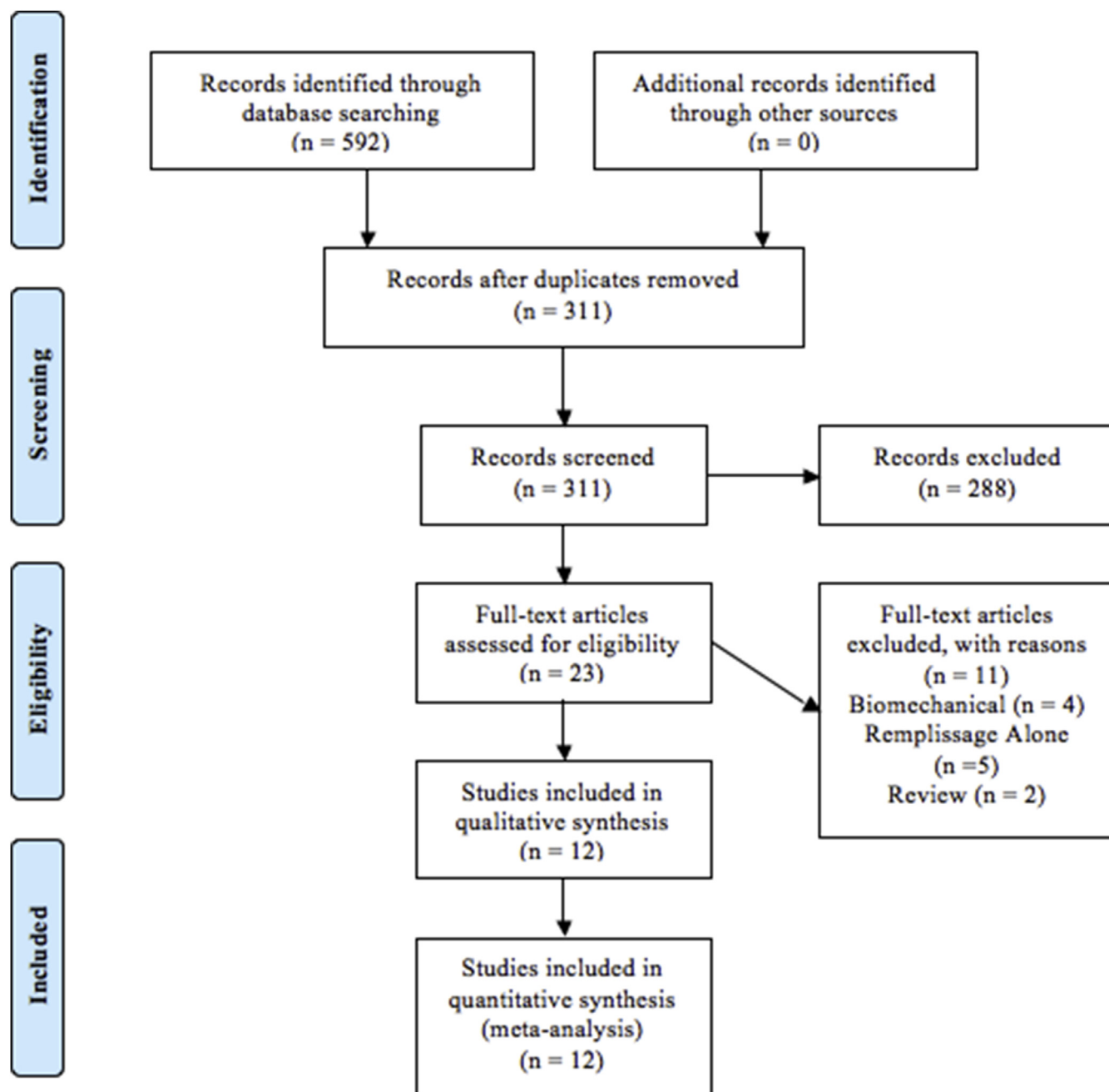


Figure 1 PRISMA (Preferred Reporting Items for Systematic Reviews and Meta-analyses) study selection flow diagram.

ABR procedure compared with 91.3 after remplissage. A statistically significant difference was found in favor of the additive remplissage procedure (MD, -7.13; 95% CI, -8.84 to -5.41; $I^2 = 0\%$; $P < .01$).

Total recurrence rate

Total recurrent instability (including recurrent dislocation or subluxation) was reported in 7 studies, comprising 172 ABR procedures alone and 157 procedures that included remplissage. Recurrent instability occurred in

16.8% of patients who underwent the ABR procedure compared with 3.2% of those who underwent remplissage. A statistically significant difference was found in favor of the additive remplissage procedure (RR, 3.74; 95% CI, 1.67-8.38; $I^2 = 0\%$; $P = .001$).

Recurrent dislocation

Recurrent dislocation was reported in 8 studies, comprising 188 ABR procedures alone and 172 procedures that included remplissage. Recurrent dislocation occurred in

Table I Study characteristics

Author	LOE	Design	MQOE	Patients, n			Age, yr	M/F, n	Follow-up, mo
				ABR	ABR with remplissage	OL			
ABR vs. ABR with remplissage									
Bastard et al, ⁵ 2019	III	RCS	9	39	28	29.6	37/30	128	
Cho et al, ⁹ 2016	III	CCS	9	35	37	25.4	67/5	24	
Franceschi et al, ¹⁵ 2012	III	RCS	9	25	25	26.9	36/14	25	
Garcia et al, ¹⁶ 2015	III	RCS	8	14	10	25.3	18/6	37	
Hughes et al, ²¹ 2018	III	RCS	9	20	21	17.9	33/8	40	
Ko et al, ²⁷ 2016	III	RCS	8	24	24	29.3	37/11	66	
Miyamoto et al, ³³ 2017	III	RCS	8	18	18	28.4	34/2	12	
Nourissat et al, ³⁵ 2011	II	PCS	9	17	15	24.0	20/12	28	
OL vs. ABR with remplissage									
Abouelsoud and Abdelrahman, ¹ 2015	III	RCS	8	16	16	28.2	29/3	31	
Bah et al, ³ 2018	III	RCS	8	43	43	24.0	15/71	47	
Cho et al, ¹⁰ 2016	III	CCS	9	37	35	26.3	66/6	27	
Yang et al, ⁴⁰ 2018	III	RCS	8	98	91	29.1	180/9	38	

LOE, level of evidence; MQOE, methodologic quality of evidence; ABR, arthroscopic Bankart repair; OL, open Latarjet procedure; M, male; F, female; RCS, retrospective cohort study; CCS, case-control study; PCS, prospective cohort study.

14.8% of patients who underwent the ABR procedure compared with 1.7% of those who underwent remplissage. A statistically significant difference was found in favor of the additive remplissage procedure (MD, 4.35; 95% CI, 1.79-10.58; $I^2 = 0\%$; $P = .001$).

Revisions due to recurrence

Revisions due to recurrent instability were reported in 7 studies, comprising 172 ABR procedures alone and 157 procedures that included remplissage. Revision due to recurrent instability was required in 8.5% of patients who underwent the ABR procedure compared with 1.7% of those who underwent remplissage. There was no statistically significant difference between the procedures (RR, 2.54; 95% CI, 0.97-6.66; $I^2 = 0\%$; $P = .06$).

Return to play

Return to play was reported in 3 studies, comprising 66 ABR procedures alone and 62 procedures that included remplissage. The rate of patients returning to play was 78.8% for the ABR procedure compared with 83.9% for the remplissage procedure. There was no statistically significant difference between the procedures (RR, 1.00; 95% CI, 0.86-1.15; $I^2 = 6\%$; $P = .55$).

Range of motion

Forward flexion

Forward flexion was reported in 3 studies, comprising 78 ABR procedures alone and 80 procedures that included remplissage. The ABR procedure resulted in average forward flexion of 165.2°, whereas the remplissage procedure resulted in average forward flexion of 162.1°. There was no statistically significant difference between the procedures (MD, 3.11°; 95% CI, -1.30° to 7.52°; $I^2 = 39\%$; $P = .17$).

External rotation with arm at side

External rotation with the arm at the side was reported in 3 studies, comprising 78 ABR procedures alone and 80 procedures that included remplissage. Average external rotation with the arm at the side was 62.7° after the ABR procedure compared with 55.6° after the remplissage procedure. There was no statistically significant difference between the procedures (MD, 7.20°; 95% CI, -6.85° to 21.24°; $I^2 = 91\%$; $P = .32$).

Open Latarjet procedure vs. ABR and remplissage

Rowe score

The Rowe score was reported in 3 studies, comprising 94 open Latarjet procedures and 96 procedures that included remplissage. The average Rowe score was 88.4 after the open Latarjet procedure compared with 89.4 after remplissage. There was no statistically significant difference between the procedures (MD, -0.96; 95% CI, -3.43 to 1.50; $I^2 = 48\%$; $P = .44$).

Total recurrence rate

Total recurrent instability (including recurrent dislocation or subluxation) was reported in 4 studies, comprising 185 open Latarjet procedures and 194 procedures that included remplissage. The open Latarjet procedure resulted in 7.0% of patients having recurrent instability, whereas the remplissage procedure resulted in 9.8% of patients having recurrent instability. There was no statistically significant difference between the procedures (RR, 0.74; 95% CI, 0.37-1.48; $I^2 = 0\%$; $P = .39$).

Recurrent dislocation

Recurrent dislocation was reported in 2 studies, comprising 107 open Latarjet procedures and 114 procedures that included remplissage. The open Latarjet procedure resulted in 3.7% of patients having recurrent dislocation, whereas the remplissage procedure resulted in 4.4% of patients having recurrent dislocation. There was no statistically significant difference between the procedures (RR, 0.84; 95% CI, 0.23-3.00; $I^2 = 0\%$; $P = .38$).

Revisions due to recurrence

Revisions due to recurrent instability were reported in 4 studies, comprising 185 open Latarjet procedures and 194 procedures that included remplissage. The open Latarjet procedure resulted in 1.6% of patients undergoing revision due to recurrent instability, whereas the remplissage procedure resulted in 2.1% of patients undergoing revision due to recurrent instability. There was no statistically significant difference between the procedures (RR, 0.79; 95% CI, 0.18-3.49; $I^2 = 0\%$; $P = .76$).

Total revisions

Total revisions were reported in 4 studies, comprising 185 Latarjet procedures and 194 procedures that included remplissage. Revision was required in 3.7% of patients who underwent the open Latarjet procedure compared with 5.7% of patients who underwent the remplissage procedure. Revisions following the Latarjet procedure were performed because of recurrence, screw removal, irrigation of hematoma, and bone block fracture. Revisions following the remplissage procedure were performed because of recurrence, subacromial decompression, and glenohumeral débridement. There was no statistically significant difference between the procedures (RR, 0.68; 95% CI, 0.27-1.69; $I^2 = 0\%$; $P = .41$).

Total complications

Total complication rates were reported in 4 studies, comprising 185 Latarjet procedures and 194 procedures that included remplissage. The open Latarjet procedure resulted in complications in 8.6% of patients, whereas the remplissage procedure resulted in complications in 0.5% of patients. The complications in those who underwent the open Latarjet procedure included 4 deep wound infections, 4 cases of painful and/or loose hardware, 3 malunions, 2 graft fractures, 1 nonunion, 1 transient suprascapular nerve palsy, and 1 case of postoperative stiffness. There was 1 deep infection in a patient who underwent remplissage. A statistically significant difference was found in favor of the additive remplissage procedure (RR, 11.77; 95% CI, 2.25-61.49; $I^2 = 0\%$; $P = .003$).

Return to play

Return to play was reported in 1 study, comprising 52 open Latarjet procedures and 52 procedures that included

remplissage. Both procedures resulted in an average return-to-play rate of 90.6%. There was no statistically significant difference between the procedures (MD, 1.00; 95% CI, 0.85-1.17; $I^2 = 0\%$; $P > .999$).

Range of motion

Forward flexion

Forward flexion was reported in 3 studies, comprising 169 open Latarjet procedures and 176 procedures that included remplissage. The open Latarjet procedure resulted in average forward flexion of 159.6°, whereas the remplissage procedure resulted in average forward flexion of 162.4°. There was no statistically significant difference between the procedures (MD, -2.72°; 95% CI, -7.85° to 2.42°; $I^2 = 46\%$; $P = .30$).

External rotation with arm at side

External rotation with the arm at the side was reported in 2 studies, comprising 134 open Latarjet procedures and 141 procedures that included remplissage. The open Latarjet procedure resulted in average external rotation with the arm at the side of 51.7°, whereas the remplissage procedure resulted in average external rotation with the arm at the side of 47.4°. There was no statistically significant difference between the procedures (MD, 4.32°; 95% CI, -11.35° to 19.99°; $I^2 = 90\%$; $P = .59$).

External rotation of arm in abduction

External rotation of the arm in abduction was reported in 2 studies, comprising 134 open Latarjet procedures and 141 procedures that included remplissage. The open Latarjet procedure resulted in average external rotation of the arm in abduction of 65.1°, whereas the remplissage procedure resulted in average external rotation of the arm in abduction of 66.3°. There was no statistically significant difference between the procedures (MD, -1.26°; 95% CI, -16.74° to 14.23°; $I^2 = 78\%$; $P = .87$).

Internal rotation of arm

Internal rotation of the arm was reported in 2 studies, comprising 134 open Latarjet procedures and 141 procedures that included remplissage. The open Latarjet procedure resulted in average internal rotation of the arm of 57.6°, whereas the remplissage procedure resulted in average internal rotation of the arm of 53.4°. There was no statistically significant difference between the procedures (MD, 4.26°; 95% CI, -10.43° to 18.95°; $I^2 = 81\%$; $P = .57$).

Forest plots of all the aforementioned analyses can be found in [Supplementary Appendix S1](#).

Discussion

The most important finding of this study was that ABR with remplissage results in lower instability recurrence rates compared with ABR alone while resulting in similar

recurrence rates, with less morbidity and fewer complications, compared with the Latarjet procedure. Additionally, we found that placing the infraspinatus tendon and posterior capsule in the bony Hill-Sachs defect does not seem to significantly alter postoperative range of motion compared with ABR alone in forward flexion or external rotation, although we were unable to assess potential discrepancies in internal range of motion. Thus, our findings are in accordance with our hypothesis and support the use of an additive remplissage to ABR in the setting of anterior shoulder instability when an engaging Hill-Sachs lesion is present.

The presence of engaging Hill-Sachs lesions has been shown to increase recurrent instability rates.⁴ Of particular interest, which may dictate surgical management, is whether the Hill-Sachs lesion is on-track or off-track.^{12,39} When “off-track” humeral lesions are present, the remplissage and Latarjet procedures are considered superior to Bankart repair alone because these procedures address and mitigate the engagement of the Hill-Sachs lesion with the anterior glenoid rim. Remplissage acts to fill the defect using the infraspinatus and posteroinferior capsule. As a result, engagement of the Hill-Sachs lesion is prevented, and the lesion remains “on-track,” particularly in external rotation and abduction, which is not addressed by a Bankart repair alone. A recent biomechanical systematic review validated these findings and reported that remplissage consistently prevented engagement of the Hill-Sachs lesion on the anterior glenoid in the majority of studies in the literature.²⁸ These biomechanical data have translated into reduced rates of recurrent instability *in vivo*, as highlighted in our data set, in which the combined ABR-remplissage cohort had a 5 times lower rate of recurrence than the cohort that underwent ABR alone. In contrast, the Latarjet procedure acts to widen the glenoid articular surface while simultaneously providing stability by way of the sling effect provided by the transposed conjoint tendon.^{13,26} These 2 effects in combination reduce the chances of Hill-Sachs lesion engagement. Although debate is ongoing as to what is the best surgical option for patients with recurrent shoulder instability and evidence of a significant Hill-Sachs lesion, our meta-analysis demonstrates that significantly lower rates of recurrent instability occur after the Latarjet procedure and remplissage compared with ABR alone.

Many different functional outcome scores were reported in the 12 studies included in our review; however, the most commonly reported measure was the Rowe score. The mean Rowe score in all studies was greater than 80, indicating good outcomes with no significant differences between procedures.²⁵ There was no significant increase when complication rates were compared between ABR alone and Bankart repair with remplissage. Although our complication rates are not as high as the rate reported by Griesser et al¹⁸ in their systematic review of the Latarjet procedure (30%), we calculated an almost 17-fold decrease in

complications in the remplissage cohort compared with patients who underwent the Latarjet procedure.

With such mixed results in the current literature, many orthopedic surgeons have raised concerns about the remplissage procedure and whether it will lead to decreased range of motion postoperatively.^{14,32,35} Our systematic review and meta-analysis demonstrated no statistically significant difference in range of motion following ABR with remplissage vs. that after Bankart repair alone or after the Latarjet procedure. However, although the findings were not statistically significant, it is important for treating orthopedic surgeons to be mindful of patient characteristics (eg, sport played and occupation) because, for some patients, a small deficit in range of motion can have a drastic impact on their performance. Garcia et al¹⁷ highlighted a return-to-play rate of only 50% in baseball players following remplissage compared with 95.5% in non-baseball players. Such findings suggest that deficits that could be considered negligible by most patients may have significant implications for certain athletes, in whom other treatment modalities may be more appropriate.³¹

Return to play has been shown to be the most important clinical outcome measure following shoulder stabilization.³⁸ After remplissage, Cho et al^{9,10} found that 91% of their patients were capable of returning to play. The rates found in this review are slightly higher than the reported rates of return to play following shoulder stabilization in the literature.²⁴ When reported, remplissage and the Latarjet procedure showed equally high rates of return to play. Unfortunately, return to play has been insufficiently reported after the remplissage procedure. This finding suggests the need for future research to address the question of return to play for various sports after remplissage compared with that after the Latarjet procedure for those patients who have chronic anterior shoulder instability in the setting of a significant Hill-Sachs lesion.

As each procedure has specific advantages and disadvantages, the choice of ABR with remplissage vs. the Latarjet procedure depends on surgeon training and preference and a thorough discussion with the patient, with careful consideration of specific patient characteristics. Additionally, it is important to note that the amount of glenoid bone loss in the setting of an off-track Hill-Sachs lesion that is critical to failure is still undefined. However, Yang et al⁴⁰ found that with >10% glenoid bone loss, the outcomes were worse in patients who received the remplissage procedure than in those who underwent the Latarjet procedure, although further study is required.

Limitations

This study has several limitations and potential biases, including the limitations of the included studies themselves. Variations in patient populations, surgical techniques, and surgeon experience could all affect the outcomes. Factors

such as preoperative glenoid and humeral bone loss were insufficiently reported and thus could not be quantitatively compared between the groups. However, in 2 of the included studies comparing remplissage and the Latarjet procedure, there was a higher rate of patients who underwent prior surgery in the Latarjet cohort. Additionally, Warth et al³⁸ found that the greatest concern among patients undergoing surgery for anterior shoulder instability was the ability to return to sport, whereas the reported outcomes regarding return to play in this study were limited.

Conclusion

In patients with Hill-Sachs lesions and subcritical glenoid bone loss, ABR with remplissage resulted in lower rates of recurrent instability compared with ABR alone while resulting in similar recurrence rates, as well as similar patient-reported outcomes, with lower morbidity and fewer complications, compared with the Latarjet procedure.

Disclaimer

The authors, their immediate families, and any research foundations with which they are affiliated have not received any financial payments or other benefits from any commercial entity related to the subject of this article.

Supplementary data

Supplementary data to this article can be found online at <https://doi.org/10.1016/j.jse.2020.06.021>.

References

1. Abouelsoud MM, Abdelrahman AA. Recurrent anterior shoulder dislocation with engaging Hill-Sachs defect: remplissage or Latarjet? *Eur Orthop Traumatol* 2015;6:151-6. <https://doi.org/10.1007/s12570-015-0313-3>
2. Alkaduhimi H, Verweij LPE, Willigenburg NW, van Deurzen DFP, van den Bekerom MPJ. Remplissage with Bankart repair in anterior shoulder instability: a systematic review of the clinical and cadaveric literature. *Arthroscopy* 2019;35:1257-66. <https://doi.org/10.1016/j.arthro.2018.10.117>
3. Bah A, Lateur GM, Kouevidjin BT, Bassinga JYS, Issa M, Jaafar A, et al. Chronic anterior shoulder instability with significant Hill-Sachs lesion: arthroscopic Bankart with remplissage versus open Latarjet procedure. *Orthop Traumatol Surg Res* 2018;104:17-22. <https://doi.org/10.1016/j.otsr.2017.11.009>
4. Baker CL, Uribe JW, Whitman C. Arthroscopic evaluation of acute initial anterior shoulder dislocations. *Am J Sports Med* 1990;18:25-8.
5. Bastard C, Herisson O, Gaillard J, Nourissat G. Impact of remplissage on global shoulder outcome: a long-term comparative study. *Arthroscopy* 2019;35:1362-7. <https://doi.org/10.1016/j.arthro.2019.01.013>
6. Boone JL, Arciero RA. First-time anterior shoulder dislocations: has the standard changed? *Br J Sports Med* 2010;44:355-60. <https://doi.org/10.1136/bjsm.2009.062596>
7. Burkhart SS, De Beer JF. Traumatic glenohumeral bone defects and their relationship to failure of arthroscopic Bankart repairs: significance of the inverted-pear glenoid and the humeral engaging Hill-Sachs lesion. *Arthroscopy* 2000;16:677-94.
8. Buza JA III, Iyengar JJ, Anakwenze OA, Ahmad CS, Levine WN. Arthroscopic Hill-Sachs remplissage: a systematic review. *J Bone Joint Surg Am* 2014;96:549-55. <https://doi.org/10.2106/JBJS.L.01760>
9. Cho NS, Yoo JH, Juh HS, Rhee YG. Anterior shoulder instability with engaging Hill-Sachs defects: a comparison of arthroscopic Bankart repair with and without posterior capsulodesis. *Knee Surg Sports Traumatol Arthrosc* 2016;24:3801-8. <https://doi.org/10.1007/s00167-015-3686-5>
10. Cho NS, Yoo JH, Rhee YG. Management of an engaging Hill-Sachs lesion: arthroscopic remplissage with Bankart repair versus Latarjet procedure. *Knee Surg Sports Traumatol Arthrosc* 2016;24:3793-800. <https://doi.org/10.1007/s00167-015-3666-9>
11. Deeks JJ, Dinnes J, D'Amico R, Sowden AJ, Sakarovich C, Song F, et al. Evaluating non-randomised intervention studies. *Health Technol Assess* 2003;7:iii-x.1-173. <https://doi.org/10.3310/hta7270>
12. Di Giacomo G, Itoi E, Burkhart SS. Evolving concept of bipolar bone loss and the Hill-Sachs lesion: from "engaging/non-engaging" lesion to "on-track/off-track" lesion. *Arthroscopy* 2014;30:90-8. <https://doi.org/10.1016/j.arthro.2013.10.004>
13. Dines JS, Dodson CC, McGarry MH, Oh JH, Altchek DW, Lee TQ. Contribution of osseous and muscular stabilizing effects with the Latarjet procedure for anterior instability without glenoid bone loss. *J Shoulder Elbow Surg* 2013;22:1689-94. <https://doi.org/10.1016/j.jse.2013.02.014>
14. Elkinson I, Giles JW, Faber KJ, Boons HW, Ferreira LM, Johnson JA, et al. The effect of the remplissage procedure on shoulder stability and range of motion: an in vitro biomechanical assessment. *J Bone Joint Surg Am* 2012;94:1003-12. <https://doi.org/10.2106/JBJS.J.01956>
15. Franceschi F, Papalia R, Rizzello G, Franceschetti E, Del Buono A, Panasci M, et al. Remplissage repair—new frontiers in the prevention of recurrent shoulder instability: a 2-year follow-up comparative study. *Am J Sports Med* 2012;40:2462-9. <https://doi.org/10.1177/0363546512458572>
16. Garcia GH, Park MJ, Zhang C, Kelly JD IV, Huffman GR. Large Hill-Sachs lesion: a comparative study of patients treated with arthroscopic Bankart repair with or without remplissage. *HSS J* 2015;11:98-103. <https://doi.org/10.1007/s11420-015-9438-8>
17. Garcia GH, Wu HH, Liu JN, Huffman GR, Kelly JD IV. Outcomes of the remplissage procedure and its effects on return to sports: average 5-year follow-up. *Am J Sports Med* 2016;44:1124-30. <https://doi.org/10.1177/0363546515626199>
18. Griesser MJ, Harris JD, McCoy BW, Hussain WM, Jones MH, Bishop JY, et al. Complications and re-operations after Bristow-Latarjet shoulder stabilization: a systematic review. *J Shoulder Elbow Surg* 2013;22:286-92. <https://doi.org/10.1016/j.jse.2012.09.009>
19. Higgins JP, Thompson SG, Deeks JJ, Altman DG. Measuring inconsistency in meta-analyses. *BMJ* 2003;327:557-60. <https://doi.org/10.1136/bmj.327.7414.557>
20. Hozo SP, Djulbegovic B, Hozo I. Estimating the mean and variance from the median, range, and the size of a sample. *BMC Med Res Methodol* 2005;5:13. <https://doi.org/10.1186/1471-2288-5-13>
21. Hughes JL, Bastrom T, Pennock AT, Edmonds EW. Arthroscopic Bankart repairs with and without remplissage in recurrent adolescent anterior shoulder instability with Hill-Sachs deformity. *Orthop J Sports Med* 2018;6:2325967118813981. <https://doi.org/10.1177/2325967118813981>

22. Hurley ET, Jamal MS, Ali ZS, Montgomery C, Pauzenberger L, Mullett H. Long-term outcomes of the Latarjet procedure for anterior shoulder instability: a systematic review of studies at 10-year follow-up. *J Shoulder Elbow Surg* 2019;28:e33-9. <https://doi.org/10.1016/j.jse.2018.08.028>
23. Hurley ET, Lim Fat D, Farrington SK, Mullett H. Open versus arthroscopic Latarjet procedure for anterior shoulder instability: a systematic review and meta-analysis. *Am J Sports Med* 2019;47:1248-53. <https://doi.org/10.1177/0363546518759540>
24. Hurley ET, Montgomery C, Jamal MS, Shimozone Y, Ali Z, Pauzenberger L, et al. Return to play after the Latarjet procedure for anterior shoulder instability: a systematic review. *Am J Sports Med* 2019;47:3002-8. <https://doi.org/10.1177/0363546519831005>
25. Jensen KU, Bongaerts G, Bruhn R, Schneider S. Not all Rowe scores are the same! Which Rowe score do you use? *J Shoulder Elbow Surg* 2009;18:511-4. <https://doi.org/10.1016/j.jse.2009.02.003>
26. Kephart CJ, Abdulian MH, McGarry MH, Tibone JE, Lee TQ. Biomechanical analysis of the modified Bristow procedure for anterior shoulder instability: is the bone block necessary? *J Shoulder Elbow Surg* 2014;23:1792-9. <https://doi.org/10.1016/j.jse.2014.03.003>
27. Ko SH, Cha JR, Lee CC, Hwang IY, Choe CG, Kim MS. The influence of arthroscopic remplissage for engaging Hill-Sachs lesions combined with Bankart repair on redislocation and shoulder function compared with Bankart repair alone. *Clin Orthop Surg* 2016;8:428-36. <https://doi.org/10.4055/cios.2016.8.4.428>
28. Lazarides AL, Duchman KR, Ledbetter L, Riboh JC, Garrigues GE. Arthroscopic remplissage for anterior shoulder instability: a systematic review of clinical and biomechanical studies. *Arthroscopy* 2019;35:617-28. <https://doi.org/10.1016/j.arthro.2018.09.029>
29. Liberati A, Altman DG, Tetzlaff J, Mulrow C, Gotzsche PC, Ioannidis JP, et al. The PRISMA statement for reporting systematic reviews and meta-analyses of studies that evaluate health care interventions: explanation and elaboration. *J Clin Epidemiol* 2009;62:e1-34. <https://doi.org/10.1016/j.jclinepi.2009.06.006>
30. Liu JN, Gowd AK, Garcia GH, Cvetanovich GL, Cabarcas BC, Verma NN. Recurrence rate of instability after remplissage for treatment of traumatic anterior shoulder instability: a systematic review in treatment of subcritical glenoid bone loss. *Arthroscopy* 2018;34:2894-907.e2. <https://doi.org/10.1016/j.arthro.2018.05.031>
31. Memon M, Kay J, Cadet ER, Shahsavari S, Simunovic N, Ayeni OR. Return to sport following arthroscopic Bankart repair: a systematic review. *J Shoulder Elbow Surg* 2018;27:1342-7. <https://doi.org/10.1016/j.jse.2018.02.044>
32. Merolla G, Paladini P, Di Napoli G, Campi F, Porcellini G. Outcomes of arthroscopic Hill-Sachs remplissage and anterior Bankart repair: a retrospective controlled study including ultrasound evaluation of posterior capsulotenodesis and infraspinatus strength assessment. *Am J Sports Med* 2015;43:407-14. <https://doi.org/10.1177/0363546514559706>
33. Miyamoto R, Yamamoto A, Shitara H, Ichinose T, Shimoyama D, Sasaki T, et al. Clinical outcome of arthroscopic remplissage as augmentation during arthroscopic Bankart repair for recurrent anterior shoulder instability. *Open Orthop J* 2017;11:1268-76. <https://doi.org/10.2174/1874325001711011268>
34. Murphy AI, Hurley ET, Hurley DJ, Pauzenberger L, Mullett H. Long-term outcomes of the arthroscopic Bankart repair: a systematic review of studies at 10-year follow-up. *J Shoulder Elbow Surg* 2019;28:2084-9. <https://doi.org/10.1016/j.jse.2019.04.057>
35. Nourissat G, Kilinc AS, Werther JR, Doursounian L. A prospective, comparative, radiological, and clinical study of the influence of the "remplissage" procedure on shoulder range of motion after stabilization by arthroscopic Bankart repair. *Am J Sports Med* 2011;39:2147-52. <https://doi.org/10.1177/0363546511416315>
36. Purchase RJ, Wolf EM, Hobgood ER, Pollock ME, Smalley CC. Hill-Sachs "remplissage": an arthroscopic solution for the engaging hill-Sachs lesion. *Arthroscopy* 2008;24:723-6. <https://doi.org/10.1016/j.arthro.2008.03.015>
37. Riff AJ, Frank RM, Sumner S, Friel N, Bach BR Jr, Verma NN, et al. Trends in shoulder stabilization techniques used in the United States based on a large private-payer database. *Orthop J Sports Med* 2017;5:2325967117745511. <https://doi.org/10.1177/2325967117745511>
38. Warth RJ, Briggs KK, Dornan GJ, Horan MP, Millett PJ. Patient expectations before arthroscopic shoulder surgery: correlation with patients' reasons for seeking treatment. *J Shoulder Elbow Surg* 2013;22:1676-81. <https://doi.org/10.1016/j.jse.2013.05.003>
39. Yamamoto N, Itoi E, Abe H, Minagawa H, Seki N, Shimada Y, et al. Contact between the glenoid and the humeral head in abduction, external rotation, and horizontal extension: a new concept of glenoid track. *J Shoulder Elbow Surg* 2007;16:649-56. <https://doi.org/10.1016/j.jse.2006.12.012>
40. Yang JS, Mehran N, Mazzocca AD, Pearl ML, Chen VW, Arciero RA. Remplissage versus modified Latarjet for off-track Hill-Sachs lesions with subcritical glenoid bone loss. *Am J Sports Med* 2018;46:1885-91. <https://doi.org/10.1177/0363546518767850>
41. Zacchilli MA, Owens BD. Epidemiology of shoulder dislocations presenting to emergency departments in the United States. *J Bone Joint Surg Am* 2010;92:542-9. <https://doi.org/10.2106/JBJS.I.00450>