



## REVIEW ARTICLES

# The American Society of Shoulder and Elbow Therapists' consensus statement on rehabilitation for anatomic total shoulder arthroplasty

June S. Kennedy, PT, DPT, OCS<sup>a,\*</sup>, Grant E. Garrigues, MD<sup>b</sup>,  
Federico Pozzi, PT, MA, PhD<sup>c</sup>, Matthew J. Zens, DPT, SCS, ATC<sup>d</sup>, Bryce Gaunt, PT, SCS<sup>e</sup>,  
Brian Phillips, PT, DPT<sup>e</sup>, Ashim Bakshi, MHS, OTR, CHT<sup>f</sup>, Angela R. Tate, PT, PhD<sup>g,h</sup>

<sup>a</sup>Department of Physical and Occupational Therapy, Duke University Health Systems, Durham, NC, USA

<sup>b</sup>Midwest Orthopaedics at Rush, Chicago, IL, USA

<sup>c</sup>University of Florida, Gainesville, FL, USA

<sup>d</sup>Dakota Wesleyan University, Mitchell, SD, USA

<sup>e</sup>Human Performance Rehabilitation Centers at St Francis Rehabilitation Center, Columbus, GA, USA

<sup>f</sup>The Hand and Orthopedic Rehab Clinic, Terre Haute, IN, USA

<sup>g</sup>Excel Physical Therapy, Blue Bell, PA, USA

<sup>h</sup>Arcadia University, Glenside, PA, USA

Anatomic total shoulder arthroplasty is the gold standard shoulder replacement procedure for patients with an intact rotator cuff and sufficient glenoid bone to accommodate prosthetic glenoid implant and offers reliable patient satisfaction, excellent implant longevity, and a low incidence of complications. Disparity exists in the literature regarding rehabilitation strategies following anatomic total shoulder arthroplasty. This article presents a consensus statement from experts in the field on rehabilitation following anatomic total shoulder arthroplasty. The goal of this consensus statement is to provide a current evidence-based foundation to inform the rehabilitation process after anatomic total shoulder arthroplasty. These guidelines apply to anatomic total shoulder arthroplasty (replacement of the humeral head and glenoid), hemiarthroplasty (replacing only the humeral head), and hemiarthroplasty with glenoid reaming or resurfacing. The consensus statement integrates an extensive literature review, as well as survey results of the practice patterns of members of the American Society of Shoulder and Elbow Therapists and the American Shoulder and Elbow Surgeons. Three stages of recovery are proposed, which initially protect and then gradually load soft tissue affected by the surgical procedure, such as the subscapularis, for optimal patient outcomes. The proposed guidelines should be used in collaboration with surgeon preferences and patient-specific factors.

**Level of evidence:** Level IV; Expert Opinion

© 2020 Journal of Shoulder and Elbow Surgery Board of Trustees. All rights reserved.

**Keywords:** Shoulder arthroplasty; physical therapy; subscapularis; shoulder replacement; exercise; rehabilitation

\*Reprint requests: June S. Kennedy, PT, DPT, OCS, Duke Sports Medicine Physical Therapy, Pepsico Building 3475 Erwin Rd, Durham, NC 27705, USA.

E-mail address: [June.kennedy@duke.edu](mailto:June.kennedy@duke.edu) (J.S. Kennedy).

Glenohumeral osteoarthritis is increasing because of the rise in the aging population, and though the exact prevalence is unclear, the condition may affect up to one-third of people older than 60 years.<sup>52</sup> Anatomic total shoulder

arthroplasty (ATSA) is the gold standard shoulder replacement procedure for patients with an intact rotator cuff and sufficient glenoid bone to accommodate prosthetic glenoid implantation and offers reliable patient satisfaction, excellent implant longevity, and a low incidence of complications.<sup>24,28,41,51,61</sup> Patients who are not ideal candidates for ATSA because of high physical demand (which will challenge glenoid prosthesis longevity) and those with poor glenoid bone stock may benefit from other anatomic options, including humeral head replacement without addressing the native glenoid (hemiarthroplasty)<sup>38</sup> or hemiarthroplasty with glenoid reaming (ream and run procedure).<sup>21,22,62</sup> Patients with combined rotator cuff deficiency and glenohumeral osteoarthritis may have better outcomes with the nonanatomic option of a reverse total shoulder arthroplasty.<sup>32</sup>

Since the initial description of ATSA and rehabilitation for this procedure by Charles Neer II, MD, and therapist Mary Hughes,<sup>26,48,49</sup> there have been many modifications to the surgical technique, prosthetic components, and rehabilitation processes. As surgical procedures are modified, ongoing updates of rehabilitation guidelines are needed. A recent systematic review demonstrated lack of consistency in the rehabilitation process following ATSA.<sup>10</sup> Articles published since the time of this review also demonstrate disparity regarding sling use, range of motion (ROM), and strengthening recommendations in spite of being written by content experts.<sup>9,53</sup> Therapists must understand the implications of current research and surgical techniques to provide safe and effective rehabilitation strategies.

The goal of this consensus statement is to provide a current evidence-based foundation to inform the rehabilitation process after ATSA. These guidelines apply to ATSA (replacement of the humeral head and glenoid), hemiarthroplasty (replacing only the humeral head), and hemiarthroplasty with glenoid reaming or resurfacing and do not address the unique considerations of the reverse total shoulder arthroplasty. The proposed guidelines should be used in collaboration with surgeon's preferences and patient-specific factors.

## Description of the surgical procedure

Understanding the ATSA surgical procedure is critical for planning and executing postsurgical rehabilitation. Anatomic shoulder arthroplasty is primarily a soft tissue procedure. Meticulous surgical treatment of the subscapularis (SSc), the biceps tendon, and any capsular contractures are all critical elements of the surgery, with important implications for postoperative rehabilitation.

The glenohumeral joint is surrounded by the rotator cuff and thus access to the joint typically involves traversing through the SSc muscle-tendon-bone unit. Though less common, there are alternative approaches that spare the SSc.<sup>2</sup> These include an anterosuperior approach through the

rotator interval<sup>14,35</sup> and a posterior approach through the interval between the teres minor and the infraspinatus.<sup>31</sup> The biceps long head tendon can be protected and left in situ, cut without reattachment (tenotomy), or cut and reattached (tenodesis).<sup>1,60</sup> A soft tissue tenodesis to the pectoralis major is the most popular option.

After entering the joint, the capsule is released fully from the humerus and the humeral head is dislocated. The coracohumeral ligament is generally contracted in glenohumeral osteoarthritis, and release of this structure is paramount. Osteophytes are released to define the native anatomic neck and the humeral head is cut.<sup>55</sup> The humerus is prepared to accept the humeral implant, and an appropriately sized and positioned humeral head is chosen to match the patient's native anatomy.

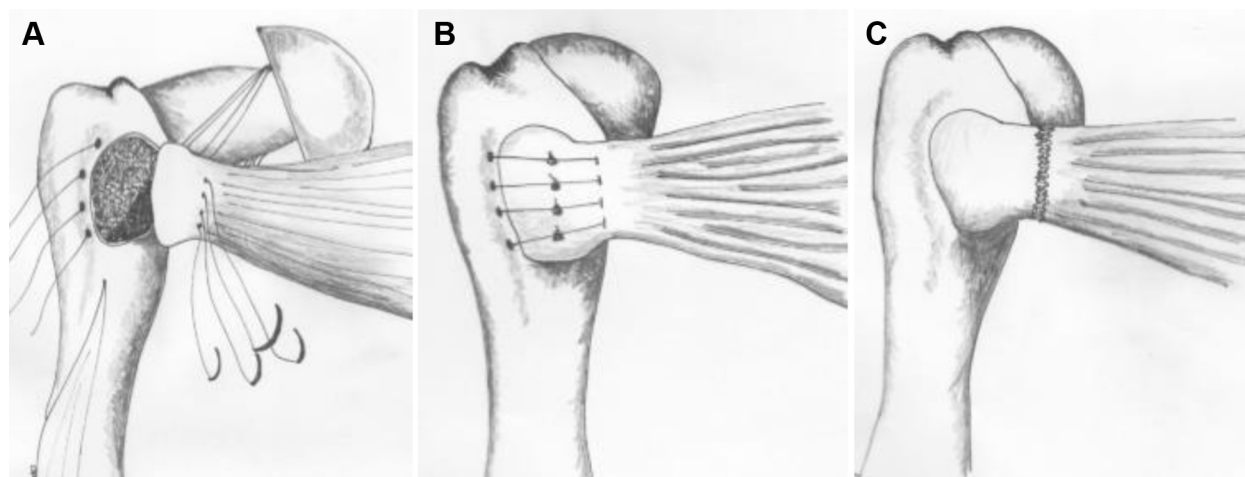
At this point, the techniques for addressing the glenoid for the various anatomic arthroplasty variations diverge depending on the pathology being treated. In a hemiarthroplasty for avascular necrosis of the humeral head without glenoid-sided chondral changes, the labrum and glenoid cartilage will be preserved, and the surgeon will proceed to placement of the final humeral implant, followed by closure. For a hemiarthroplasty with glenoid reaming, careful reaming to reshape and restore a uniformly smooth and concave (concentric) glenoid cavity is the next step. For ATSA, the labrum will be excised circumferentially, the glenoid will be carefully reamed and prepared to accept the glenoid implant, and the final glenoid implant placed.<sup>55</sup>

A trial humeral head is then placed and the humerus is critically assessed. Important factors to evaluate are soft tissue tension, particularly of the proposed SSc repair, joint stability, and ROM. The 40-50-60 rule is a popular intraoperative test<sup>45</sup> in which the SSc should reach its repair site with the humerus in 40° of external rotation (and 0° of abduction), the humerus should have 50% posterior translation, and 60° of internal rotation with the arm in 90° of scaption. Inability to reach these numbers indicates either inadequate soft tissue releases or an overstuffed prosthetic joint.

The final implant is inserted and the critically important SSc is repaired. The surgeon should check for the "subscapularis safe zone" during external rotation (ER), which is defined as the amount of ER achieved in the surgery without strain across the SSc repair.<sup>56</sup> The surgeon should communicate this ROM to rehabilitation specialists to allow safe mobilization in ER without jeopardizing the SSc repair during the early postoperative period. A sling is typically placed on the patient in the operating room, prior to the patient's emergence from anesthesia.

## Pre-habilitation and education before surgery

A "pre-habilitation" session in which the patient meets with a therapist or physician's assistant prior to surgery has



**Figure 1** Three methods of subscapularis takedown: (A) lesser tuberosity osteotomy, (B) subscapularis peel, and (C) subscapularis tenotomy. (Reprinted with permission from the *Journal of Shoulder and Elbow Arthroplasty*; Dunn et al.<sup>15</sup>).

been recommended to educate patients in postoperative exercise and activities of daily living (ADL) instruction.<sup>64</sup> Patients may also benefit from an explanation of the surgical procedure as it relates to postoperative precautions, namely, protection of the SSc. Additional preoperative education topics can include planning for assistance in the postoperative period, modifying the home environment to remove obstacles, utilizing appropriate nutritional intake and smoking cessation to facilitate optimal healing, and postoperative pain management. Although studies are lacking in ATSA patients, preoperative classes addressing patient recovery have modified preoperative expectations in patients with hip and knee arthroplasty.<sup>44</sup> Patient expectations preoperatively have been linked to patient satisfaction and better outcomes postoperatively in the hip, knee, and shoulder arthroplasty populations.<sup>43,50,65,66</sup> Research is needed to determine the potential benefit of pre-habilitation and education prior to ATSA on postoperative outcomes.

### Protection of the healing structures in the immediate postoperative recovery

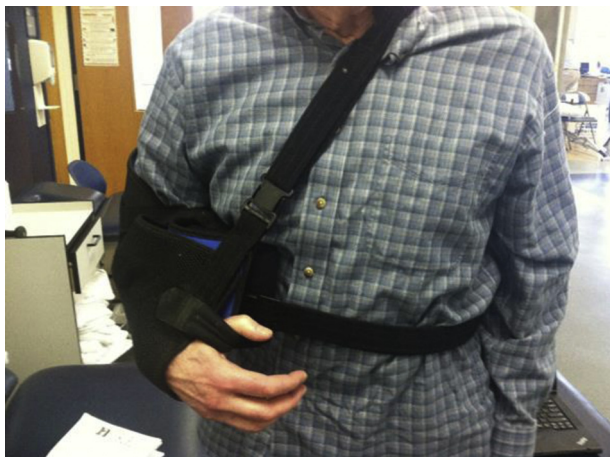Subscapularis dysfunction after ATSA results in higher level of pain, instability, and lack of maximal active internal rotation (IR)<sup>3,27,30</sup>; therefore, protection of the healing SSc must be a primary objective during the postoperative healing stage of recovery. There are 3 different SSc detachment techniques, and each is characterized by different tissue-healing mechanisms: (1) SSc tenotomy; (2) tendon-to-tendon, SSc peel, tendon-to-bone; and (3) lesser tuberosity osteotomy (LTO), bone-to-bone (Fig. 1).<sup>15</sup> Excellent results have been demonstrated with all of the most popular methods of managing the SSc during shoulder arthroplasty<sup>60</sup>; however, there is active debate regarding the relative merits of each technique.<sup>1,36,37,39</sup> The optimal

method of protecting the SSc in the early healing phase following surgery with respect to rehabilitation is unclear and has not been systematically studied.

Although some cadaveric biomechanical studies report that bone-to-bone repair is stronger compared to tendon-to-tendon or tendon-to-bone repairs, others failed to find significant differences between repairs.<sup>6,23,57,67</sup> Randomized clinical trials and a systematic review of the literature in live cohort studies have shown that the type of SSc management does not influence postoperative outcomes,<sup>12,37,39,56</sup> although the SSc healing rate is higher after osteotomy compared with that after tenotomy.<sup>12,39,56</sup> Considering the absence of a clear clinical advantage of one detachment/repair technique, it is likely that rehabilitation specialists will encounter each of these techniques in clinical practice.

A pilot study showed that the SSc tendon-to-bone interface of healthy cadaveric shoulder fails at approximately 700 N.<sup>23</sup> After tenotomy or osteotomy, the load to failure of cadaveric SSc decreased to 350 and 443 N, respectively. A higher failure rate was reported for tendon-to-bone repairs (67%) compared with tendon-to-tendon (16%) and bone-to-bone (0%) when cyclic loads of 150 N were applied to cadaveric specimens of surgically managed SSc. This study suggests that the LTO construct may allow progression of SSc stretching and strengthening better than the SSc tenotomy or peel methods of detachment. Computational biomechanical models predicted that the SSc exerts up to 283 N during abduction and adduction tasks. Therefore, in the early postoperative phase, even simple tasks such as unweighted abduction and adduction may generate forces that may exceed the failing load of surgically managed SSc.

The long head of the biceps is often cut and attached with soft tissue tenodesis to the pectoralis major as a routine procedure during ATSA. There is a dearth of research regarding rehabilitation guidelines specific to this



**Figure 2** Sling with abduction pillow.

procedure. Following supra-pectoral and subpectoral biceps tenodesis, resisted elbow flexion and supination are avoided for the first 6 weeks following surgery.<sup>33,40</sup>

### Appropriate Management of the Immobilization Period

Protection of the SSc in the early phase of healing after ATSA is facilitated through use of a sling or shoulder immobilizer. Better ER and adduction motion up to 1 year following ATSA, as well as lower night pain at 2 weeks postoperatively have been demonstrated when using a neutral rotation sling with an abduction pillow wedge vs. a traditional IR sling (Fig. 2).<sup>5</sup> The healing SSc is also protected by limiting active contraction of the muscle to prevent muscular force pulling across the tendon healing site, as well as limiting passive tension through stretch across the tendon. Rehabilitation is only safe when the strength of the postoperative repair or healing tissue is significantly greater than the stress imposed by rehabilitation strategies.<sup>19</sup> There is a delicate balance between obtaining and maintaining ROM gains obtained in surgery with the need for soft tissue healing. Overly protective rehabilitation may result in stiffness, whereas overly aggressive rehabilitation may compromise SSc healing and lead to decreased shoulder stability and function.<sup>8</sup> Potentially injurious forces can be avoided by slowly progressing staged ROM goals, controlling submaximal loading forces by limiting repetitive activity, and avoiding forces that may overstress the structural integrity of the repair.<sup>19</sup>

Although literature supports the introduction of passive ROM in the early healing phase following ATSA,<sup>8,11,17</sup> a consensus of definitive parameters is lacking. Rehabilitation specialists should select exercises that demonstrate less than 15% maximum voluntary isometric contraction on electromyography for the SSc as this guideline has been proposed as a safe level of activation following rotator cuff

repair.<sup>68</sup> Some studies limit passive forward elevation to 90°, whereas others allow passive ROM flexion to gradually increase as tolerated or “within the limits of stability and soft tissue tension determined intra-operatively.”<sup>3,8,11</sup> The SSc has been shown to retain its native level of passive tension with flexion or scaption in cadaveric studies following ATSA with variable humeral head component size,<sup>71</sup> though cadaveric studies do not reflect the pain and swelling present in a postoperative patient.

The amount of ER allowed immediately following ATSA is challenging to elucidate and may be patient-specific. Collaboration between the surgeon, rehabilitation specialist, and the patient is advised for understanding the SSc takedown method and safe-zone during surgery. The surgeon should communicate clearly regarding how much ER can be allowed. Some patients have excessive SSc shortening and ER deficiency prior to surgery, thus the tendon may be under tension to a greater degree than other patients who are not as stiff preoperatively. Surgeons often release the SSc tendon during the procedure and convention allows for immediate passive ER with the arm at the side; however there is much variation in the literature reporting end ranges from 0°–40°.<sup>3,11,17</sup> External rotation at 90° abduction, extension, and isolated abduction are not indicated in the early healing phase following ATSA because of excessive passive tension on the healing tendon with these motions.<sup>3</sup> Active contraction of the SSc through isometric contraction, ADL that involve resisted IR, or activities such as placing the hand behind the back or the hand behind the head are also contraindicated.

The optimal timing and setting of therapy are also unclear. One randomized controlled trial comparing immediate to 4-week delayed therapy following LTO for ATSA revealed better SSc healing rates by radiographic assessment at 6 months for the delayed therapy group, but overall no difference in patient outcomes.<sup>13</sup> A retrospective comparison of formal physical therapy compared to a simple home program found that the home group had better outcomes for flexion and abduction ROM and 36-Item Short Form Health Survey physical component scores at final follow-up.<sup>47</sup> The therapy programs in this study were not equivalent—the formal therapy plan involved closed-chain quadruped activity and IR isometrics early in the rehabilitation (after 4 weeks), which likely contributed to poorer patient outcomes by compromising the healing SSc repair. The home program employed use of pendulum exercises alone for the first 8 weeks after surgery followed by progression of motion and function as tolerated, and the end points for assessment of outcome were different between groups.

### Gradual loading to the healing tissues

After the early healing phase, passive ROM toward maximum mobility, active ROM, and strengthening

exercises are gradually introduced in the plan of care. Similar to other guidelines for rehabilitation following shoulder surgeries, a staged approach to recover mobility and strength is advised.<sup>19,68</sup> This approach maximizes the loads necessary for healing while protecting the repaired structures from repetitive activity and dangerous forces. Progressive tissue loading is influenced by many factors, including surgical management of the SSc, additional repaired tendon of the rotator cuff, preoperative diagnosis, patients' characteristics, and presence of comorbidities that impact bone and tendon healing.

A strong bone-to-bone interface for the LTO takedown method of SSc should be present by postoperative week 6, and an advantage of this procedure may be the ability to assess healing on radiographs. The absence of soft tissue attrition to the SSc with the LTO procedure may allow for a faster progression of ROM and strengthening exercises. Surgical reduction of the subperiosteal release of the SSc tendon with the SSc peel method generates a tendon-to-bone healing interface similar to a rotator cuff repair. Animal models of repaired rotator cuff tendon have shown that the repair strength is approximately 19%-30% of normal at 6 weeks with disorganized scar formation, and 29%-50% of normal at 12 weeks.<sup>20</sup> Sharpey fibers that bind the tendon to the bone appear in considerable number only after 12 weeks, and the bone-to-tendon junction is almost mature at 15 weeks.<sup>63</sup> Tendon-to-tendon healing as in the ST method is characterized by a remodeling phase at 6 weeks. The tissue at the site of repair changes from cellular to fibrous, and type 1 collagen is synthesized. This process continues up to 10 weeks; afterwards, the tissue at the repair site gradually changes from fibrous tissue to scarlike tendon tissue over the course of 1 year.<sup>59</sup> Patient characteristics that influence healing and progression of load include age, smoking, comorbidities (osteoporosis, diabetes, obesity, vascular diseases, impaired metabolism), and medications (corticosteroids, immunosuppressants), which all can negatively impact the healing process. These concomitant factors should be taken into account when progressing ROM and strengthening exercises.

## ASSET consensus rehabilitation guidelines

Two American Society of Shoulder and Elbow Therapists (ASSET) members developed 2 surveys regarding practice patterns for rehabilitation after ATSA: one survey for ASSET members and one survey for the American Shoulder and Elbow Surgeons (ASES) members. An ASSET member with extensive research experience provided feedback regarding the survey question design and content. Each draft of the survey was further reviewed by 5 members in the respective professional group. Feedback from each member was used to revise each survey. The final version of the ASSET survey included 37 questions regarding specific exercises, activities, and ROM allowed at

each stage of recovery. The final version of the ASES survey included 10 questions regarding practice patterns, including the use of a sling or shoulder immobilizer after ATSA as well as preferences regarding ROM limits in phase 1 and 2 of recovery after surgery. These surveys were e-mailed to entire membership of the ASSET and ASES. The response rate was 34% (37/110) from ASSET and 15% (120/810) from ASES. A consensus in survey response to inform the rehabilitation guideline was established a priori as 67% agreement as recommended in a Delphi consensus method.<sup>46</sup> Survey questions and responses for ASES and ASSET are summarized in [Tables I and II](#). The development of the proposed consensus rehabilitation guidelines for ATSA included integration of the ASSET and ASES survey responses and literature review regarding the healing time frames for implicated tissues (joint capsule, SSc, and biceps tendon). Proposed consensus rehabilitation guidelines were presented and discussed at the 2019 ASSET annual conference. Detailed rehabilitation guidelines following ATSA are provided in [Table III](#).

Rehabilitation is divided into 3 phases of 6-week intervals based on healing time frames and survey responses. The proposed rehabilitation guidelines should be implemented with input from surgeons to ensure that the recommended parameters are in alignment with surgeon preferences, and with consideration of patient-specific variables. Progression through rehabilitation phases should be based both on healing time frames as well as patients achieving milestones for each phase. The use of validated patient-reported outcome measures is advised. Measures often cited in shoulder arthroplasty research include the Disabilities of the Arm, Shoulder, and Hand questionnaire (DASH), QuickDASH, Shoulder Pain and Disability Index, PENN Shoulder Score, the Patient-Reported Outcomes Measurement Information System (PROMIS), or the ASES Standardized Shoulder Assessment Form score. Pain level should be assessed routinely using the 0-10 numeric pain rating scale or visual analog scale. Glenohumeral joint passive and active ROM and upper-quarter strength should be measured at appropriate stages of recovery, and examination components are detailed in the rehabilitation guidelines ([Table I](#)). A qualitative assessment of the patient's shoulder biomechanics should be integrated into assessment during the active phase of recovery.

### Phase 1: postoperative week 0-6

Phase 1 begins on postoperative day 1 and progresses through the end of the sixth postoperative week. During this early healing phase of recovery, the hierarchy of need is protection of the SSc, which was mobilized for access to the glenohumeral joint and then repaired. ASES surveys regarding sling use reveal lack of consensus, though the majority of surgeons prefer using a sling or shoulder

**Table I** Practice pattern survey results for the American Society of Shoulder and Elbow Therapists

	Phase 1 (POD 1-POW6)	Phase 2 (POW 6-12)	Phase 3 (POW 12+)
Sling	No sling: 5% 2 weeks: 22% 4 weeks: 59% 6 weeks: 24%	No respondent used a sling beyond 6 weeks	No sling
Elevation	120° passive Not allowed active	As tolerated passive and active	No limit passive and active
External rotation in 0° abduction	30° passive or active	60° passive and active	No limit passive and active
External rotation in 90° abduction	Not allowed active or passive	60° passive and active	No limit passive and active
Internal rotation	Hand to abdomen	Hand to posterior hip	No limit but advance gradually

POD, postoperative day; POW, postoperative week.

All numbers represent degrees of glenohumeral range of motion that reached at least 67% consensus among 37 responders.

**Table II** Practice pattern survey results for the American Shoulder and Elbow Surgeons

	Phase 1 (POD 1-POW 6)	Phase 2 (POW 6-12)	Phase 3 (POW 12+)
Sling	LTO: 33% 4 weeks; 39% 6 weeks ST: 16% 2 weeks; 24% 4 weeks; 41% 6 weeks SP: 17% 2 weeks; 14% 4 weeks; 45% 6 weeks	No respondent used a sling beyond 6 weeks	No sling
Elevation	130° passive: LTO 120° passive: ST 90° passive: SP Not allowed active	As tolerated passive and active	No limit passive and active
External rotation in 0° abduction	30°: LTO 20°: ST and SP Active vs. passive not specified	No limit: LTO 60° passive and active: ST and SP	No limit passive and active
Internal rotation	Hand to trochanter	No limit	No limit but advance gradually

POD, postoperative day; POW, postoperative week; LTO, lesser tuberosity osteotomy; ST, subscapularis tenotomy; SP, subscapular peel.

All numbers represent degrees of glenohumeral range of motion, which reached at least 67% consensus among 120 responders. LTO: 51/120; ST: 37/120; SP: 29/120.

Three responders did not specify method of subscapularis takedown.

immobilizer for 4-6 weeks. ASSET recommends using a sling with abduction pillow for 4-6 weeks in collaboration with the referring surgeon. If the sling is removed at home, the elbow should be kept at the side, the upper extremity used for only the most basic ADL, and the limits for ER observed at all times. Using the sling at night during sleep is advisable to prevent unwarranted ROM during phase 1.

There is a dearth of research that assesses the varied methods of SSc takedown as it relates to the timing and degree of mobilization after shoulder arthroplasty, though there is agreement that ER should be limited and IR and extension behind the back avoided during this early phase of healing. ASES surgeons reached consensus that ER to 30° is safe for patients who have had LTO, whereas those who perform SSc tenotomy or peel prefer a slower approach limiting external rotation to 20°. This practice pattern reflects the research that in spite of no differences in overall patient outcomes, the LTO procedure is a stronger

construct because of bone-to-bone fixation and may tolerate earlier mobility. ASSET member survey results reveal that the majority allow external rotation to 30° during phase 1, though the method of surgical SSc takedown was not differentiated in the survey. The ASSET consensus statement recommends a maximum of 30° with the arm at the side for the LTO procedure, with a slower approach for the SSc tenotomy and peel procedures, and no ER in the 90° of abduction position during phase 1. Rehabilitation specialists should confer with referring surgeons to determine the "safe zone" of ER observed in the operating room to ensure that the 30° limit is appropriate for the patient. Surgeons may choose the operative determined safe zone ROM in lieu of consensus mobility recommendations. External rotation ROM should be performed with the arm supported in the plane of the scapula (approximately 30° anterior the frontal plane) as the humeral head is centered on the glenoid in this plane, thereby reducing the strain to

**Table III** The American Society of Shoulder and Elbow Therapists' rehabilitation guidelines for anatomic shoulder arthroplasty

Phase	Precautions and guidelines	Goals	Exercises	Criteria to advance to next phase	Examination
1 (POD 1 to POW 4-6)	<p>Sling 24/7 (remove for grooming and home exercise program 3-5 times a day)</p> <p>Avoid hand behind the back and ER at 90°</p> <p>No shoulder active elevation</p> <p>No submersion in water until after 4 weeks</p> <p>No weight bearing on shoulder</p>	<p>Protect healing subscapularis, joint capsule, and biceps tenodesis</p> <p>Prevent infection</p> <p>Promote distal circulation and control swelling</p> <p>Proper sling fit</p> <p>PROM: 120° elevation and 30° ER (unless other specified limit by surgeon)</p>	<p>Pendulum</p> <p>Active elbow, wrist and hand, scapular retraction</p> <p>Passive elevation to 120° in scapular plane (eg, rope and pulley, table slide, supine well arm assisted)</p> <p>ER to 30° in scapular plane with arm at side (eg, well arm or dowel assisted, or table supported and rotate away [Fig. 2])</p> <p>Nonimpact aerobic activities: walking; stationary bike when incision is healed</p>	<p>Pain less than 3/10 with PROM</p> <p>Healing incision without signs of infection</p> <p>Clearance by surgeon after radiograph assessment at postoperative visit</p>	<p>Wound assessment</p> <p>Swelling assessment of upper extremity</p> <p>Neurovascular assessment of upper extremity</p> <p>Sling fit and ability to don/doff properly</p> <p>Patient-reported outcome measure</p> <p>Pain level</p> <p>ROM for elevation (passive only) and ER (passive and active) in range of motion constraints (0-30)</p>
2 (POW 4-6 to 12)	<p>Discontinue sling at the end of POW 4-6 (surgeon preference)</p> <p>Motion recovery without excessive force</p> <p>May begin ER at 90° of abduction in scapular plane to 60° limit</p> <p>May begin functional IR with hand behind back gently</p> <p>Weight-bearing on the UE for use of assistive device allowed</p> <p>No closed-chain exercise</p> <p>Advance arm use in ADL gradually</p>	<p>Optimize PROM</p> <p>Develop AROM to equal PROM</p> <p>Establish dynamic stability of shoulder with deltoid, rotator cuff, and periscapular strengthening through AROM against gravity</p>	<p>Stretching beyond precautionary limits in phase 1 for elevation and ER(0) without excessive force</p> <p>Begin ER(90) to 60° limit in scapular plane</p> <p>Active forward elevation progression when passive motion restored to expected level: supine with gradual incline to vertical, short to long lever arm (bent to straight elbow)</p> <p>Active ER/IR with arm at side sitting to sidelying</p> <p>Scapular AROM against gravity (eg prone extension to hip with scapular retraction/depression; prone</p>	<p>AROM against gravity equals PROM</p> <p>No pain</p> <p>Need higher-level demand than ADL functions (eg, sport or work)</p>	<p>AROM shoulder elevation, ER(0), and functional IR (highest spinal level achieved with thumb behind back without overpressure)</p> <p>PROM shoulder elevation, ER(0), ER(90) up to 60°, and IR(90)</p> <p>Patient-reported outcome measure</p> <p>Pain level</p>

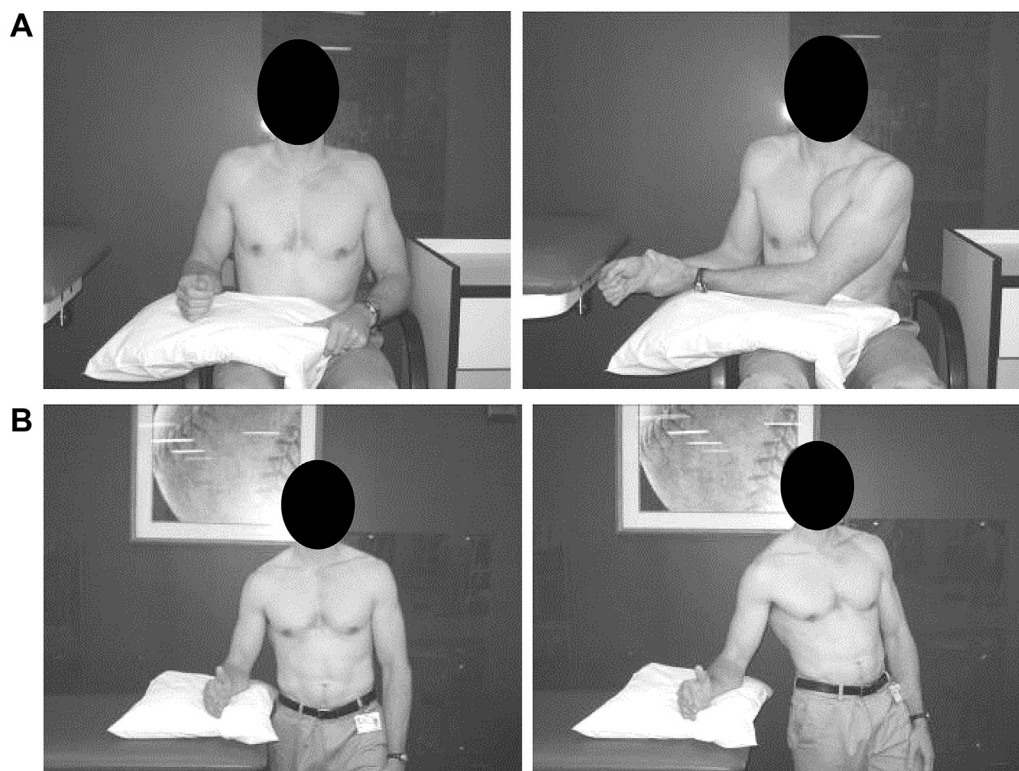*(continued on next page)*

**Table III** The American Society of Shoulder and Elbow Therapists' rehabilitation guidelines for anatomic shoulder arthroplasty (continued)

Phase	Precautions and guidelines	Goals	Exercises	Criteria to advance to next phase	Examination
3 (POW 12+)	<p>May begin to add resistance to shoulder—low loading with more repetition advised</p> <p>Keep weight training below shoulder level and anterior to the frontal plane</p> <p>Closed-chain exercises such as planks and yoga</p> <p>Gradual return to sport; advanced upper extremity sport such as golf/tennis initiated at 4 mo, and full return not prior to 6 mo</p> <p>Avoid impact loading such as sledgehammer, wood chopping, bench pressing</p>	<p>Achieve functional demands for work and/or sport</p> <p>Gradual increase in deltoid and periscapular muscle strength</p> <p>Maintain functional mobility of shoulder</p> <p>Pain-free use of shoulder in ADL, work, and sport</p>	<p>horizontal abduction to neutral)</p> <p>IR behind back gently allowed</p> <p>Aerobic activities: walking; elliptical without UE resistance, stationary bicycle; lower body weight training</p> <p>Gentle end range stretching especially in forward elevation as part of a daily lifelong routine</p> <p>Deltoid, rotator cuff, scapular muscle and other upper body strengthening with light resistance (free weights, elastic bands, or gym machines) keeping weight below shoulder level and anterior to the frontal plane</p> <p>Biceps strengthening with weighted elbow flexion</p> <p>Functional sports-specific training considering total body (eg, core, endurance)</p> <p>Aerobic activities: walking, stationary bicycle, elliptical, jogging, swimming when strength is normalized in rotator cuff and scapular stabilizers</p>	NA	<p>PROM for elevation, ER(0); ER(90); IR(90)</p> <p>AROM for elevation, ER(0) and functional IR</p> <p>Scapulohumeral rhythm/biomechanics of active movement strategies</p> <p>Strength testing for deltoid, rotator cuff, scapular muscles</p> <p>Sports-specific analysis (eg, trunk and hip rotation for golf)</p> <p>Patient-reported outcome measure</p> <p>Pain</p>

POD, postoperative day; POW, postoperative week; ER, external rotation; IR, internal rotation; UE, upper extremity; ADL, activities of daily living; PROM, passive range of motion; AROM, active range of motion; NA, not applicable; ROM, range of motion.





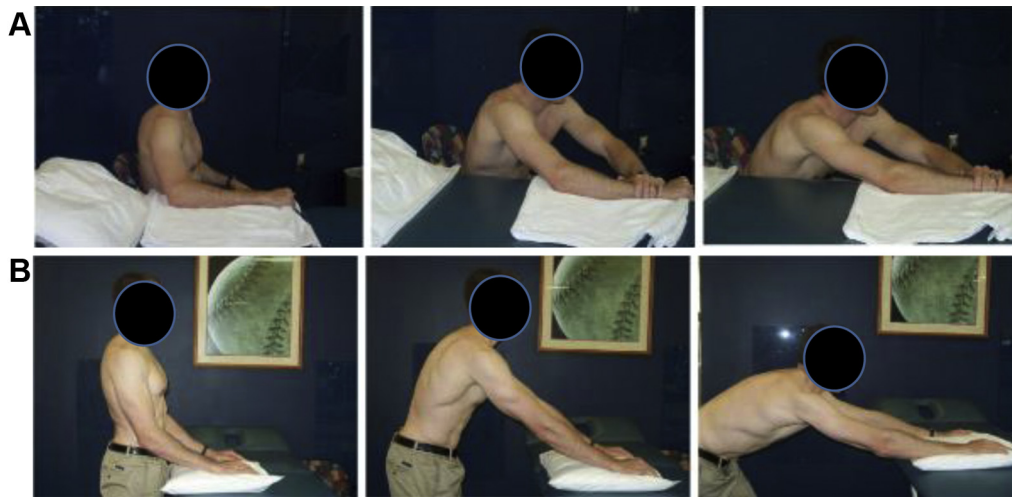**Figure 3** Passive methods for external rotation to 30° in phase 1 of rehabilitation: (A) assisted with the well arm and (B) by supported step-around.

the healing anterior joint capsule and SSc.<sup>4,7</sup> Methods of performing ER include well arm- or dowel-assisted motion in the seated or supine position, or resting the arm on a supportive surface such as a table or countertop and turning the torso slightly away (Fig. 2). The table step-around ER exercise illustrated in Figure 3 lessens inadvertent patient guarding or contraction of the SSc muscle during dowel-assisted ROM. The ASSET panel of experts agree that supine exercises soon after ATSA are challenging for patients because of the following reasons: (1) if the arm is not well supported in the plane of the scapula, there may be painful strain across the healing incision, anterior joint capsule, and SSc; (2) many patients are challenged with getting into and out of a supine position without weight bearing on the surgical arm; and (3) finding a place to sit to do ROM is likely more convenient than lying supine and may foster increased compliance with home exercises.

Consensus for passive elevation in phase 1 on the ASES survey was 130°, 120°, and 90° for LTO, SSc tenotomy, and SSc peel, respectively. The ASSET practice pattern survey reached consensus at allowing 120° of elevation without differentiation of SSc takedown method. As cadaveric research has demonstrated no strain on the SSc during elevation following arthroplasty,<sup>71</sup> the ASSET recommendation for elevation in phase 1 allows passive motion to 120° while stressing the importance of avoiding undue force or overpressure. Isolated glenohumeral motion with

scapular blocking should be avoided at this stage of recovery so that scapulohumeral rhythm can occur naturally, thereby avoiding strain on the healing SSc tendon. Methods of performing passive elevation that have demonstrated acceptably low SSc electromyographic activity of less than 15% maximum voluntary contraction include rope and pulley in a seated position, table slide, or step back (Fig. 4), and supine well arm-assisted elevation, whereas supine dowel-assisted elevation was found to be higher than this recommended level (24%).<sup>16</sup> Seated table-supported or rope-and-pulley exercises may be better selections for patients with mobility and/or balance challenges. Supine exercises may be challenging for patients if the “well arm” has glenohumeral osteoarthritis, rotator cuff pathology, pain, or limited mobility for other reasons.

Active elbow flexion and extension through full ROM is permitted as a phase 1 exercise so that the healing biceps tenodesis retains full mobility. The short head of the biceps and the brachialis muscles load share this motion; therefore, active elbow flexion will not jeopardize the healing biceps tenodesis, though heavy resistance should be avoided for 12 weeks per ASES survey consensus. Wrist and hand active ROM should be performed for circulatory benefits to prevent distal swelling in the operative upper extremity, and active scapular retraction should be initiated to optimize glenoid posture and overcome the uncomfortable static position of resting



**Figure 4** Passive elevation with (A) table slide and (B) table step back.

in a sling. Gentle Codman pendulum exercises are promoted in this phase as a method of shoulder muscle relaxation, joint fluid circulation, and improving passive ROM in elevation.

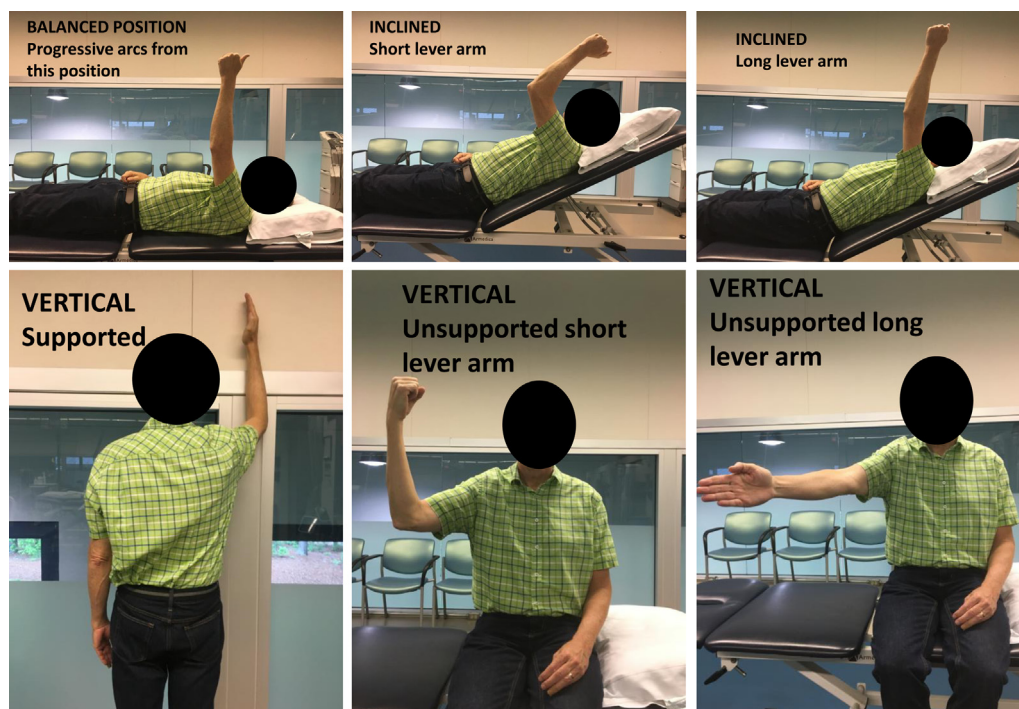
Patient education regarding the ROM limits for ER and elevation is imperative as well as activity guidelines restricting active elevation, resisted IR with ADL, weight bearing through the postoperative upper extremity, and lifting of weighted objects. ER with the arm at the side within the specified limited arc of motion can be active or passive as the posterior rotator cuff is not compromised during surgery. Absolute precautions include avoiding ER beyond the safe zone observed intraoperatively, ER ROM at 90° of abduction as this maximizes SSc strain, and functional IR by placing the hand behind the back. ASES and ASSET practice pattern surveys reached consensus for allowing the hand only to the greater trochanter during phase 1.

## Phase 2: postoperative week 7-12

Phase 2 of rehabilitation spans the beginning of 7 through the end of 12 weeks, and the primary goal during this time period is to gradually restore mobility. ROM exercises should be gentle passive stretches beyond the phase 1 precautionary range limits followed by a progression to active assisted and then active ROM as expected mobility is achieved. Expected ROM varies based on the preoperative diagnosis for ATSA. Patients who undergo ATSA for osteoarthritis have the most favorable outcomes and may reach approximately 140°-150° of scapular plane elevation, 50°-60° of ER with the arm at the side, and IR to the upper lumbar spine.<sup>34</sup> In contrast, ROM expectations are lower if ATSA is performed for rheumatoid arthritis, post-traumatic arthritis, or dislocation arthropathy.<sup>69</sup> With these differences in expected outcome in mind, rehabilitation specialists should try to achieve ROM goals by 12 weeks while the

healing joint capsule and SSc tendon are pliable, though avoidance of excess overpressure to achieve ROM is still important.

The Jackins active elevation progression is recommended once mobility is restored.<sup>29</sup> This progression involves having patients first control the weight of the arm at 90° of elevation in the supine position, and then actively move through increasing arcs of shoulder elevation from this balanced position. Figure 5 illustrates the progression: when the patient is able to control the full arc of elevation in supine, the head of the bed is gradually inclined to more vertical positions initially with a bent elbow to provide a shorter lever arm to the shoulder. Progression from supine to more upright gravity resisted positioning, and short to long lever arm (bent to straight elbow) has been shown to progress electromyography activation in the rotator cuff and deltoid muscles.<sup>18,70</sup> ASES and ASSET experts reached consensus that stretching ER with the arm at the side can progress safely up to 60°, and stretching ER in increasing angles of scapular plane abduction up to 90° is allowed during phase 2 though should not exceed 60° in order to protect against excessive SSc strain. ASES surveys reveal that the majority of surgeons allow IR behind the back gradually at this stage of recovery, whereas ASSET surveys exhibit more caution, with the majority agreeing to limit motion to the sacrum. All of the practitioners agree that motion for functional IR up the spine should progress gently and gradually. Because of the healing capsule, joint mobilization should only be used for pain modulation if needed, and in the event of true stiffness unresponsive to gentle stretching. ASSET consensus is that closed-chain exercises both in weight-bearing and non-weight-bearing positions are not indicated in phase 2; however, active ROM against gravity with the weight of the arm as resistance is allowed for deltoid, rotator cuff, and scapular muscle activation.



**Figure 5** Elevation progression: Patient progresses from the “balanced position” of holding the weight of the arm at 90° in supine, through progressive arcs of active range of motion in supine, then inclined, then upright. On each progression, the elbow is initially bent for a short lever arm, and then straightened for a long lever arm load.

### Phase 3: postoperative week 12 +

Phase 3 of rehabilitation begins at 12 weeks following surgery. Consideration regarding insurance restrictions for rehabilitation services should be factored into the patient plan of care. For many patients with low activity goals, this phase of recovery will be a recommendation to continue gentle stretching for life if individual goals have been met. Patients with higher-level goals will benefit from continued strengthening, which includes rotator cuff, deltoid, and scapular stabilizer muscles, with advanced return to sport initiated after postoperative month 4.<sup>9</sup>

ASES and ASSET surveys reached consensus that at this stage of recovery patients may stretch in all planes without ROM precautions and restore motion as tolerated, striving to attain mobility aligned with patient goals. ROM and functional gains largely occur by 6 months, though strength will continue to develop up to 2 years following shoulder arthroplasty.<sup>54</sup> Surgeon recommendations on return to sports after ATSA varies moderately.<sup>25,42</sup> Swimming, golf, cycling, and general fitness training are the most common activities enjoyed by patients following ATSA, and 89% are involved in some form of sports at an average of 2.8 years following surgery.<sup>58</sup> Strengthening exercises may progress gradually using light hand weights and/or elastic band resistance. Return to weight training is allowed with a recommendation to keep weights anterior to the frontal

plane and below shoulder level, with use of lighter weights and higher repetitions. The majority of rehabilitation specialists surveyed indicated that at this time closed chain activities are permitted, including planks, yoga, and quadruped exercises. A gradual return to prior activity level such as golf, tennis, and swimming is allowed, with full return to play restricted until postoperative month 6 to allow for mature SSc healing. An example of graded return to activity is to allow chipping and putting for golf at 4 months, with return to full swing at 6 months. There is a lack of consensus regarding maximum weight lifting limits following ATSA with 15 lb (11%) and 25 lb (28%) advised by ASSET survey responders. There was consensus that heavy impact loading with bench press, wood chopping, or use of a sledgehammer is not advised.

### Future directions

Prosthetic components used in shoulder arthroplasty are being developed that may impact rehabilitation decision making. An example of an innovative component with rising utility is the stemless humeral head, which may alter SSc fixation methods and require a different rehabilitation approach. The convertible humeral prosthesis (from anatomic to reverse) is another recent prosthetic option, and the impact of this device on index procedure vs.

arthroplasty revision should be researched regarding rehabilitation decision making.

## Conclusion

ATSA is a surgical procedure with reliable results for end-stage glenohumeral osteoarthritis, and rehabilitation following this procedure should prioritize optimizing healing of the SSc repair, followed by slow passive and active motion recovery. Communication with the surgeon regarding the method of SSc takedown and the ER safe zone can provide guidance to the rehabilitation specialist.

## Acknowledgments

The authors gratefully acknowledge the following contributors to this consensus statement: Sarah E. Jackins, PT: manuscript content; Todd Peterson, ATC, PTA, CSCS: ASES survey development and analysis; Lori Michener, PT, ATC, PhD, FAPTA: project process and survey review; Tanya Beiswenger, PT, SCS, ATC, Lindsey Colbert, PT, DPT, Arlette Frederick, PT, DPT, MS, OCS, Michael Glindmeyer, DPT, SCS, ATC, and Jake Landes, PT, DPT, SCS: literature review; Rebecca Dickinson, PT, DPT, and Lee Rosenzweig, PT, DPT: manuscript review.

## Disclaimer

Federico Pozzi, PT, MA, PhD, received salary support to complete this work from the Career Development Award sponsored by the Academy of Orthopaedic Physical Therapy and the Rehabilitation Research Center Development Program sponsored by the National Institute of Health (K12 HD055929). The outside funding sources were not involved in the data analysis, preparation, and/or editing of this manuscript. No other source of funding was applied to this project.

The other authors, their immediate families, and any research foundations with which they are affiliated have not received any financial payments or other benefits from any commercial entity related to the subject of this article.

## References

- Aibinder WR, Bicknell RT, Bartsch S, Scheibel M, Athwal GS. Subscapularis management in stemless total shoulder arthroplasty: tenotomy versus peel versus lesser tuberosity osteotomy. *J Shoulder Elbow Surg* 2019;28:1942-7. <https://doi.org/10.1016/j.jse.2019.02.022>
- Amirthanayagam TD, Amis AA, Reilly P, Emery RJH. Rotator cuff-sparing approaches for glenohumeral joint access: an anatomic feasibility study. *J Shoulder Elbow Surg* 2017;26:512-20. <https://doi.org/10.1016/j.jse.2016.08.011>
- Armstrong A, Lashgari C, Teeffey S, Menendez J, Yamaguchi K, Galatz LM. Ultrasound evaluation and clinical correlation of subscapularis repair after total shoulder arthroplasty. *J Shoulder Elbow Surg* 2006;15:541-8. <https://doi.org/10.1016/j.jse.2005.09.013>
- Basti J. Postoperative and nonoperative rehabilitation of proximal humerus fractures. In: Gaunt B, McCluskey G III, editors. *A systematic approach to shoulder rehabilitation*. Columbus, GA: Human Performance and Rehabilitation Centers, Inc.; 2012. p. 425.
- Baumgarten KM, Osborn R, Schweinle WE, Zens MJ. The position of sling immobilization influences the outcomes of anatomic total shoulder arthroplasty: a randomized, single-blind, prospective study. *J Shoulder Elbow Surg* 2018;27:2120-8. <https://doi.org/10.1016/j.jse.2018.08.030>
- Van den Berghe GR, Nguyen B, Patil S, D'Lima DD, Mahar A, Pedowitz R, et al. A biomechanical evaluation of three surgical techniques for subscapularis repair. *J Shoulder Elbow Surg* 2008;17:156-61. <https://doi.org/10.1016/j.jse.2007.04.016>
- Bigliani LU, Kelkar R, Flatow EL, Pollock RG, Mow VC. Glenohumeral stability. Biomechanical properties of passive and active stabilizers. *Clin Orthop Relat Res* 1996;13-30.
- Boardman ND, Cofield RH, Bengtson KA, Little R, Jones MC, Rowland CM. Rehabilitation after total shoulder arthroplasty. *J Arthroplasty* 2001;16:483-6.
- Brameier DT, Hirscht A, Kowalsky MS, Sethi PM. Rehabilitation strategies after shoulder arthroplasty in young and active patients. *Clin Sports Med* 2018;37:569-83. <https://doi.org/10.1016/j.csm.2018.05.007>
- Bullock GS, Garrigues GE, Ledbetter L, Kennedy J. A systematic review of proposed rehabilitation guidelines following anatomic and reverse shoulder arthroplasty. *J Orthop Sports Phys Ther* 2019;49:337-46. <https://doi.org/10.2519/jospt.2019.8616>
- Caplan JL, Whitfield B, Neviasser RJ. Subscapularis function after primary tendon to tendon repair in patients after replacement arthroplasty of the shoulder. *J Shoulder Elbow Surg* 2009;18:193-196. discussion 197. <https://doi.org/10.1016/j.jse.2008.10.019>
- Choate WS, Kwapisz A, Momaya AM, Hawkins RJ, Tokish JM. Outcomes for subscapularis management techniques in shoulder arthroplasty: a systematic review. *J Shoulder Elbow Surg* 2018;27:363-70. <https://doi.org/10.1016/j.jse.2017.08.003>
- Denard PJ, Lädermann A. Immediate versus delayed passive range of motion following total shoulder arthroplasty. *J Shoulder Elbow Surg* 2016;25:1918-24. <https://doi.org/10.1016/j.jse.2016.07.032>
- Ding DY, Mahure SA, Akuoko JA, Zuckerman JD, Kwon YW. Total shoulder arthroplasty using a subscapularis-sparing approach: a radiographic analysis. *J Shoulder Elbow Surg* 2015;24:831-7. <https://doi.org/10.1016/j.jse.2015.03.009>
- Dunn R, Joyce CD, Bravman JT. Comparison of subscapularis management and repair techniques. *J Shoulder Elbow Arthroplasty* 2019;3: <https://doi.org/10.1177/2471549219848152>
- Edwards PK, Ebert JR, Littlewood C, Ackland T, Wang A. A systematic review of electromyography studies in normal shoulders to inform postoperative rehabilitation following rotator cuff repair. *J Orthop Sports Phys Ther* 2017;47:931-44. <https://doi.org/10.2519/jospt.2017.7271>
- Foruria AM, Oh LS, Sperling JW, Cofield RH. Anteromedial approach for shoulder arthroplasty: current indications, complications, and results. *J Shoulder Elbow Surg* 2010;19:734-8. <https://doi.org/10.1016/j.jse.2009.10.016>
- Gaunt BW, McCluskey GM, Uhl TL. An electromyographic evaluation of subdividing active-assistive shoulder elevation exercises. *Sports Health* 2010;2:424-32. <https://doi.org/10.1177/1941738110366840>

19. Gaunt BW, Shaffer MA, Sauers EL, Michener LA, McCluskey GM, Thigpen C, et al. The American Society of Shoulder and Elbow Therapists' consensus rehabilitation guideline for arthroscopic anterior capsulolabral repair of the shoulder. *J Orthop Sports Phys Ther* 2010; 40:155-68. <https://doi.org/10.2519/jospt.2010.3186>
20. Gerber C, Schneeberger AG, Perren SM, Nyffeler RW. Experimental rotator cuff repair. A preliminary study. *J Bone Joint Surg Am* 1999; 81:1281-90.
21. Getz CL, Kearns KA, Padegimas EM, Johnston PS, Lazarus MD, Williams GR. Survivorship of hemiarthroplasty with concentric glenoid reaming for glenohumeral arthritis in young, active patients with a biconcave glenoid. *J Am Acad Orthop Surg* 2017;25:715-23. <https://doi.org/10.5435/JAAOS-D-16-00019>
22. Gilmer BB, Comstock BA, Jette JL, Warme WJ, Jackins SE, Matsen FA. The prognosis for improvement in comfort and function after the ream-and-run arthroplasty for glenohumeral arthritis: an analysis of 176 consecutive cases. *J Bone Joint Surg Am* 2012;94:e102. <https://doi.org/10.2106/JBJS.K.00486>
23. Giuseffi SA, Wongtriratanchai P, Omae H, Cil A, Zobitz ME, An KN, et al. Biomechanical comparison of lesser tuberosity osteotomy versus subscapularis tenotomy in total shoulder arthroplasty. *J Shoulder Elbow Surg* 2012;21:1087-95. <https://doi.org/10.1016/j.jse.2011.07.008>
24. Godenèche A, Boileau P, Favard L, Le Huec J-C, Lévine C, Nové-Josserand L, et al. Prosthetic replacement in the treatment of osteoarthritis of the shoulder: early results of 268 cases. *J Shoulder Elbow Surg* 2002;11:11-8. <https://doi.org/10.1067/mse.2002.120140>
25. Golant A, Christoforou D, Zuckerman JD, Kwon YW. Return to sports after shoulder arthroplasty: a survey of surgeons' preferences. *J Shoulder Elbow Surg* 2012;21:554-60. <https://doi.org/10.1016/j.jse.2010.11.021>
26. Hughes M, Neer CS. Glenohumeral joint replacement and post-operative rehabilitation. *Phys Ther* 1975;55:850-8.
27. Ives EP, Nazarian LN, Parker R, Garrigues GE, Williams GR. Subscapularis tendon tears: a common sonographic finding in symptomatic postarthroplasty shoulders. *J Clin Ultrasound* 2013;41:129-33. <https://doi.org/10.1002/jcu.21980>
28. Izquierdo R, Voloshin I, Edwards S, Freehill MQ, Stanwood W, Wiater JM, et al. Treatment of glenohumeral osteoarthritis. *J Am Acad Orthop Surg* 2010;18:375-82. <https://doi.org/10.5435/00124635-201006000-00010>
29. Jackins S. Postoperative shoulder rehabilitation. *Phys Med Rehabil Clin N Am* 2004;15:643-682. vi. <https://doi.org/10.1016/j.pmr.2004.01.002>
30. Jackson JD, Cil A, Smith J, Steinmann SP. Integrity and function of the subscapularis after total shoulder arthroplasty. *J Shoulder Elbow Surg* 2010;19:1085-90. <https://doi.org/10.1016/j.jse.2010.04.001>
31. Jerosch J, Greig M, Peuker ET, Filler TJ. The posterior subdeltoid approach: a modified access to the posterior glenohumeral joint. *J Shoulder Elbow Surg* 2001;10:265-8.
32. Jobin CM, Brown GD, Bahu MJ, Gardner TR, Bigliani LU, Levine WN, et al. Reverse total shoulder arthroplasty for cuff tear arthropathy: the clinical effect of deltoid lengthening and center of rotation medialization. *J Shoulder Elbow Surg* 2012;21:1269-77. <https://doi.org/10.1016/j.jse.2011.08.049>
33. Kahlenberg CA, Patel RM, Nair R, Deshmane PP, Harnden G, Terry MA. Clinical and biomechanical evaluation of an all-arthroscopic suprapectoral biceps tenodesis. *Orthop J Sports Med* 2014; 2:2325967114553558. <https://doi.org/10.1177/2325967114553558>
34. Kiet TK, Feeley BT, Naimark M, Gajju T, Hall SL, Chung TT, et al. Outcomes after shoulder replacement: comparison between reverse and anatomic total shoulder arthroplasty. *J Shoulder Elbow Surg* 2015; 24:179-85. <https://doi.org/10.1016/j.jse.2014.06.039>
35. Lafosse L, Schnaser E, Haag M, Gobezie R. Primary total shoulder arthroplasty performed entirely thru the rotator interval: technique and minimum two-year outcomes. *J Shoulder Elbow Surg* 2009;18:864-73. <https://doi.org/10.1016/j.jse.2009.03.017>
36. Lapner PLC, Sabri E, Rakhra K, Bell K, Athwal GS. Healing rates and subscapularis fatty infiltration after lesser tuberosity osteotomy versus subscapularis peel for exposure during shoulder arthroplasty. *J Shoulder Elbow Surg* 2013;22:396-402. <https://doi.org/10.1016/j.jse.2012.05.031>
37. Lapner PLC, Sabri E, Rakhra K, Bell K, Athwal GS. Comparison of lesser tuberosity osteotomy to subscapularis peel in shoulder arthroplasty: a randomized controlled trial. *J Bone Joint Surg Am* 2012;94: 2239-46. <https://doi.org/10.2106/JBJS.K.01365>
38. Levine WN, Djurasovic M, Glasson JM, Pollock RG, Flatow EL, Bigliani LU. Hemiarthroplasty for glenohumeral osteoarthritis: results correlated to degree of glenoid wear. *J Shoulder Elbow Surg* 1997;6: 449-54.
39. Levine WN, Munoz J, Hsu S, Byram IR, Bigliani LU, Ahmad CS, et al. Subscapularis tenotomy versus lesser tuberosity osteotomy during total shoulder arthroplasty for primary osteoarthritis: a prospective, randomized controlled trial. *J Shoulder Elbow Surg* 2019;28: 407-14. <https://doi.org/10.1016/j.jse.2018.11.057>
40. Liechti DJ, Mitchell JJ, Menge TJ, Hackett TR. Immediate physical therapy without postoperative restrictions following open subpectoral biceps tenodesis: low failure rates and improved outcomes at a minimum 2-year follow-up. *J Shoulder Elbow Surg* 2018;27:1891-7. <https://doi.org/10.1016/j.jse.2018.02.061>
41. Lo IKY, Litchfield RB, Griffin S, Faber K, Patterson SD, Kirkley A. Quality-of-life outcome following hemiarthroplasty or total shoulder arthroplasty in patients with osteoarthritis. A prospective, randomized trial. *J Bone Joint Surg Am* 2005;87:2178-85. <https://doi.org/10.2106/JBJS.D.02198>
42. Magnussen RA, Mallon WJ, Willems WJ, Moorman CT. Long-term activity restrictions after shoulder arthroplasty: an international survey of experienced shoulder surgeons. *J Shoulder Elbow Surg* 2011;20: 281-9. <https://doi.org/10.1016/j.jse.2010.07.021>
43. Mahomed NN, Liang MH, Cook EF, Daltroy LH, Fortin PR, Fossel AH, et al. The importance of patient expectations in predicting functional outcomes after total joint arthroplasty. *J Rheumatol* 2002; 29:1273-9.
44. Mancuso CA, Graziano S, Briskie LM, Peterson MGE, Pellicci PM, Salvati EA, et al. Randomized trials to modify patients' preoperative expectations of hip and knee arthroplasties. *Clin Orthop Relat Res* 2008;466:424-31. <https://doi.org/10.1007/s11999-007-0052-z>
45. Matsen F, Lippitt S. *Shoulder surgery: principles and procedures*. Philadelphia, PA: Saunders; 2004.
46. McMillan SS, King M, Tully MP. How to use the nominal group and Delphi techniques. *Int J Clin Pharm* 2016;38:655-62. <https://doi.org/10.1007/s11096-016-0257-x>
47. Mulieri PJ, Holcomb JO, Dunning P, Pliner M, Bogle RK, Pupello D, et al. Is a formal physical therapy program necessary after total shoulder arthroplasty for osteoarthritis? *J Shoulder Elbow Surg* 2010; 19:570-9. <https://doi.org/10.1016/j.jse.2009.07.012>
48. Neer CS. Articular replacement for the humeral head. *J Bone Joint Surg Am* 1955;37:215-28.
49. Neer CS, Watson KC, Stanton FJ. Recent experience in total shoulder replacement. *J Bone Joint Surg Am* 1982;64:319-37.
50. Noble PC, Condit MA, Cook KF, Mathis KB. The John Insall Award: patient expectations affect satisfaction with total knee arthroplasty. *Clin Orthop Relat Res* 2006;452:35-43. <https://doi.org/10.1097/01.blo.0000238825.63648.1e>
51. Norris TR, Iannotti JP. Functional outcome after shoulder arthroplasty for primary osteoarthritis: a multicenter study. *J Shoulder Elbow Surg* 2002;11:130-5. <https://doi.org/10.1067/mse.2002.121146>
52. Pandya J, Johnson T, Low AK. Shoulder replacement for osteoarthritis: a review of surgical management. *Maturitas* 2018;108:71-6. <https://doi.org/10.1016/j.maturitas.2017.11.013>
53. Payne C, Jaggi A, Le Leu A, Garofalo R, Conti M. (v) Rehabilitation for shoulder arthroplasty. *Orthop Trauma* 2015;29:313-23. <https://doi.org/10.1016/j.mporth.2015.09.003>

54. Razmjou H, Stratford P, Kennedy D, Holtby R. Pattern of recovery following total shoulder arthroplasty and humeral head replacement. *BMC Musculoskelet. Disord* 2014;15:306. <https://doi.org/10.1186/1471-2474-15-306>
55. Ricchetti ET, Williams GR. Total shoulder arthroplasty—indications, technique, and results. *Oper Tech Orthop* 2011;21:28-38. <https://doi.org/10.1053/j.oto.2010.11.001>
56. Scalise JJ, Ciccone J, Iannotti JP. Clinical, radiographic, and ultrasonographic comparison of subscapularis tenotomy and lesser tuberosity osteotomy for total shoulder arthroplasty. *J Bone Joint Surg Am* 2010;92:1627-34. <https://doi.org/10.2106/JBJS.G.01461>
57. Schrock JB, Kraeutler MJ, Houck DA, Provenzano GG, McCarty EC, Bravman JT. Lesser tuberosity osteotomy and subscapularis tenotomy repair techniques during total shoulder arthroplasty: a meta-analysis of cadaveric studies. *Clin Biomech (Bristol, Avon)* 2016;40:33-6. <https://doi.org/10.1016/j.clinbiomech.2016.10.013>
58. Schumann K, Flury MP, Schwyzer H-K, Simmen BR, Drerup S, Goldhahn J. Sports activity after anatomical total shoulder arthroplasty. *Am J Sports Med* 2010;38:2097-105. <https://doi.org/10.1177/0363546510371368>
59. Sharma P, Maffulli N. Tendon injury and tendinopathy: healing and repair. *J Bone Joint Surg Am* 2005;87:187-202. <https://doi.org/10.2106/JBJS.D.01850>
60. Shields E, Ho A, Wiater JM. Management of the subscapularis tendon during total shoulder arthroplasty. *J Shoulder Elbow Surg* 2017;26:723-31. <https://doi.org/10.1016/j.jse.2016.11.006>
61. Singh JA, Sperling JW, Cofield RH. Revision surgery following total shoulder arthroplasty: analysis of 2588 shoulders over three decades (1976 to 2008). *J Bone Joint Surg Br* 2011;93:1513-7. <https://doi.org/10.1302/0301-620X.93B11.26938>
62. Somerson JS, Neradilek MB, Service BC, Hsu JE, Russ SM, Matsen FA. Clinical and radiographic outcomes of the ream-and-run procedure for primary glenohumeral arthritis. *J Bone Joint Surg Am* 2017;99:1291-304. <https://doi.org/10.2106/JBJS.16.01201>
63. Sonnabend DH, Howlett CR, Young AA. Histological evaluation of repair of the rotator cuff in a primate model. *J Bone Joint Surg Br* 2010;92:586-94. <https://doi.org/10.1302/0301-620X.92B4.22371>
64. St. Pierre P, Frankle M. Shoulder Rehabilitation. Is there a role for home therapy? In: Bennett J, editor. *Physical therapy: theories, practices and benefits*. New York: Nova Science Publishers; 2011.
65. Styron JF, Higuera CA, Strnad G, Iannotti JP. Greater patient confidence yields greater functional outcomes after primary total shoulder arthroplasty. *J Shoulder Elbow Surg* 2015;24:1263-7. <https://doi.org/10.1016/j.jse.2015.04.018>
66. Swarup I, Henn CM, Nguyen JT, Dines DM, Craig EV, Warren RF, et al. Effect of pre-operative expectations on the outcomes following total shoulder arthroplasty. *Bone Joint J* 2017;99:1190-6. <https://doi.org/10.1302/0301-620X.99B9.BJJ-2016-1263.R1>
67. Van Thiel GS, Wang VM, Wang F-C, Nho SJ, Piasecki DP, Bach BR, et al. Biomechanical similarities among subscapularis repairs after shoulder arthroplasty. *J Shoulder Elbow Surg* 2010;19:657-63. <https://doi.org/10.1016/j.jse.2010.01.014>
68. Thigpen CA, Shaffer MA, Gaunt BW, Leggin BG, Williams GR, Wilcox RB. The American Society of Shoulder and Elbow Therapists' consensus statement on rehabilitation following arthroscopic rotator cuff repair. *J Shoulder Elbow Surg* 2016;25:521-35. <https://doi.org/10.1016/j.jse.2015.12.018>
69. Wilcox RB, Arslanian LE, Millett P. Rehabilitation following total shoulder arthroplasty. *J Orthop Sports Phys Ther* 2005;35:821-36. <https://doi.org/10.2519/jospt.2005.35.12.821>
70. Wise MB, Uhl TL, Mattacola CG, Nitz AJ, Kibler WB. The effect of limb support on muscle activation during shoulder exercises. *J Shoulder Elbow Surg* 2004;13:614-20. <https://doi.org/10.1016/j.jse.2004.04.006>
71. Wright T, Easley T, Bennett J, Struk A, Conrad B. Shoulder arthroplasty and its effect on strain in the subscapularis muscle. *Clin Biomech (Bristol, Avon)* 2015;30:373-6. <https://doi.org/10.1016/j.clinbiomech.2015.02.010>