

Critical Coarctation of the Aorta in Selective Fetal Growth Restriction and the Role of Coronary Stent Implantation

Manon Gijtenbeek^a Monique C. Haak^a Arend D.J. ten Harkel^b
Regina Bökenkamp^b Benedicte Eyskens^{d,e} Els Ortibus^{e,f} Bart Meyns^{c,g}
Marc Gewillig^{d,e} Liesbeth Lewi^{e,h}

^aDivision of Fetal Medicine, Department of Obstetrics, Leiden University Medical Center, Leiden, The Netherlands; ^bDepartment of Pediatric Cardiology, Leiden University Medical Center, Leiden, The Netherlands; ^cDepartment of Cardiac Surgery, University Hospitals Leuven, Leuven, Belgium; ^dDepartment of Pediatrics, Pediatric Cardiology, University Hospitals Leuven, Leuven, Belgium; ^eDepartment of Development and Regeneration, Cluster Woman and Child, Biomedical Sciences, KU Leuven, Leuven, Belgium; ^fDepartment of Pediatrics, Pediatric Neurology, University Hospitals Leuven, Leuven, Belgium; ^gDepartment of Cardiovascular Sciences, Biomedical Sciences, KU Leuven, Leuven, Belgium; ^hDepartment of Obstetrics and Gynecology, Obstetrics, University Hospitals Leuven, Leuven, Belgium

Keywords

Coarctation of the aorta · Congenital heart defect · Low birth weight infant · Monochorionic twin · Selective fetal growth restriction · Stent implantation

Abstract

Introduction: Monochorionic twins are at increased risk of congenital heart defects (CHDs). Up to 26% have a birth weight <1,500 g, a CHD requiring neonatal surgery, therefore, poses particular challenges. **Objective:** The aim of the study was to describe pregnancy characteristics, perinatal management, and outcome of monochorionic twins diagnosed with critical coarctation of the aorta (CoA). **Methods:** We included monochorionic twins diagnosed with critical CoA (2010–2019) at 2 tertiary referral centers, and we systematically reviewed the literature regarding CoA in monochorionic twins. **Results:** Seven neonates were included. All

were the smaller twin of pregnancies complicated by selective fetal growth restriction. The median gestational age at birth was 32 weeks (28–34). Birth weight of affected twins ranged as 670–1,800 g. One neonate underwent coarctectomy at the age of 1 month (2,330 g). Six underwent stent implantation, performed between day 8 and 40, followed by definitive coarctectomy between 4 and 9 months in 4. All 7 developed normally, except for 1 child with neurodevelopmental delay. Three co-twins had pulmonary stenosis, of whom 1 required balloon valvuloplasty. The literature review revealed 10 cases of CoA, all in the smaller twin. Six cases detected in the first weeks after birth were treated with prostaglandins alone, by repeated transcatheter angioplasty or by surgical repair, with good outcome in 2 out of 6. **Conclusions:** CoA specifically affects the smaller twin of growth discordant monochorionic twin pairs. Stent implantation is a feasible bridging therapy to surgery in these low birth weight neonates.

© 2020 S. Karger AG, Basel

Introduction

Monochorionic twins are 6 times more likely to be born with a congenital heart defect (CHD) compared to singletons [1]. All subtypes of CHD are more common in monochorionic twins, except for tetralogy of Fallot and transposition of the great arteries [1]. Coarctation of the aorta (CoA) as an isolated congenital abnormality in monochorionic twins is predominantly found in donor twins with twin-twin transfusion syndrome (TTTS) [2, 3]. Donor twins are usually the smaller twin in their set, which leads to the question whether other factors related to fetal growth also contribute to the development of CoA. Up to 26% of monochorionic twins have a birth weight less than 1,500 g [4]. In these very low birth weight (VLBW) infants, a critical CHD, such as critical CoA, poses particular challenges. In term neonates with a normal birth weight, the treatment of choice of critical CoA is surgical repair, usually by resection and extended end-to-end anastomosis. This treatment results in excellent long-term survival with low morbidity. In most centers, the role of catheter interventions by balloon angioplasty or stent implantation is restricted to the resolution of re-coarctation. Catheter interventional therapy in neonates is used as a bailout option in patients with poor left ventricular function or other severe comorbidities. In VLBW infants, the role of catheter intervention might be different as the surgical risks and frequency of re-coarctation will increase. In the present study, we report the pregnancy characteristics, perinatal management, and outcome of monochorionic twins who were diagnosed with critical CoA at 2 tertiary referral centers for complicated monochorionic pregnancies, and we systematically review the literature regarding CoA in monochorionic twins.

Methods

Case Series

A tertiary multicenter retrospective study was performed at the University Hospitals Leuven, Belgium, and Leiden University Medical Center, The Netherlands. We have identified monochorionic twins who were born in one of the 2 tertiary referral centers and were diagnosed with critical CoA between 2010 and 2019.

The following fetal and perinatal variables were collected: time of diagnosis and type of selective fetal growth restriction (sFGR), fetal abnormalities on prenatal ultrasound, gestational age (GA) at birth, birth weight, and placental share. sFGR was defined as an estimated fetal weight <10th centile of one twin with intertwin discordance of $\geq 25\%$ [5, 6] and classified according to the classification system of Gratacós [5]. A detailed fetal anomaly scan was performed at mid-gestation. A third trimester anomaly scan was only

performed in case of suspicion of fetal abnormalities at earlier scans or in case of TTTS. Fetal CoA was suspected when there was ventricular disproportion in a 4-chamber view, the left ventricle being significantly smaller than the right ventricle. Placentas were routinely injected with color dye according to our previously reported protocol [7], and placental territory was calculated by dividing the placental territory of the larger twin by the placental territory of the smaller twin [8].

Postnatal echocardiography was performed in case of clinical signs and symptoms such as a cardiac murmur, diminished pulsations at the lower extremities, or if pulmonary hypertension was suspected. CoA was defined as a local constriction with increased pulse wave velocity and diastolic forward flow across the aortic isthmus. In cases with dubious echo findings under prostaglandin treatment, the drug was discontinued and the patient closely monitored and repeatedly studied by echocardiography to depict the typical findings. For this study, we collected ultrasound and echocardiographic findings, time of diagnosis of CoA, type of treatment postpartum, number of interventions, age and weight of the infant at time of intervention, time to surgery and, if applicable, long-term developmental outcomes. We also collected data on perinatal outcome and long-term outcome of the co-twin.

Systematic Literature Review

Relevant articles were identified using electronic databases (Pubmed, Embase, Web of Science, and Cochrane) on September 30, using search terms related to “monochorionic twins” and “coarctation of the aorta.” The complete search string is available in online suppl. 1 (for all online suppl. material, see www.karger.com/doi/10.1159/000508305). The search was limited to articles written in English. No time restriction for publication dates was used. One reviewer (M. Gijtenbeek) screened titles and abstracts for relevance. If a title or abstract seemed relevant, the full text was retrieved and assessed for inclusion. Selected articles were cross-referenced. Studies were excluded if the twins with CoA had additional extracardiac anomalies or if birth weight could not be retrieved from the data. The following data were extracted from the selected articles and tabulated: first author, year of publication, pregnancy complications, GA at birth, birth weight, time of diagnosis, type of treatment, outcome, and development of the co-twin.

Results

During the study period, 7 monochorionic diamniotic twins were diagnosed with critical CoA, of whom 6 underwent coronary stent implantation as bridging therapy to surgery. All 7 were diagnosed with sFGR during pregnancy. sFGR type 1 (positive umbilical artery end-diastolic flow) was diagnosed in 2 cases, type 2 (persistent absent or reversed umbilical artery end-diastolic flow) in 1 case, and type 3 (intermittent absent or reversed umbilical artery end-diastolic flow) in 4 cases. None of the cases had TTTS. All 7 had discordant amniotic fluid at some point in pregnancy, but the discordance never fulfilled the cri-

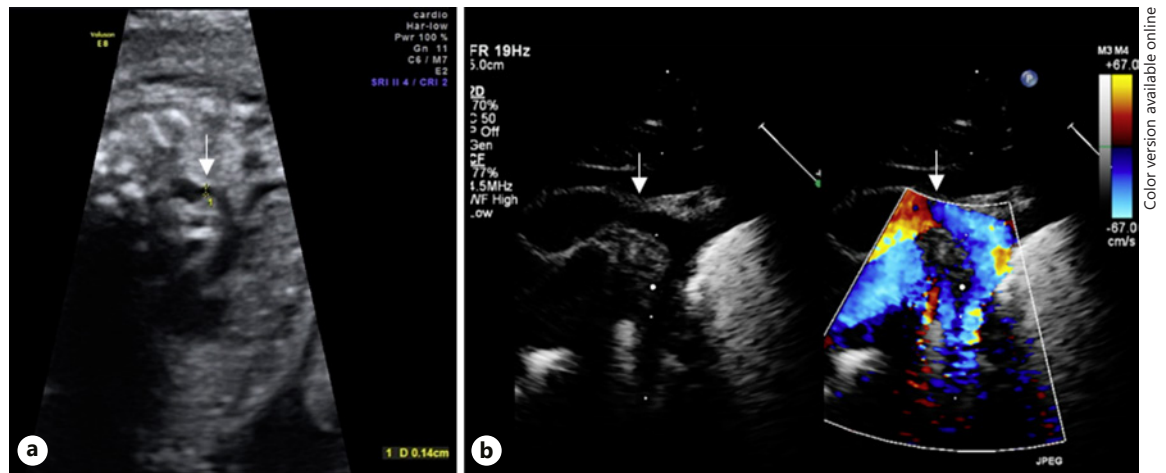


Fig. 1. Ultrasound image of case 2 at 28 weeks' gestation (a) and after birth (b). Arrows indicate the coarcted segment.

teria for TTTS. In case 4 at 17 weeks, there was a difference in middle cerebral artery peak systolic velocity with 32 cm/s in the smaller twin (1.37 multiples of the median) and 17 cm/s in the larger twin (0.73 multiples of the median), suggestive of twin anemia polycythemia sequence, which resolved spontaneously at 20 weeks' gestation. The affected twin in case 1 had borderline ventriculomegaly, with a normal fetal brain MRI at 28 weeks. In 2 cases (cases 2 and 6) CoA was suspected antenatally (Fig. 1). Case 5 showed left/right asymmetry in the 4-chamber view, which was attributed to adaptation in FGR. All cases were hospitalized between 27- and 33-weeks' gestation for inpatient monitoring, including a course of corticosteroids for fetal lung maturation. All were delivered by cesarean section, of which 3 were emergency deliveries because of an abnormal heart rate pattern in the smaller twin. The median GA at birth was 32 weeks (28–34). Birth weight of the affected twins ranged from 670 to 1,800 g. The placentas showed gross unequal sharing with little individual territory for the smaller twin, except for the placenta of the case with early twin anemia polycythemia sequence.

All infants, except for case 4, were given intravenous prostaglandin E (PGE) treatment to keep the arterial duct open. PGE was stopped in 2 cases because of suspected pulmonary hemorrhage (cases 1 and 3) and pulmonary edema (case 1). Two other cases experienced hypotension (case 5) or sepsis-like syndrome (case 6) resulting from prolonged PGE treatment. One twin, born at 34 weeks' gestation with a birth weight of 1,630 g (co-twin 2,475 g), underwent coarctectomy via thoracotomy at the age of 1 month (2,330 g) and a balloon dilatation of a re-coarctation at the age of 2.5 months.

The other 6 neonates underwent coronary stent implantation, of whom individual patient characteristics and outcomes are depicted in Table 1. In case 5, balloon angioplasty on day 18 (1,040 g) via the right carotid artery was performed, which was not effective. In all 6 cases, coronary stent placement was performed because of unbalanced hemodynamic situation with systemic hypoperfusion and pulmonary overflow. Median age and weight at stent implantation was 29 days (8–40) and 1,735 g (1,075–2,700), respectively (Fig. 2). Stent implantation was performed via sternotomy (cases 1 and 6), or percutaneously via the femoral artery (cases 2, 3, and 4) or carotid artery (Case 5). Heparin and conotrope was administered to case 3 because of femoral artery thrombosis. No other complications of stent placement occurred. Cases 1 and 5 had a percutaneous balloon dilatation of the stent at 3 months (2,580 g) and 10 months (8,500 g), respectively. In case 6, 2 coronary stents were placed via sternotomy together with banding of the pulmonary artery and clipping of the duct. At the age of 2 months (3,008 g), a percutaneous balloon dilatation of the stent, a stent-in-stent placement proximal in the CoA, and a balloon dilatation of pulmonary artery banding were performed. Four infants had definitive surgical correction via thoracotomy at 6 months (4–9) and weight 5,150 g (4,430–6,080); 2 infants were still awaiting coarctectomy. Two patients suffered from pneumonia postsurgery (cases 2 and 3).

All 7 infants developed normally (9 months–9 years), except for 1 child with neurodevelopmental delay. One infant had a mildly delayed motor development at the age of 1 year, which was attributed to visual impairment because of areolar atrophy of the macula.

Table 1. Results

Characteristic	Case 1	Case 2	Case 3	Case 4	Case 5	Case 6
Fetal characteristics	sFGR type 3 (15 wk) Brain MRI normal (28 wk)	sFGR type 3 (15 wk) A: CoA; B: PS (28 wk)	sFGR type 3 (25 wk) A: absent DV; B: PS (25 wk) Brain MRI normal (30 wk)	sFGR type 1, TAPS (17 wk) TAPS spontaneous resolved (20 wk)	sFGR type 1 (23 wk) A: LV/RV asymmetry (26 wk) sFGR type 2 (27 wk)	sFGR type 1 (16 wk) A: PLVCS, CoA (20 wk) A: hypoplastic arch, VSD (29 wk)
Obstetrical outcome						
GA at birth (wk + d)	28 + 4	32 + 4	32 + 2	34	28 + 1	34
BW (percentile)	A: 670 g (1st), B: 1,055 g (7th)	A: 1,800 g (17th), B: 2,150 g (71st)	A: 1,190 g (1st), B: 1,630 g (6th)	A: 1,530 g (1st), B: 2,280 g (44th)	A: 780 g (10th), B: 1,466 g (94th)	A: 1,380 g (1st), B: 2,160 g (27th)
Placental share	13%/87%	15%/85%	–	32%/68%	19%/81%	25%/75%
Postnatal outcome A						
Age at diagnosis	5 d	Prenatal	1 d	40 d	11 d	Prenatal
PDA with PGE	Yes	Yes	Yes	No	Yes	Yes
Age at stent	29 d	28 d	30 d	40 d	22 d	8 d
Weight at stent	1,075 g	2,700 g	1,750 g	2,410 g	1,210 g	1,719 g
Stent size, mm	3×8	4.5×12	4.7×8	4×8	4.5×13	4×8 and 4.5×12
Age at surgery	9 mo	6 mo	5.5 mo	4 mo	N/A	N/A
Weight at surgery	5,000 g	6,080 g	5,300 g	4,430 g	N/A	N/A
Follow-up	2 yr: mild delay motor development, 8 yr: normal cardiac function	6 yr: delayed mental development, 7 yr: normal cardiac function	6 yr: normal development and cardiac function	4 yr: normal development and cardiac function	1 yr: mild delay motor development, 19 mo: awaiting repair	9 mo: awaiting repair
Postnatal outcome B						
Diagnosis	RDS	Dilated ascending aorta, peripheral PS	Pulmonary valve stenosis, 30 d: balloon dilatation	11 mo: repair of isolated palatoschisis	RDS	Peripheral PS
Follow-up	2 yr: normal development	6 yr: delayed language development, 7 yr: normal cardiac function	8 yr: normal development and cardiac function	3 yr: normal development	1 yr: normal development	9 mo: normal development

sFGR, selective fetal growth restriction; w, weeks; TAPS, twin anemia polycythemia sequence; A, affected twin; B, co-twin; PS, pulmonary stenosis; DV, ductus venosus; LV/RV, left/right ventricle; PLVCS, persistent left vena cava superior; CoA, coarctation of the aorta; VSD, ventricle septum defect; GA, gestational age; d, day(s); BW, birth weight; g, grams; PDA, patent ductus arteriosus; PGE, prostaglandin E; mo, month(s); g, gram(s); N/A, not applicable; yr, year(s); RDS, respiratory distress syndrome.

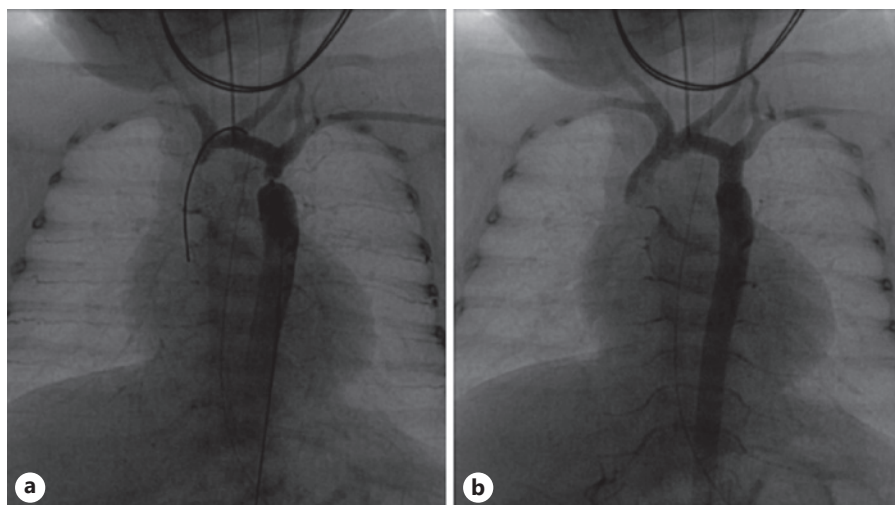


Fig. 2. Intraoperative images of case 3. **a** Pre-intervention. **b** Status post-stent implantation.

Three of the larger co-twins had a form of pulmonary stenosis: 1 twin had symptomatic pulmonary valve stenosis that required balloon valvuloplasty at the age of 2 months and 2 twins had peripheral pulmonary artery stenosis that was managed conservatively. All co-twins had a normal development and cardiac function at follow-up visits.

Systematic Literature Review

The search resulted in 145 articles. After the removal of 48 overlapping results, 97 abstracts and titles were screened. Full texts of 21 articles were assessed in detail. Review articles ($n = 2$), congress abstracts ($n = 3$), articles with non-isolated cases ($n = 4$), articles from which the birth weight or exact number of twins with CoA could not be retrieved ($n = 5$), and articles not written in English ($n = 1$) were excluded. The remaining 6 articles were case reports, case series, or cohort studies [2, 3, 9–12].

The 6 articles described 10 cases of monozygotic twins with discordant CoA (Table 2). Four twins had TTTS, all were treated by amnioreduction. In 2 other cases (9–10), TTTS diagnosis was uncertain (no mentioning of Quintero staging). Both were treated by immediate delivery of twins because of fetal distress, with a significant birth weight discordance. The median birth weight of affected twins was 925 g (712–2,523); all were the smaller twin in their set. Four cases of CoA were detected after more than 2 months, of whom 2 underwent a coarctectomy with good cardiac outcome. In 6 cases, critical CoA was detected in the first weeks after birth (cases 4–10). Cases 4 and 8 were treated with PGE alone, of whom one died after 4 days, and the other infant had extensive periventricular leukomalacia on MRI. Case 9 had 2 angioplas-

ties with normal outcome. Three cases had surgical correction of the CoA, of whom one developed severe neurological problems, and another suffered from chronic lung disease and poor growth.

Five out of 10 co-twins had an uneventful neonatal period and follow-up. Two infants died, 1 suffered from PPHN, and the other had a dysplastic aortic valve. One co-twin had Ebstein's anomaly with pulmonary stenosis, which required balloon septostomy and valve repair.

Discussion

This case series shows that sFGR in monozygotic twin pregnancies can be accompanied by critical CoA, which specifically affects the smaller twin. In these low birth weight infants, stent implantation is a feasible bridging therapy to surgery.

The estimated prevalence of CoA in monozygotic twins is 2.1 per 1,000 live births [1], which is considerably higher than the population prevalence of 0.34 per 1,000 singleton live births [13]. There are a few case series available describing this defect in monozygotic twins [2, 3, 9–12, 14–17], and CoA as an isolated congenital abnormality in monozygotic twins has been associated with TTTS [2, 3]. The underdevelopment of the aortic arch in donor twins is possibly explained by (chronic) hypovolemia and decreased left-sided cardiac output [18]. The donor twins in these case reports were the smaller twin in their set, which leads to the question of whether factors related to fetal growth also contribute to the development of CoA. All our cases affected the smaller twin of a monozygotic pair with sFGR, and none had TTTS. In an un-

Table 2. Summary of monochorionic twins with discordant CoA reported in the literature

Author	Pregnancy complications	GA at birth, wk	BW, g	BW co-twin, g	Time of diagnosis	Treatment	Follow-up	Co-twin
1 Driver and Suckling [9]	None	-	2,200	2,300	5.5 months			Normal development
2 Morgan [10]	?	-	2,155	3,289	5 years	8 weeks after diagnosis surgical repair	1 year after surgery: alive and well	Normal development
3 Morgan [10]	?	-	2,523	2,835	5 years	None		Normal development
4 Hidaka et al. [11]	TTTS (donor)	28	712	1,060	Postnatal	PGE	Pulmonary hemorrhage and renal failure; died on day 4	Normal development
5 van den Boom et al. [2]	TTTS (donor)	27	725	1,200	Postnatal	Day 22 surgical repair	IVH, 9 months: mild residual stenosis of the distal aorta, spastic diplegia, and cortical blindness	PPHN; died after 25 h
6 van den Boom et al. [2]	TTTS (donor)	28	850	1,180	Day 65	Day 67 surgical repair	Discharged at 5 weeks corrected GA	Chronic lung disease and PDA without treatment
7 van den Boom et al. [2]	TTTS (donor)	25	713	937	Day 4	Day 13 surgical repair of CoA and PDA	Chronic lung disease, poor growth	Dysplastic aortic valve; died after 24 h
8 van den Boom et al. [2]	TTTS (donor)	33	1,520	2,490	Postnatal	PGE for 1 day	Hypoplastic distal aortic arch, no focal coarctation; MRI showed extensive PVL repair	PPHN, Ebstein anomaly with PS; balloon septostomy + valve repair
9 Al-Ammouri et al. [3]	TTTS?	30	900	1,550	Day 5	Day 7 balloon angioplasty, day 47 balloon angioplasty re-coarctation	13 months: no signs of re-coarctation	Normal development
10 Moldovan and Cucerea [12]	TTTS?	31	950	1,700	2 weeks	Surgical correction at 2 months (2,000 g)	Severe ROP	Bilateral grade III IVH, bilateral ventriculomegaly, intracranial hypertension; VP drain

GA, gestational age; w, weeks; BW, birth weight; g, grams; TTTS, twin-twin transfusion syndrome; PGE, prostaglandin E; IVH, intraventricular hemorrhage; PPHN, persistent pulmonary hypertension of the newborn; PDA, patent ductus arteriosus; CoA, coarctation of the aorta; PVL, periventricular leukomalacia; PS, pulmonary stenosis; ROP, retinopathy of prematurity; VP, ventriculoperitoneal.

selected cohort of monochorionic twin pregnancies [19], there were 64 live-born twin pairs with a birth weight of more than 25%. Of these 64, 3 growth-restricted twins were diagnosed with a critical CoA, leading to an estimated incidence of about 5%.

Altered blood flow conditions affect cardiac development of monochorionic twins with sFGR differently, and cardiac dysfunction occurs in both the larger and the smaller co-twins even in the absence of TTTS [20]. In TTTS, the renin-angiotensin system is activated, and the renal secretion of renin is upregulated because of the chronic hypovolemia in the donor twin [21, 22]. It has been suggested that renin is activated in both the larger and the smaller twins in sFGR as well, with or without the presence of TTTS [23]. Unequally shared placentas in twins without TTTS usually have large AA anastomoses, a larger net flow over arterio-venous anastomoses, and a larger diameter of all anastomoses [24]. The characteristics of umbilical artery Doppler flow are strongly influenced by the pattern of these intertwin vascular connections, and the predominant direction and magnitude of blood flow interchange via placental anastomoses may vary accordingly. Fetuses with positive umbilical artery diastolic flow are generally considered to have a favorable prognosis and fetuses with persistent absent or reversed end-diastolic flow have been reported to have a high risk of hypoxia and fetal demise [5]. Since 4 of the 7 cases in this study had intermittent absent or reversed umbilical artery end-diastolic flow, we hypothesize that highly unstable fetal hemodynamics may contribute to the development of cardiovascular abnormalities. In the smaller twin in sFGR, without signs of TTTS, narrowing of the aortic arch may occur secondary to the hemodynamic disturbances (decreased perfusion and decreased left-sided cardiac output) [25]. Two of our cases with critical CoA had positive umbilical artery diastolic flow, suggesting that only chronic hypovolemia may already have an effect on cardiac development.

Interestingly, 3 of the larger twins in our study had pulmonary stenosis of whom one required balloon valvuloplasty. The larger twin perfuses a variable proportion of the placenta of the smaller one, mainly via AA anastomoses. This involves by definition an increase in cardiac output and potentially a hyperdynamic circulation, resembling a milder form of the situation observed in monochorionic twins with an acardiac fetus [26]. The myocardial adaptation to the hyperdynamic circulation in the larger twin may result in pulmonary stenosis [27].

In previous reports of CoA in VLBW donor twins [2, 3], the defect was treated with prostaglandins alone, by

repeated transcatheter angioplasty or by surgical repair. In VLBW infants, surgical treatment carries a substantial risk for morbidity and mortality [28, 29] and is preferably postponed until 3 kg with prostaglandins. In our experience, the results of surgical coarctation repair at 1.5 kg are disappointing with a high risk of early critical re-coarctation. “Rescue-stenting” of the re-coarctation can then be offered, followed by surgical reintervention with stent excision later in life. This redo surgery carries a risk of complications such as vocal cord paralysis or phrenic nerve paralysis. Prolonged treatment with PGE to postpone surgery is also associated with a high risk of complications, such as respiratory depression, hypotension, sepsis, and hemorrhage. In fact, in our series, PGE treatment was discontinued because of complications in 4 out of 6 cases. In 6 out of 7 patients, prostaglandin therapy was insufficient to gain weight and postpone surgery, and the clinical condition demanded earlier treatment. Balloon angioplasty as bridging therapy to surgery can be performed in case of localized coarctation with otherwise well-developed aortic arch. In case of long-segmented aortic arch hypoplasia, balloon angioplasty will not be useful, and balloon dilatation before 6 months of age has a recurrence rate over 50% [30, 31].

In our experience, it is difficult to maintain an acceptable hemodynamic balance in children with left heart obstructive lesions and duct dependent systemic circulation requiring PGE therapy. Pulmonary vascular resistance will drop in the first weeks after birth, and this process occurs earlier in the premature infant [32]. As a result, these children will develop pulmonary overflow and insufficient systemic circulation with clinical signs of heart failure and risk of necrotizing enterocolitis. To minimize these risks, in twin pairs with discordant growth that are usually delivered between 32 and 34 weeks gestation, primary coronary stent implantation may be a feasible bridging therapy to surgery [33, 34], which we have shown with this case series. Stent implantation can lead to a longer postponement of surgery, and consequently higher infant weight at surgery [33]. Stent implantation does carry a substantial risk of complications, such as carotid or femoral artery trauma or thrombosis. In our study, however, only 1 patient had a complication of the stent implantation. In newborns where a very small stent is implanted, re-coarctation is likely to occur. In our series, 3 patients needed a (balloon) dilatation of the stent, procedures that went uneventful. Four infants received uncomplicated surgical correction by thoracotomy, a procedure that may be more challenging than primary surgical correction. All 6 infants treated by stent implantation had a good cardiac

outcome, 2 were still awaiting definitive repair. Unfortunately, there are no controlled studies yet to decide on the best treatment for the rare cases of critical CoA in VLBW infants.

Long-term neurodevelopment was favorable in the majority of twins. It is known that the risk of long-term neurological or cognitive impairment in monochorionic twins with sFGR or with a large birth weight discordance is higher than in uncomplicated monochorionic or dichorionic twins, with a disadvantage for the smaller twin [35]. In our cohort, 6 of the 7 growth restricted twins had a normal neurodevelopment. Even though the numbers in this study are small, the presence of a critical CoA in addition to the growth restriction does not seem to increase the risk of neurodevelopmental impairment in monochorionic twins.

In conclusion, CoA appears to specifically affect the smaller twin of a growth discordant monochorionic twin pair. Stent implantation is a feasible bridging therapy to surgery in these low birth weight neonates. Larger cotwins are also at risk for cardiac anomalies arising from cardiac overload, namely, pulmonary stenosis. Our findings underline the importance of dedicated fetal echocardiography and postnatal surveillance in twin pregnancies complicated by sFGR.

References

- Gijtenbeek M, Shirzada MR, Ten Harkel ADJ, Oepkes D, Haak MC. Congenital heart defects in monochorionic twins: a systematic review and meta-analysis. *J Clin Med*. 2019;8(6):902.
- van den Boom J, Battin M, Hornung T. Twin-twin transfusion syndrome, coarctation of the aorta and hypoplastic aortic arch: a case series report. *J Paediatr Child Health*. 2010;46(3):76–9.
- Al-Ammouri I, Jaradat S, Radwan J. Severe coarctation of the aorta in a 900 g donor of twin-twin transfusion newborn with successful repeated transcatheter angioplasty: a case report. *Cardiol Young*. 2015;25(2):394–7.
- Hack KE, Derks JB, de Visser VL, Elias SG, Visser GH. The natural course of monochorionic and dichorionic twin pregnancies: a historical cohort. *Twin Res Hum Genet*. 2006;9(3):450–5.
- Gratacós E, Lewi L, Muñoz B, Acosta-Rojas R, Hernandez-Andrade E, Martinez JM, et al. A classification system for selective intrauterine growth restriction in monochorionic pregnancies according to umbilical artery Doppler flow in the smaller twin. *Ultrasound Obstet Gynecol*. 2007;30(1):28–34.
- Lewi L, Gucciardo L, Huber A, Jani J, Van Mieghem T, Doné E, et al. Clinical outcome and placental characteristics of monochorionic diamniotic twin pairs with early- and late-onset discordant growth. *Am J Obstet Gynecol*. 2008;199(5):511.e1–e7.
- Lopriore E, Slaghekke F, Middeldorp JM, Klumper FJ, van Lith JM, Walther FJ, et al. Accurate and simple evaluation of vascular anastomoses in monochorionic placenta using colored dye. *J Vis Exp*. 2011;(55):e3208.
- Groene SG, Tollenaar LSA, Slaghekke F, Middeldorp JM, Haak M, Oepkes D, et al. Placental characteristics in monochorionic twins with selective intrauterine growth restriction in relation to the umbilical artery Doppler classification. *Placenta*. 2018;71:1–5.
- Driver CD, Suckling PV. Coarctation of the aorta in one of identical twins. *S Afr Med J*. 1960;34:592–3.
- Morgan J. Evidence of non-genetic origin of coarctation of the aorta. *Can Med Assoc J*. 1969;100(24):1134–8.
- Hidaka N, Tsukimori K, Chiba Y, Hara T, Wake N. Monochorionic twins in which at least one fetus has a congenital heart disease with or without twin-twin transfusion syndrome. *J Perinat Med*. 2007;35(5):425–30.
- Moldovan E, Cucerea M. Drug closure of a patent ductus arteriosus in an extremely low birth weight premature newborn. A case report. *J Crit Care Med*. 2015;1(1):28–32.
- van der Linde D, Konings EE, Slager MA, Witsenburg M, Helbing WA, Takkenberg JJ, et al. Birth prevalence of congenital heart disease worldwide: a systematic review and meta-analysis. *J Am Coll Cardiol*. 2011;58(21):2241–7.
- Yasuda K, Ohki S, Seguchi M. Co-occurrence of coarctation of the aorta and hypospadias in smaller twins in monochorionic pregnancies: two case reports. *Am J Perinatol*. 2004;21(3):131–4.
- Ropačka-Lesiak M, Kowalska-Jasiecka J, Kowalska K, Lech J, Malewski W, Breborowicz G. [Aortic coarctation in the recipient in TTTS: diagnostic problems: a case report]. *Ginekol Pol*. 2012;83(7):545–8.
- Sehested J. Coarctation of the aorta in monozygotic twins. *Br Heart J*. 1982;47(6):619–20.
- Levin DL, Muster AJ, Newfeld EA, Paul MH. Concordant aortic arch anomalies in monozygotic twins. *J Pediatr*. 1973;83(3):459–61.

Statement of Ethics

The research was conducted ethically in accordance with the World Medical Association Declaration of Helsinki. The study was approved by the Medical Ethics Committee of the University Hospital Leuven, Leuven, Belgium (S62385), and the Leiden University Medical Center, Leiden, The Netherlands (G19.084). The local ethics committee of the University Hospital Leuven agreed on using retrospective data collected by the interventional team without written consent of included patients.

Conflict of Interest Statement

The authors have no conflicts of interest to declare.

Funding Sources

L.L. is supported by a grant of Fonds voor Wetenschappelijk Onderzoek (1804718N).

Author Contributions

Study conception and design: M. Gijtenbeek, L.L., and M.C.H.; data acquisition: all authors; analysis and data interpretation: M. Gijtenbeek, L.L., and M.C.H.; drafting of the manuscript: M. Gijtenbeek and L.L.; and critical revision: all authors.

- 18 Rudolph AM, Heymann MA, Spitznas U. Hemodynamic considerations in the development of narrowing of the aorta. *Am J Cardiol.* 1972;30(5):514–25.
- 19 Couck I, Ponnet S, Deprest J, Devlieger R, de Catte L, Lewi L. Outcome of selective intrauterine growth restriction in monochorionic twin pregnancies at 16, 20 or 30 weeks according to the new consensus definition. *Ultrasound Obstet Gynecol.* 2020.
- 20 Moriichi A, Cho K, Furuse Y, Akimoto T, Kaneshi Y, Yamada T, et al. B-type natriuretic peptide levels are correlated with birthweight discordance in monochorionic-diamniotic twins without twin-twin transfusion syndrome. *J Perinatol.* 2013;33(3):182–7.
- 21 Mahieu-Caputo D, Dommergues M, Delezoide AL, Lacoste M, Cai Y, Narcy F, et al. Twin-to-twin transfusion syndrome. Role of the fetal renin-angiotensin system. *Am J Pathol.* 2000;156(2):629–36.
- 22 Mahieu-Caputo D, Meulemans A, Martinovic J, Gubler MC, Delezoide AL, Muller F, et al. Paradoxical activation of the renin-angiotensin system in twin-twin transfusion syndrome: an explanation for cardiovascular disturbances in the recipient. *Pediatr Res.* 2005; 58(4):685–8.
- 23 Fujioka K, Morioka I, Miwa A, Yokota T, Matsuo K, Morikawa S, et al. Renin is activated in monochorionic diamniotic twins with birthweight discordance who do not have twin-to-twin transfusion syndrome. *J Perinatol.* 2012;32(7):514–9.
- 24 Lewi L, Cannie M, Blickstein I, Jani J, Huber A, Hecher K, et al. Placental sharing, birthweight discordance, and vascular anastomoses in monochorionic diamniotic twin placentas. *Am J Obstet Gynecol.* 2007;197(6): 587.e1–e8.
- 25 Buyens A, Gyselaers W, Coumans A, Al Nasiry S, Willekes C, Boshoff D, et al. Difficult prenatal diagnosis: fetal coarctation. *Facts Views Vis Obgyn.* 2012;4(4):230–6.
- 26 Umur A, van Gemert MJ, van den Wijngaard JP, Ross MG, Nikkels PG. Haemodynamic resistance model of monochorionic twin pregnancies complicated by acardiac twinning. *Phys Med Biol.* 2004;49(14):N205–13.
- 27 Eschbach SJ, Boons LSTM, Van Zwet E, Middeldorp JM, Klumper FJCM, Lopriore E, et al. Right ventricular outflow tract obstruction in complicated monochorionic twin pregnancy. *Ultrasound Obstet Gynecol.* 2017;49(6):737–43.
- 28 Sudarshan CD, Cochrane AD, Jun ZH, Soto R, Brizard CP. Repair of coarctation of the aorta in infants weighing less than 2 kilograms. *Ann Thorac Surg.* 2006;82(1):158–63.
- 29 Karamlou T, Bernasconi A, Jaeggi E, Alhabshan F, Williams WG, Van Arsdell GS, et al. Factors associated with arch reintervention and growth of the aortic arch after coarctation repair in neonates weighing less than 2.5 kg. *J Thorac Cardiovasc Surg.* 2009;137(5):1163–7.
- 30 Rao PS, Jureidini SB, Balfour IC, Singh GK, Chen SC. Severe aortic coarctation in infants less than 3 months: successful palliation by balloon angioplasty. *J Invasive Cardiol.* 2003; 15(4):202–8.
- 31 Liang CD, Su WJ, Chung HT, Hwang MS, Huang CF, Lin YJ, et al. Balloon angioplasty for native coarctation of the aorta in neonates and infants with congestive heart failure. *Pediatr Neonatol.* 2009;50(4):152–7.
- 32 Rudolph AM. *Fetal circulation and cardiovascular adjustments after birth. Rudolph's pediatrics.* New York: McGraw-Hill Education; 2003. p. 1794.
- 33 Stegeman R, Breur JMPJ, Heuser J, Jansen NJG, de Vries WB, Vijlbrief DC, et al. Primary coronary stent implantation is a feasible bridging therapy to surgery in very low birth weight infants with critical aortic coarctation. *Int J Cardiol.* 2018;261:62–5.
- 34 Radtke WA, Waller BR, Hebra A, Bradley SM. Palliative stent implantation for aortic coarctation in premature infants weighing. *Am J Cardiol.* 2002;90(12):1409–12.
- 35 Groene SG, Tollenaar LSA, Oepkes D, Lopriore E, van Klink JMM. The impact of selective fetal growth restriction or birth weight discordance on long-term neurodevelopment in monochorionic twins: a systematic literature review. *J Clin Med.* 2019;8(7): 944.