

Classification Criteria in Axial Spondyloarthritis

What Have We Learned; Where Are We Going?



Rhys J. Hayward^{a,b}, Pedro M. Machado, MD, PhD^{a,c,d,*}

KEYWORDS

- Axial spondyloarthritis • Ankylosing spondylitis • Classification • Diagnosis
- Back pain • Inflammation • Magnetic resonance imaging • Radiographs

KEY POINTS

- Axial spondyloarthritis (axSpA) is a chronic inflammatory condition that can present with either radiographic changes or without.
- Historically there was the requirement for radiographic changes, whereas the updated classifications incorporate clinical manifestations, family history, response to therapy, MRI, and genetic and laboratory findings.
- Classification criteria have progressed in line with scientific advances incorporating the utility of MRI to identify inflammatory changes to the sacroiliac joint before radiographic changes.
- The ASAS classification criteria are the most relevant criteria set that increase the scope and parameters. They have facilitated SpA research, including epidemiology, outcomes research, and treatment.
- Clinical judgment remains the mainstay for diagnosis of axSpA. Physicians should not misuse classification criteria, avoiding their use before a clinical diagnosis is made.

INTRODUCTION

Spondyloarthritis (SpA) is a generic term for a family of diseases, which can either have a predominantly axial (axial SpA [axSpA]; cardinal manifestation: chronic back pain) or a predominantly peripheral phenotype (peripheral SpA [pSpA]; cardinal manifestation(s): arthritis, enthesitis, or dactylitis). The range of clinical features of SpA is broad

^a Department of Rheumatology, Northwick Park Hospital, London North West University Healthcare NHS Trust, Watford Road, Harrow, Middlesex HA1 3UJ, London, UK; ^b Department of Rheumatology, University College London Hospitals NHS Foundation Trust, 3rd Floor, 250 Euston Road, NW1 2PG, London, UK; ^c Department of Neuromuscular Diseases, University College London, 1st Floor, Russell Square House, 10-12 Russell Square, WC1B 5EH, London, UK; ^d Centre for Rheumatology, University College London, Room 415, 4th Floor, Rayne Institute, 5 University St, Bloomsbury, London WC1E 6JF

* Corresponding author. Centre for Rheumatology and Department of Neuromuscular Diseases, University College London, 1st Floor, Russell Square House, 10-12 Russell Square, London WC1B 5EH, UK.

E-mail address: p.machado@ucl.ac.uk

and includes chronic (typically inflammatory) back pain, arthritis, enthesitis, dactylitis, as well as extra-articular manifestations (EAMs), such as psoriasis, uveitis, and inflammatory bowel disease (IBD). SpA is associated with the major histocompatibility complex class I human leukocyte antigen-B27 (HLA-B27)^{1,2} and axSpA can be further divided into 2 subsets: axSpA with (radiographic axial SpA [r-axSpA] or ankylosing spondylitis [AS]) and without definite radiographic changes in the sacroiliac joints (SIJs) (nonradiographic axial SpA [nr-axSpA]).

SpA encompasses diseases historically designated as AS, psoriatic arthritis (PsA), enteropathic arthritis (IBD-related arthritis), reactive arthritis, arthritis related to uveitis, and a subgroup of juvenile idiopathic arthritis (enthesitis-related arthritis) (Fig. 1). For this article we will be focusing on the axial component of the disease. HLA-B27 is present in about 8% in populations of European descent, and the prevalence of axSpA mirrors the prevalence of HLA-B27 in a given population, ranging between 0.3% and 1.4%.³ The aim of this article is to highlight how diagnosis is evolving and classification of axSpA has changed, including much of the terminology.

DIAGNOSIS AND CLASSIFICATION OF AXIAL SPONDYLOARTHRITIS

The diagnosis of axSpA should be a clinical exercise based on the recognition of a pattern of clinical, laboratory, and imaging features that, taken together, are suggestive of axSpA. This exercise includes the consideration of differential diagnosis. Classification criteria are mainly used for research purposes and intended to create homogenous groups of patients with a certain condition applying a standardized definition. Fig. 2 gives an historical perspective of SpA classification criteria over time and landmark developments related to the development of new criteria; Table 1 summarizes the various published criteria.

The modified New York (mNY) criteria for AS^{2,4,5} required the presence of radiographic changes at the SIJ.⁶ For a very long time, these were primary classification criteria for those patients with inflammatory back pain (IBP) or with limitation of spinal/chest mobility.⁷ The main limitation of these criteria is the requirement of definite radiographic changes of the SIJs; the criteria were often applied as diagnostic criteria and this has the very real potential of causing a delay to diagnosis and ultimately treatment. It is known that it can take several years before there is progression from inflammation in the SIJs to clear evidence of radiographic changes. Moreover, a certain

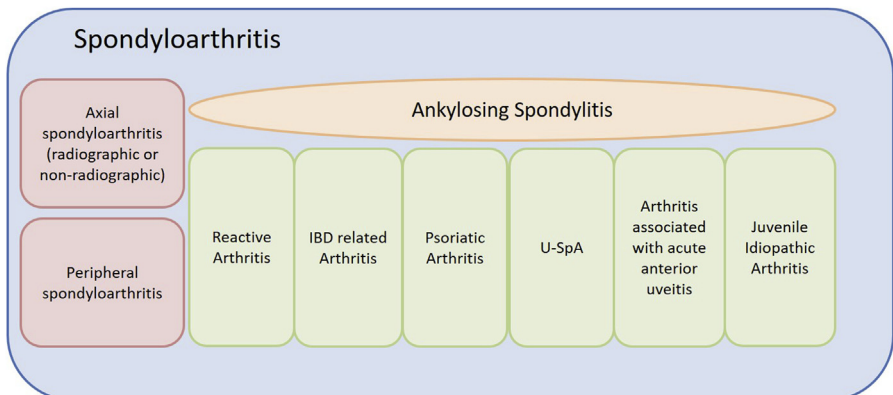


Fig. 1. The spondyloarthritis spectrum. IBD, inflammatory bowel disease; U-SpA, undifferentiated spondyloarthritis.

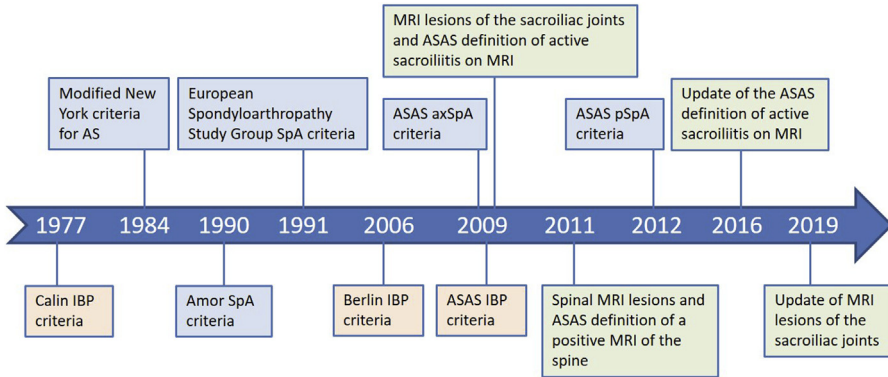


Fig. 2. Development of classification criteria for spondyloarthritis and inflammatory back pain and MRI definitions over time. AS, ankylosing spondylitis; ASAS, Assessment of Spondyloarthritis International Society; axSpA, axial spondyloarthritis; IBP, inflammatory back pain; pSpA, peripheral spondyloarthritis; SpA, spondyloarthritis. (Data from Refs. ^{7,9,10,12,19,20,68-73})

proportion of those with axSpA may never go onto develop definite radiographic damage and therefore, although unequivocally having the clinical characteristics of AS, may never fulfill these criteria.

AXIAL SPONDYLOARTHRITIS: AN HISTORICAL PERSPECTIVE

The mNY criteria for AS⁷ were published in 1985. It was a body of work that standardized the classification of AS; the change was to include sacroiliitis grade ≥ 2 bilaterally or sacroiliitis grade 3 unilaterally to define the presence of radiographic sacroiliitis; this was mandatory and clinical presentations alone were not enough. This could be potentially detrimental as radiographic changes may not always be present; moreover, there is also the issue of discrepancies in interpretation of radiographs that can play a role in heterogeneity and further delay of diagnosis. The reliability of SIJ grading is poor, and training makes little impact on improving the reproducibility.⁸ Equally the mNY clinical criteria do not take into account the peripheral and EAMs of the disease.

Subsequently, Amor and colleagues⁹ developed their criteria. These criteria, however, aim to classify patients within the entirety of the SpA group and are not specific only to the axial disease. Therefore, for the purposes of classifying axSpA they help but are not enough. These criteria use a scoring system, with ≥ 6 being classifiable and ≥ 5 being probable of SpA. Adding a weighting structure is useful but can be seen as arduous. They use an imaging component but only with regard to a definite radiographic change (similar to the mNY criteria), which scores 3 points, the most attainable for a single component. The criteria then highlight a list of potential clinical components with associated scores being: lumbar or dorsal pain during the night, or morning stiffness of lumbar or dorsal spine (1 point); asymmetric oligoarthritis (2 points); buttock pain (1 point); if affecting alternately the right or left buttock (2 points); dactylitis (2 points); enthesitis (2 points); iritis (2 points); nongonococcal urethritis or cervicitis accompanying, or within 1 month before, the onset of arthritis (1 point); presence or history of psoriasis, balanitis, or IBD (2 points); good response to nonsteroidal anti-inflammatory drugs (NSAIDs) in less than 48 hours, or relapse of the pain in less than 48 hours if NSAIDs discontinued (2 points); presence of HLA-B27, of familial history of AS, Reiter syndrome, uveitis, psoriasis, or chronic enterocolopathies (2 points).

Then the European Spondyloarthritis Study Group (ESSG) developed a criteria set. Their rationale was that there were areas of SpA that were being neglected in the classification, which, ultimately, could help to better categorize patients belonging to the SpA spectrum. They completed a multicenter Europe-wide study identifying the sensitivity and specificity of a wider criteria set. They started with 183 variables but this was narrowed down to 25, then further to the following 7 with the primary criteria being that a patient had to have either IBP or synovitis (asymmetric or predominately lower limbs) and at least 1 of the following, positive family history; IBD; urethritis; cervicitis or acute diarrhea ≤ 1 month before onset of symptoms; alternating buttock pain; enthesopathy; or radiographic sacroiliitis. It is important to note that these criteria can be used for both axSpA and pSpA and is therefore not specific to only axial disease. Diagnosis of sacroiliitis depends on radiographic changes but not inflammatory changes (only visible on MRI). These criteria do not include MRI inflammatory changes to the spine, or for that matter radiographic changes, which could be perceived as a limiting factor. Nevertheless the sensitivity and specificity was comparable with the criteria of Amor and colleagues, with sensitivity 86.7% and 84.8% and specificity 87% and 89.9%, respectively.¹⁰

In 2009 the term axSpA was created by the Assessment of Spondyloarthritis International Society (ASAS) who went on to create the ASAS classification criteria for axSpA.^{11,12} This is the first classification criteria set developed after the introduction of MRI for axial disease.¹³ Therefore, one can assume that this concept would reduce the likelihood of their being false negatives based on normal radiographic findings; the set equally increased the positive predictive value of axSpA to 93.3%.¹⁴ As there have been no further developments or new introductions of other criteria, from here on we will look into the use of this criteria set in more detail. It is important to emphasize again at this stage that classification criteria are not diagnostic; clinical reasoning can and should always supersede fitting patients into a particular classification structure.¹⁵ The gold standard for diagnosis would still fall on the clinician to incorporate all the patient information, including laboratory, imaging, and clinical findings to complete the diagnosis.¹⁶

The ASAS criteria have 2 arms from which a classification can be made, an imaging and a clinical arm. In the imaging arm, the presence of MRI inflammation, which plays an important role in the rheumatologist's judgment to make a diagnosis of axial SpA, is a prominent factor, together with the classical presence of radiographic sacroiliitis. However, not all patients with axSpA have sacroiliitis on imaging (eg, in the validation study of the ASAS criteria,¹² 25% of the patients did not have radiographic or MRI evidence of sacroiliitis), underscoring that in clinical practice the rheumatologist bases his decision also on many other clinical and laboratory features, and that a diagnosis of axSpA can be made in the absence of sacroiliitis on imaging, including MRI sacroiliitis/inflammation.¹⁷ The clinical arm was intended for use where there was no imaging available (or where imaging is negative)¹⁸ and one therefore cannot assume or prove radiographic or inflammatory changes of the SIJs. Because of the strong association of sacroiliitis with axSpA, and because of high sensitivity and specificity, if sacroiliitis is present on imaging, only 1 other SpA feature needs to be present to classify a patient as having axSpA according to the ASAS criteria, whereas 2 additional features are required in the HLA-B27/clinical arm.¹² The features and requirements of each arm are listed in **Table 1**.

The new criteria for axSpA can be applied in patients with back pain for longer than 3 months with an onset before the age of 45 years.^{11,12} Of note, chronic back pain, not necessarily being IBP, is present as an entry criterion, reflecting that, in clinical practice, patients with noninflammatory chronic back pain may represent up to 20% to

Table 1**Published classification criteria for spondyloarthritis^a**

<i>mNY</i> <i>criteria</i> <i>for AS</i>	<i>Entry</i> <i>criterion:</i>	Imaging criterion plus ≥ 1 clinical criterion	<i>Imaging</i> <i>criterion:</i>	Radiographic sacroiliitis ^b	<i>Clinical</i> <i>criteria:</i>	<ul style="list-style-type: none"> • Low back pain and stiffness for more than 3 mo that improves with exercise, but is not relieved by rest • Limitation of motion of the lumbar spine in the sagittal and frontal planes • Limitation of chest expansion relative to normal values correlated for age and sex • Lumbar or dorsal pain during the night, or morning stiffness of lumbar or dorsal spine (1 point) • Asymmetric oligoarthritis (2 points) • Buttock pain (1 point), if affecting alternately the right or the left buttock (2 points) • Dactylitis (2 points) • Enthesitis (2 points) • Iritis (2 points) • Nongonococcal urethritis or cervicitis accompanying, or within 1 mo before, the onset of arthritis (1 point) • Acute diarrhea accompanying, or within 1 mo before, the onset of arthritis (1 point) • Presence or history of psoriasis, balanitis, or IBD (Crohn's/ulcerative colitis) (2 points) • Good response to NSAIDs in <48 h, or relapse of the pain in <48 h if NSAIDs discontinued (2 points) • Presence of HLA-B27, or familial history of AS, Reiter syndrome, uveitis, psoriasis, or chronic enterocolopathies (2 points)
<i>Amor</i> ⁹ <i>criteria</i> <i>for SpA</i>		Sum of points of items below must be ≥ 6 ; a sum of points ≥ 5 classifies for probable SpA		Radiographic sacroiliitis ^b (3 points)	<ul style="list-style-type: none"> • Buttock pain alternating between right and left gluteal areas • Urethritis, cervicitis, or acute diarrhea within 1 mo before arthritis • IBD • Psoriasis • Positive family history 	
<i>ESSG</i> <i>criteria</i> <i>for SpA</i>		IBP (modified Calin) ²⁰ or synovitis (asymmetric or predominantly in the lower limbs), and ≥ 1 clinical or radiological criterion		Radiographic sacroiliitis ^b		

(continued on next page)

Table 1
(continued)

<i>ASCBPAS</i> <i>criteria</i> <i>for axSpA</i>	CBP (≥ 3 mo) with an onset < 45 y of age and:	(a) Imaging criterion plus ≥ 1 the clinical criteria or	(b) Positive HLA-B27 plus ≥ 2 other clinical criteria	Radiographic sacroiliitis ^b or MRI sacroiliitis ^c	<ul style="list-style-type: none"> • IBP (ASAS)⁶⁸ • Arthritis • Enthesitis (heel) • Uveitis • Dactylitis • Psoriasis • Crohn's/ulcerative colitis • Increased CRP • Good response to NSAIDs • Family history of SpA • HLA-B27
<i>ASAS</i> <i>criteria</i> <i>for pSpA</i>	Peripheral arthritis, enthesitis, or dactylitis and:	(a) Imaging criterion or ≥ 1 clinical SpA feature from group A or	(b) ≥ 2 other clinical SpA features from group B	Radiographic sacroiliitis ^b or MRI sacroiliitis ^c	<ul style="list-style-type: none"> Group A • Uveitis • Psoriasis • Crohn's/ulcerative colitis • Preceding infection • HLA-B27 Group B • Arthritis • Enthesitis • Dactylitis • IBP ever (ASAS)⁶⁸ • Family history for SpA

Abbreviations: AS, ankylosing spondylitis; ASAS, assessment of spondyloarthritis international society; axSpA, axial spondyloarthritis; CBP, chronic back pain; CRP, C-reactive protein; ESSG, European Spondyloarthropathy Study Group; HLA, human leukocyte antigen; IBD, inflammatory bowel disease; IBP, inflammatory back pain; mNY, modified New York; MRI, magnetic resonance imaging; NSAIDs, nonsteroidal anti-inflammatory drugs; pSpA, peripheral spondyloarthritis; SpA, spondyloarthritis.

^a Please note that the definition of IBP and some SpA features varies between different criteria sets; for details please consult the original publications.

^b Defined as radiographic sacroiliitis grade ≥ 2 bilaterally or grade 3 to 4 unilaterally; grade 0 = normal; grade 1 = suspicious changes; grade 2 = minimum abnormality (small localized areas with erosion or sclerosis, without alteration in the joint width); grade 3 = unequivocal abnormality (moderate or advanced sacroiliitis with erosions, evidence of sclerosis, widening, narrowing, or partial ankyloses); grade 4 = severe abnormality (total ankyloses).

^c Defined as bone marrow edema (short tau inversion recovery sequence) or osteitis (T1 postgadolinium sequence) highly suggestive of SpA, clearly present and located in the typical anatomic areas (subchondral or periarticular bone marrow); if there is only one signal (lesion) per MRI slice suggesting active inflammation, the lesion should be present on at least 2 consecutive slices; if there is more than one signal (lesion) on a single slice, one slice may be sufficient.

Data from Refs. ^{9,20,68}

30% of patients with axSpA, whereas IBP can be observed in 20% to 25% of patients with noninflammatory (mechanical) causes of chronic back pain.^{19–21} Detailed analysis in the ASAS axSpA validation study also demonstrated that IBP as an entry criterion did not perform better than chronic back pain.¹² However, the presence of IBP is an important symptom that should prompt further diagnostic tests for axSpA. Age is also an important factor in the entry criteria, reflecting that complaints associated with axSpA usually start in the second or third decade of life, and by the age of 45 years, more than 95% of patients are symptomatic.²² Importantly, evidence suggests that disease activity, comorbidities, and treatment responses are similar for nr-axSpA and r-axSpA.²³

A CRITICAL VIEW OF THE COMPONENTS OF THE ASSESSMENT OF SPONDYLOARTHRITIS INTERNATIONAL SOCIETY CLASSIFICATION CRITERIA FOR AXIAL SPONDYLOARTHRITIS

Under the imaging arm it is first prudent to consider the aspects of positivity. The primary issue being a low interrater and intrarater reliability of radiograph interpretation.²⁴ Within the skein of MRI interpretation it is important to consider the impact of mechanical elements on an interpretation of sacroiliitis suggestive of axSpA. Bone marrow edema (BMO)/osteitis is not unique to inflammatory conditions, it has been shown to be present in postpartum women (with and without pelvic pain), cleaning staff, long distance runners, soldiers, athletes, and healthy individuals.^{25–28} However, differences in the level of BMO of the axSpA group compared with the mechanical group have been reported, with axSpA having a tendency to higher levels of inflammation and presence of erosions, ankylosis, and fat infiltration. The misinterpretation of inflammation has been explored further with extensive and intermediate inflammation having a higher odds ratio of developing erosions at the SIJ after 4 years,²⁹ leading to the conclusion that limited BMO may be due to transient mechanical force, but extensive BMO seems to have a higher correlation to pathologic changes. With extensive changes having more than 1 cm depth of inflammation.

The performance of MRI in the diagnosis of axSpA was recently systematically reviewed by Jones and colleagues.³⁰ The authors found that, at the SIJ level, BMO is the most sensitive and specific individual lesion. Structural lesions, including fat deposition, have moderate sensitivity and specificity, whereas erosions demonstrate good specificity but relatively poor sensitivity (with the caveat that some of the studies used high fixed specificity values, which may have added a negative impact on sensitivity values). Combination of BMO and erosions, or BMO and fat deposition, yielded higher sensitivity and specificity than BMO alone. Predefined numbers of lesions or cutoffs have also been analyzed and suggest that BMO in ≥ 3 quadrants and erosions in ≥ 3 quadrants show high sensitivity and specificity and the presence of 3 to 5 fatty lesions also yield good sensitivity. However, further studies are required to validate these findings. In the spine, studies investigating the value of corner inflammatory lesions found moderate sensitivity and specificity, whereas spinal fatty lesions were found to have relatively poor sensitivity and specificity. Although the results suggest that spinal lesions alone are unlikely to have sufficient diagnostic performance for use in axSpA, these lesions might be useful in combination with features identified on SIJ MRI (an area that requires further research).

The systematic literature review by Jones and colleagues³⁰ served as evidence to support recommendations for acquisition and interpretation of MRI of the spine and SIJs in the assessment of patients with suspected axSpA,³¹ including recommended sequences, anatomic coverage, acquisition parameters, and interpretation of active

and structural MRI lesions. The full list of recommendations can be found in the article but 2 key messages should be highlighted (1) imaging cannot be viewed in isolation and needs to be interpreted in the context of clinical presentation and results of laboratory investigations and (2) the full range and combination of active and structural lesions of the SIJs and spine should be taken into account when deciding if the MRI scan is suggestive of axSpA or not (ie, contextual interpretation of active and structural lesions is key to enhancing diagnostic utility of MRI in patients with suspected axSpA).

HLA-B27 positivity is given a high level of weighting in the classification of axSpA according to ASAS; however, due to it requiring 2 SpA features and imaging only requiring 1 feature, imaging takes precedence. This is further reflected as there is also an increased prevalence of HLA-B27 in the r-axSpA group compared with the nr-axSpA group.^{32,33} HLA-B27 is positive in 85% to 95% of patients with r-axSpA and in 75% to 85% of patients with nr-axSpA.^{34–36}

One classification feature of SpA is a positive family history of the disease. The question here is what is the relevance? If we have further information already, such as HLA-B27 status, does a family history assist our diagnosis further? Which SpA feature is more relevant to a diagnosis of axSpA? Van Lunteren and colleagues³⁷ looked at 3 cohorts of patients with axSpA to identify if a family history was relevant if the HLA-B27 status was known. They found that there was no consensus across all 3 groups. A family history of AS was relevant in the ASAS cohort but not in the *DEvenir des Spondyloarthropathies Indifférenciées Récentes* ([DESIR] a longitudinal French cohort, including patients aged 18–50 years with IBP)³⁸ or the European SPondyloArthritis Caught Early ([SPACE] an inception cohort, including patients aged ≥ 16 years with chronic back pain from the Netherlands, Italy, Norway, or Sweden)³⁹ cohorts; equally, family history of acute anterior uveitis (AAU) was associated with a diagnosis in the SPACE cohort but not the ASAS or DESIR groups. This indicates that HLA-B27 has a greater relation to a positive diagnosis of axSpA than a positive family history does.

Further work into a positive family history has tried to identify which diagnosis in the SpA family has a greater probability of association with axSpA.¹⁶ A positive correlation was seen between a family history of AS or anterior uveitis, when correlated with HLA-B27 status. Reactive arthritis, IBD, or psoriasis did not contribute to a diagnosis of axSpA. Therefore, when considering family history as a positive SpA feature to cement the patient's diagnosis, it would seem that there is a hierarchy to consider. There also seems to be some evidence that using HLA-B27 status, if known, is more useful.¹⁶

An increased C-reactive protein (CRP) is an important component. CRP can be increased in up to 40% of patients with axSpA, and is more frequently increased in patients with r-axSpA than in patients with nr-axSpA.⁴⁰ Therefore, its sensitivity in axSpA can be, and has been questioned.³⁴ However, a positive CRP is one of the associated risk factors for developing radiographic progression.⁶ CRP is also a component of the Ankylosing Spondylitis Disease Activity Score, a composite measure of disease activity.^{41–43} On the basis that there is less positivity in nr-axSpA than r-axSpA and a higher distribution of women in the nr-axSpA group than in the r-axSpA group,¹⁸ is this a case where women with the disease tend to have lower CRP's than men? If so, it raises the question, when incorporating CRP in the classification criteria, that there will be a higher CRP in the r-axSpA group than in the nr-axSpA group.

Dactylitis is a component that can increase the susceptibility of axSpA and can occur as a peripheral manifestation. The ESPeranza cohort, a cohort of patients from Spain, assessed the frequency of dactylitis within the SpA group and found an

incidence of 9.5%.⁴⁴ This is slightly higher than those found in the SPACE cohort.³⁹ Although dactylitis is associated with peripheral SpA it has been identified that 15% of all patients who had a diagnosis of dactylitis had axial and not peripheral SpA.⁴⁴

Enthesitis is another peripheral manifestation that has been highlighted as an aspect contributing to classification; it is a straightforward component to assess in the clinic. The ASAS classification criteria only include enthesitis in the heel with their criteria, and do not include others; this has been further supported with work by Ozsoy-Unubol and Yagci⁴⁵ who completed ultrasound assessments on 9 enthesitis points in a range of patients with axSpA and mechanical back pain. Their assessment was of Achilles tendon; plantar fascia; patella tendon, distal and proximal; quadriceps; tibialis anterior; triceps; common flexor tendon, and the common extensor tendon. They identified that the most common site for power Doppler signal and calcification (a finding with diagnostic value⁴⁶) was the Achilles and patella tendon, with actually the distal and proximal patella tendon having the highest incidence in the axSpA group. The issue, however, is that these patellar areas also showed the highest incidences in the mechanical back pain group, whereas enthesitis of the Achilles tendon was prevalent in 40% of the axSpA group but was only present in 6.7% of the mechanical back pain group. This highlights many things: primarily that enthesitis can be inflammatory or mechanical; therefore enthesitis in isolation should be viewed with caution because this could be a mechanical cause from changes in activity or exercise loads, and that enthesitis at the patella, as long as not mechanical, can add significance to the diagnosis of axSpA.

The other issue is one of concomitant fibromyalgia. Areas of enthesitis that are assessed in axSpA are similar to the pain point areas assessed when considering a diagnosis of fibromyalgia⁴⁷; therefore, multiple positive “enthesitis” sites on a patient should be assessed with caution for what could be an underlying fibromyalgia, which can have similarities to the presentation of axSpA.^{48–51} The use of ultrasonography for assessment of enthesitis may reduce the number of false positives of clinical identification of pain without a pathologic condition in the tendon.⁵² However, it is recognized that not every facility will have access to an ultrasound assessment in clinic and instead will need to wait for a radiology review, which could further delay the diagnostic work up.

Uveitis is also an SpA feature, in this case an EAM; up to 33% of patients with axSpA will develop uveitis,⁵³ 50% of those who have suffered with uveitis will go onto develop recurrent disease.⁵⁴ Uveitis can be classified as infectious, noninfectious (associated with axSpA), or masquerade.⁵⁵ The standardization of uveitis is then descriptive of anatomic location being anterior, intermediate, posterior, or panuveitis.⁵⁶ It has been shown that 85% of uveitis in patients with SpA is anterior.⁵⁷ The other aspects to uveitis that make it so useful to assist with classification is that the age of onset is between 20 and 59 years⁵⁸; although this is higher than that for axSpA it is similar and therefore one could assume that they can go together at both diagnosis and within the clinical follow-up setting. Interestingly, HLA-B27-positive uveitis presents as a nongranulomatous AAU⁵⁹; this has led to the development of studies to identify those patients with AAU and HLA-B27 positivity to try and identify if they have an underlying axSpA.⁶⁰

There is a close association between SpA and IBD. There is a growing body of evidence that suggests that the IBD profile and that of SpA are in fact one and the same.^{61–63} The reason for this could be that the gut is the primary interaction site between the host immune system and microorganisms.⁶² The “trigger” of axSpA could be that following inflammation in the gut there is a change to the adaptive immune system and that the new “normal” of antibody status has changed from that previously

accepted, therefore triggering an autoimmune response.⁶⁴ Both diseases also share the HLA-B27 antigen, which is why 6.5% of SpA patients will develop IBD within 5 years from diagnosis, and 30% of patients with IBD will develop SpA.⁶⁴ In addition, synovial T cells could be developed from the gut because the same macrophages have been found in the gut as in the synovium.⁶³ Clearly these 2 conditions overlap a great deal and should each be taken into consideration when diagnosing and managing the other, particularly because 46.2% of patients with SpA without bowel symptoms or disease had inflammation in the bowel on colonoscopy.⁶⁵

The link between psoriasis and the SpA spectrum is clear.⁶⁶ The question is the relevance of psoriasis in axial disease. Is it a different pathology to psoriatic spondylitis? Is axSpA the axial involvement one of the manifestations of a peripheral disease? There is currently no widely accepted definition of axial involvement in PsA. Although there might be differences in efficacy of certain drugs/mechanisms of action for peripheral and axial manifestations of the disease, ASAS and the Group for Research and Assessment of Psoriasis and Psoriatic Arthritis have agreed to develop a consensus definition of axial involvement in PsA to be used for research purposes. Such a definition will serve primarily as a classification tool to be applied to patients with clinically diagnosed PsA to build a homogeneous group of patients for inclusion in noninterventional or interventional studies.

THE CLASSIFICATION OF AXIAL SPONDYLOARTHRITIS INCEPTION COHORT STUDY

In October 2013, after a 2-day meeting of the Arthritis Advisory Committee, a panel of experts who make recommendations to the US Food and Drug Administration (FDA), the FDA rejected the application by 2 manufacturers of tumor necrosis factor blockers (adalimumab and certolizumab) for the treatment of nr-axSpA. One of the reasons was concern from the FDA regarding the specificity of the ASAS axSpA classification criteria when erroneously used for diagnostic purposes. This has led to a delay in US regulatory approval for nr-axSpA compared with the EMA (first EMA approval in 2012; first FDA approval in 2019, after the conduct of new phase 3 clinical trials for nr-axSpA recommended by the FDA).

In 2017, a meta-analysis showed that the ASAS axSpA criteria performed well in patients included in 7 cohorts from various geographic areas.⁶⁷ The meta-analysis included 4990 patients in total, generating a very high pooled sensitivity and specificity (82% and 87%, respectively) for the axSpA criteria, with little variation across studies. The pooled sensitivity of the imaging arm (\pm clinical arm) and clinical arm (\pm imaging arm) was 57% and 49%, respectively (26% and 23% when considering patients fulfilling each arm exclusively). High estimates of pooled specificity were found for both arms, irrespective of the definition (range, 92%–97%). However, the positive likelihood ratio of the imaging arm only was higher when compared with the clinical arm only (9.6 vs 3.6). It should be noted that the criteria's performance also depends on the prevalence of SpA in the underlying population (pretest probability).

Despite these results, the validity of the ASAS axSpA criteria has been questioned. Hence, there has been the development of the classification of axial spondyloarthritis inception cohort study (NCT03993847). This is aimed at identifying the current sensitivity and specificity of the classification criteria worldwide. This longitudinal study is aiming to recruit 500 patients from North America (a minimum of 300 from the United States) and 500 from outside North America. It is an inception cohort wherein those patients referred to rheumatology with undiagnosed back pain of ≥ 3 months duration with onset ≤ 45 years will be recruited. The primary objective of the trial is to validate the performance of the current ASAS classification criteria; if a specificity of $\geq 90\%$ and

a sensitivity of $\geq 75\%$ of the original ASAS criteria will be found in the study, the ASAS criteria will be considered validated and no further analyses will be done. Only if the primary objective is not met, will refinements of the criteria be made and tested. A secondary objective is to identify confidence in ascertainment of (active) sacroiliitis by MRI. The tertiary outcome is to determine the predictive value of the criteria over a 5-year follow-up period.

SUMMARY

This review aimed to highlight issues about the diagnosis and classification of axSpA, namely the issue of over diagnosis; how mechanical factors can play a large role in altered imaging on MRI that could alter the outcome of the imaging arm. In addition, we have highlighted that caution should be used when considering certain components of the criteria to classify the disease, especially under the clinical arm. For example, although clearly enthesitis has its place and, when used appropriately, it can alter the clinician's decision, it has been shown that the exact weighting of this should be carefully considered.

We are working in a time when medical advances mean that both assessment and treatment are continually progressing. If one treatment is not efficacious there are a wider range of alternative treatment options and less barriers, as these become more financially competitive. Therefore, we must be clear that the correct diagnosis has been made and that we, as clinicians, are not "jumping" to an incorrect diagnosis through poorly understood or misinterpreted findings as diagnostics. This is a time to be excited about, but also cautious with, the progress in identifying and diagnosing, this complex and often missed spectrum of diseases, particularly in a time when there are more Allied Health Professionals (AHPs) working in primary and secondary care and will be instrumental in the diagnosis of such conditions.

In the future in this condition, work should be carried out to further educate health care providers about SpA and its features, and how the specificity of imaging can impact diagnosis and what role EAMs play in this. The diagnosis of axSpA is a clinical diagnosis and classification criteria are not aimed to be diagnostic tools. The split between r-axSpA and nr-axSpA is artificial and we should move toward the unifying concept of axSpA. Our understanding of genetics, biomarkers, and immunopathophenotypes will drive further refinement of axSpA classification criteria.

It is important that we diagnose this potentially disabling condition early. What should be developed is a way to stratify these patients into the correct diagnosis. That could, and should, include further identification of the susceptibility of the condition within the broader hospital setting and those clinicians assessing and diagnosing those patients with SpA features, such as dermatology, gastroenterology, and ophthalmology, to have a lower threshold for referring their patients for an opinion from rheumatology if they present with chronic spinal/buttock pain. Equally in primary care more attention should be sought to identify those patients with other clinical manifestations and raising awareness to their care providers; whether this be General Practitioners or the ever growing and developing role of AHPs fulfilling these roles in the community.

ACKNOWLEDGMENTS

P.M. Machado is supported by the National Institute for Health Research (NIHR) University College London Hospitals NHS Foundation Trust (UCLH) Biomedical Research Centre (BRC). The views expressed are those of the authors and not

necessarily those of the (UK) National Health Service (NHS), the NIHR, or the (UK) Department of Health.

DISCLOSURE

R.J. Hayward has nothing to disclose. P.M. Machado has received consulting/speaker's fees from Abbvie, BMS, Celgene, Eli Lilly, Janssen, MSD, Novartis, Pfizer, Roche, and UCB.

REFERENCES

1. Sieper J, Poddubnyy D. Axial spondyloarthritis. *Lancet* 2017;390(10089):73–84.
2. van Tubergen A, Weber U. Diagnosis and classification in spondyloarthritis: identifying a chameleon. *Nat Rev Rheumatol* 2012;8(5):253–61.
3. Stolwijk C, van Onna M, Boonen A, et al. Global prevalence of spondyloarthritis: a systematic review and meta-regression analysis. *Arthritis Care Res (Hoboken)* 2016;68(9):1320–31.
4. Dubreuil M, Deodhar AA. Axial spondyloarthritis classification criteria: the debate continues. *Curr Opin Rheumatol* 2017;29(4):317–22.
5. Proft F, Poddubnyy D. Ankylosing spondylitis and axial spondyloarthritis: recent insights and impact of new classification criteria. *Ther Adv Musculoskelet Dis* 2018;10(5–6):129–39.
6. Malaviya AN, Rawat R, Agrawal N, et al. The nonradiographic axial spondyloarthritis, the radiographic axial spondyloarthritis, and ankylosing spondylitis: the tangled skein of rheumatology. *Int J Rheumatol* 2017;2017:1824794.
7. van der Linden S, Valkenburg HA, Cats A. Evaluation of diagnostic criteria for ankylosing spondylitis. A proposal for modification of the New York criteria. *Arthritis Rheum* 1984;27(4):361–8.
8. van Tubergen A, Heuft-Dorenbosch L, Schulpen G, et al. Radiographic assessment of sacroiliitis by radiologists and rheumatologists: does training improve quality? *Ann Rheum Dis* 2003;62(6):519–25.
9. Amor B, Dougados M, Mijiyawa M. Criteria of the classification of spondylarthropathies. *Rev Rhum Mal Osteoartic* 1990;57(2):85–9 [in French].
10. Dougados M, van der Linden S, Juhlin R, et al. The European Spondylarthropathy Study Group preliminary criteria for the classification of spondylarthropathy. *Arthritis Rheum* 1991;34(10):1218–27.
11. Rudwaleit M, Landewé R, van der Heijde D, et al. The development of Assessment of SpondyloArthritis International Society classification criteria for axial spondyloarthritis (part I): classification of paper patients by expert opinion including uncertainty appraisal. *Ann Rheum Dis* 2009;68(6):770–6.
12. Rudwaleit M, van der Heijde D, Landewé R, et al. The development of Assessment of SpondyloArthritis International Society classification criteria for axial spondyloarthritis (part II): validation and final selection. *Ann Rheum Dis* 2009;68(6):777–83.
13. Bakker P, Molto A, Etcheto A, et al. The performance of different classification criteria sets for spondyloarthritis in the worldwide ASAS-COMOSPA study. *Arthritis Res Ther* 2017;19(1):96.
14. Sepriano A, Landewé R, van der Heijde D, et al. Predictive validity of the ASAS classification criteria for axial and peripheral spondyloarthritis after follow-up in the ASAS cohort: a final analysis. *Ann Rheum Dis* 2016;75(6):1034–42.

15. Deodhar A, Strand V, Kay J, et al. The term 'non-radiographic axial spondyloarthritis' is much more important to classify than to diagnose patients with axial spondyloarthritis. *Ann Rheum Dis* 2016;75(5):791–4.
16. Ez-Zaitouni Z, Hilkens A, Gossec L, et al. Is the current ASAS expert definition of a positive family history useful in identifying axial spondyloarthritis? Results from the SPACE and DESIR cohorts. *Arthritis Res Ther* 2017;19(1):118.
17. van der Heijde D, Rudwaleit M, Landewe RB, et al. Justification for including MRI as a tool in the diagnosis of axial SpA. *Nat Rev Rheumatol* 2010;6(11):670–2.
18. Ghosh N, Ruderman EM. Nonradiographic axial spondyloarthritis: clinical and therapeutic relevance. *Arthritis Res Ther* 2017;19(1):286.
19. Rudwaleit M, Metter A, Listing J, et al. Inflammatory back pain in ankylosing spondylitis: a reassessment of the clinical history for application as classification and diagnostic criteria. *Arthritis Rheum* 2006;54(2):569–78.
20. Calin A, Porta J, Fries JF, et al. Clinical history as a screening test for ankylosing spondylitis. *JAMA* 1977;237(24):2613–4.
21. Rudwaleit M, van der Heijde D, Khan MA, et al. How to diagnose axial spondyloarthritis early. *Ann Rheum Dis* 2004;63(5):535–43.
22. van den Berg R, van der Heijde DM. How should we diagnose spondyloarthritis according to the ASAS classification criteria: a guide for practicing physicians. *Pol Arch Med Wewn* 2010;120(11):452–7.
23. Zhao SS, Ermann J, Xu C, et al. Comparison of comorbidities and treatment between ankylosing spondylitis and non-radiographic axial spondyloarthritis in the United States. *Rheumatology (Oxford)* 2019;58(11):2025–30.
24. Molto A, Gossec L, Lefèvre-Colau MM, et al. Evaluation of the performances of 'typical' imaging abnormalities of axial spondyloarthritis: results of the cross-sectional ILOS-DESIR study. *RMD Open* 2019;5(1):e000918.
25. Seven S, Østergaard M, Morsel-Carlsen L, et al. MRI lesions in the sacroiliac joints for differentiation of patients with axial spondyloarthritis from postpartum women, patients with disc herniation, cleaning staff, long distance runners and healthy persons—a prospective cross-sectional study of 204 participants. *Arthritis Rheumatol* 2019;71(12):2034–46.
26. de Winter J, de Hooge M, van de Sande M, et al. Magnetic resonance imaging of the sacroiliac joints indicating sacroiliitis according to the assessment of spondyloarthritis international society definition in healthy individuals, runners, and women with postpartum back pain. *Arthritis Rheumatol* 2018;70(7):1042–8.
27. Varkas G, de Hooge M, Renson T, et al. Effect of mechanical stress on magnetic resonance imaging of the sacroiliac joints: assessment of military recruits by magnetic resonance imaging study. *Rheumatology (Oxford)* 2018;57(3):588.
28. Weber U, Jurik AG, Zejden A, et al. Frequency and anatomic distribution of magnetic resonance imaging features in the sacroiliac joints of young athletes: exploring "background noise" toward a data-driven definition of sacroiliitis in early spondyloarthritis. *Arthritis Rheumatol* 2018;70(5):736–45.
29. Arnbak B, Jensen TS, Schiøtz-Christensen B, et al. What level of inflammation leads to structural damage in the sacroiliac joints? A four-year magnetic resonance imaging follow-up study of low back pain patients. *Arthritis Rheumatol* 2019;71(12):2027–33.
30. Jones A, Bray TJP, Mandl P, et al. Performance of magnetic resonance imaging in the diagnosis of axial spondyloarthritis: a systematic literature review. *Rheumatology (Oxford)* 2019;58(11):1955–65.

31. Bray TJP, Jones A, Bennett AN, et al. Recommendations for acquisition and interpretation of MRI of the spine and sacroiliac joints in the diagnosis of axial spondyloarthritis in the UK. *Rheumatology (Oxford)* 2019;58(10):1831–8.
32. Song IH, Weiß A, Hermann KG, et al. Similar response rates in patients with ankylosing spondylitis and non-radiographic axial spondyloarthritis after 1 year of treatment with etanercept: results from the ESTHER trial. *Ann Rheum Dis* 2013; 72(6):823–5.
33. Chimenti MS, Conigliaro P, Navarini L, et al. Demographic and clinical differences between ankylosing spondylitis and non-radiographic axial spondyloarthritis: results from a multicentre retrospective study in the Lazio region of Italy. *Clin Exp Rheumatol* 2019;38(1):88–93.
34. Kiltz U, Baraliakos X, Karakostas P, et al. Do patients with non-radiographic axial spondylarthritis differ from patients with ankylosing spondylitis? *Arthritis Care Res (Hoboken)* 2012;64(9):1415–22.
35. Mathieu A, Paladini F, Vacca A, et al. The interplay between the geographic distribution of HLA-B27 alleles and their role in infectious and autoimmune diseases: a unifying hypothesis. *Autoimmun Rev* 2009;8(5):420–5.
36. Sieper J, van der Heijde D. Review: Nonradiographic axial spondyloarthritis: new definition of an old disease? *Arthritis Rheum* 2013;65(3):543–51.
37. van Lunteren M, van der Heijde D, Sepriano A, et al. Is a positive family history of spondyloarthritis relevant for diagnosing axial spondyloarthritis once HLA-B27 status is known? *Rheumatology (Oxford)* 2019;58(9):1649–54.
38. Dougados M, d'Agostino MA, Benessiano J, et al. The DESIR cohort: a 10-year follow-up of early inflammatory back pain in France: study design and baseline characteristics of the 708 recruited patients. *Joint Bone Spine* 2011;78(6): 598–603.
39. van den Berg R, de Hooge M, van Gaalen F, et al. Percentage of patients with spondyloarthritis in patients referred because of chronic back pain and performance of classification criteria: experience from the Spondyloarthritis Caught Early (SPACE) cohort. *Rheumatology (Oxford)* 2013;52(8):1492–9.
40. Rudwaleit M, Haibel H, Baraliakos X, et al. The early disease stage in axial spondylarthritis: results from the German Spondyloarthritis Inception Cohort. *Arthritis Rheum* 2009;60(3):717–27.
41. Machado PM, Landewe R, Heijde DV. Assessment of SpondyloArthritis international S. Ankylosing Spondylitis Disease Activity Score (ASDAS): 2018 update of the nomenclature for disease activity states. *Ann Rheum Dis* 2018;77(10): 1539–40.
42. Machado P, Landewe R. Spondyloarthritis: is it time to replace BASDAI with ASDAS? *Nat Rev Rheumatol* 2013;9(7):388–90.
43. Machado P, Landewe R, Lie E, et al. Ankylosing Spondylitis Disease Activity Score (ASDAS): defining cut-off values for disease activity states and improvement scores. *Ann Rheum Dis* 2011;70(1):47–53.
44. Tévar-Sánchez MI, Navarro-Compán V, Aznar JJ, et al. Prevalence and characteristics associated with dactylitis in patients with early spondyloarthritis: results from the ESPERanza cohort. *Clin Exp Rheumatol* 2018;36(5):879–83.
45. Ozsoy-Unubol T, Yagci I. Is ultrasonographic enthesitis evaluation helpful for diagnosis of non-radiographic axial spondyloarthritis? *Rheumatol Int* 2018; 38(11):2053–61.
46. Eder L, Barzilai M, Peled N, et al. The use of ultrasound for the assessment of enthesitis in patients with spondyloarthritis. *Clin Radiol* 2013;68(3):219–23.

47. Wolfe F, Clauw DJ, Fitzcharles MA, et al. 2016 revisions to the 2010/2011 fibromyalgia diagnostic criteria. *Semin Arthritis Rheum* 2016;46(3):319–29.
48. Almodovar R, Carmona L, Zarco P, et al. Fibromyalgia in patients with ankylosing spondylitis: prevalence and utility of the measures of activity, function and radiological damage. *Clin Exp Rheumatol* 2010;28(6 Suppl 63):S33–9.
49. Roussou E, Ciurtin C. Clinical overlap between fibromyalgia tender points and enthesitis sites in patients with spondyloarthritis who present with inflammatory back pain. *Clin Exp Rheumatol* 2012;30(6 Suppl 74):24–30.
50. Salaffi F, De Angelis R, Carotti M, et al. Fibromyalgia in patients with axial spondyloarthritis: epidemiological profile and effect on measures of disease activity. *Rheumatol Int* 2014;34(8):1103–10.
51. Dougados M, Logeart I, Szumski A, et al. Evaluation of whether extremely high enthesitis or Bath Ankylosing Spondylitis Disease Activity Index (BASDAI) scores suggest fibromyalgia and confound the anti-TNF response in early non-radiographic axial spondyloarthritis. *Clin Exp Rheumatol* 2017;35:50–3. Suppl 105(3).
52. Gandjbakhch F, Terslev L, Joshua F, et al. Ultrasound in the evaluation of enthesitis: status and perspectives. *Arthritis Res Ther* 2011;13(6):R188.
53. Bacchiega ABS, Balbi GGM, Ochtrop MLG, et al. Ocular involvement in patients with spondyloarthritis. *Rheumatology (Oxford)* 2017;56(12):2060–7.
54. Zeboulon N, Dougados M, Gossec L. Prevalence and characteristics of uveitis in the spondyloarthropathies: a systematic literature review. *Ann Rheum Dis* 2008;67(7):955–9.
55. Okada AA, Jabs DA. The standardization of uveitis nomenclature project: the future is here. *JAMA Ophthalmol* 2013;131(6):787–9.
56. Jabs DA, Nussenblatt RB, Rosenbaum JT, et al. Standardization of uveitis nomenclature for reporting clinical data. Results of the First International Workshop. *Am J Ophthalmol* 2005;140(3):509–16.
57. Gritz DC, Wong IG. Incidence and prevalence of uveitis in Northern California; the Northern California Epidemiology of Uveitis Study. *Ophthalmology* 2004;111(3):491–500 [discussion: 500].
58. Pasadhika S, Rosenbaum JT. Update on the use of systemic biologic agents in the treatment of noninfectious uveitis. *Biologics* 2014;8:67–81.
59. Biggioggero M, Crotti C, Becciolini A, et al. The management of acute anterior uveitis complicating spondyloarthritis: present and future. *Biomed Res Int* 2018;2018:9460187.
60. O'Rourke M, Haroon M, Alfarasy S, et al. The effect of anterior uveitis and previously undiagnosed spondyloarthritis: results from the DUET cohort. *J Rheumatol* 2017;44(9):1347–54.
61. Scarpa R, del Puente A, D'Arienzo A, et al. The arthritis of ulcerative colitis: clinical and genetic aspects. *J Rheumatol* 1992;19(3):373–7.
62. Round JL, Mazmanian SK. The gut microbiota shapes intestinal immune responses during health and disease. *Nat Rev Immunol* 2009;9(5):313–23.
63. Baeten D, Demetter P, Cuvelier CA, et al. Macrophages expressing the scavenger receptor CD163: a link between immune alterations of the gut and synovial inflammation in spondyloarthropathy. *J Pathol* 2002;196(3):343–50.
64. Asquith M, Elewaut D, Lin P, et al. The role of the gut and microbes in the pathogenesis of spondyloarthritis. *Best Pract Res Clin Rheumatol* 2014;28(5):687–702.

65. Van Praet L, Van den Bosch FE, Jacques P, et al. Microscopic gut inflammation in axial spondyloarthritis: a multiparametric predictive model. *Ann Rheum Dis* 2013; 72(3):414–7.
66. Leung YY, Ogdie A, Orbai AM, et al. Classification and outcome measures for psoriatic arthritis. *Front Med (Lausanne)* 2018;5:246.
67. Sepriano A, Rubio R, Ramiro S, et al. Performance of the ASAS classification criteria for axial and peripheral spondyloarthritis: a systematic literature review and meta-analysis. *Ann Rheum Dis* 2017;76(5):886–90.
68. Sieper J, van der Heijde D, Landewe R, et al. New criteria for inflammatory back pain in patients with chronic back pain: a real patient exercise by experts from the Assessment of SpondyloArthritis international Society (ASAS). *Ann Rheum Dis* 2009;68(6):784–8.
69. Rudwaleit M, van der Heijde D, Landewe R, et al. The Assessment of SpondyloArthritis International Society classification criteria for peripheral spondyloarthritis and for spondyloarthritis in general. *Ann Rheum Dis* 2011;70(1):25–31.
70. Rudwaleit M, Jurik AG, Hermann KG, et al. Defining active sacroiliitis on magnetic resonance imaging (MRI) for classification of axial spondyloarthritis: a consensual approach by the ASAS/OMERACT MRI group. *Ann Rheum Dis* 2009; 68(10):1520–7.
71. Lambert RG, Bakker PA, van der Heijde D, et al. Defining active sacroiliitis on MRI for classification of axial spondyloarthritis: update by the ASAS MRI working group. *Ann Rheum Dis* 2016;75(11):1958–63.
72. Hermann KG, Baraliakos X, van der Heijde DM, et al. Descriptions of spinal MRI lesions and definition of a positive MRI of the spine in axial spondyloarthritis: a consensual approach by the ASAS/OMERACT MRI study group. *Ann Rheum Dis* 2012;71(8):1278–88.
73. Maksymowych WP, Lambert RG, Ostergaard M, et al. MRI lesions in the sacroiliac joints of patients with spondyloarthritis: an update of definitions and validation by the ASAS MRI working group. *Ann Rheum Dis* 2019;78(11):1550–8.