

Conflicts of interest: None disclosed.

IRB approval status: Not applicable.

Correspondence to: Robert Staver, MD, MBA,
Division of Dermatology, Cambridge Health
Alliance, 33 Tower St, Somerville, MA 02135

E-mail: Rstaver@cballiance.org

REFERENCES

1. Hubiche T, Le Duff F, Chiaverini C, Giordanengo V, Passeron T. Negative SARS-CoV-2 PCR in patients with chilblain-like lesions. *Lancet Infect Dis*. 2020. [https://doi.org/10.1016/S1473-3099\(20\)30518-1](https://doi.org/10.1016/S1473-3099(20)30518-1).
2. Freeman EE, McMahon DE, Lipoff JB, et al. Pernio-like skin lesions associated with COVID-19: a case series of 318 patients from 8 countries. *J Am Acad Dermatol*. 2020;83(2):486-492.
3. Piccolo V, Bassi A. Acral findings during the COVID-19 outbreak: chilblain-like lesions should be preferred to acro-ischemic lesions. *J Am Acad Dermatol*. 2020;83(3):e231.
4. Colmenero I, Santonja C, Alonso-Riaño M, et al. SARS-CoV-2 endothelial infection causes COVID-19 chilblains: histopathological, immunohistochemical and ultrastructural study of 7 paediatric cases. *Br J Dermatol*. 2020. <https://doi.org/10.1111/bjd.19327>.
5. Long QX, Liu BZ, Deng HJ, et al. Antibody responses to SARS-CoV-2 in patients with COVID-19. *Nat Med*. 2020;26(6):845-848.

<https://doi.org/10.1016/j.jaad.2020.08.049>

Skin is a potential host of SARS-CoV-2: A clinical, single-cell transcriptome- profiling and histologic study



To the Editor: The novel coronavirus disease 2019 (COVID-19) caused by severe acute respiratory syndrome coronavirus 2 (SARS-CoV-2) has spread worldwide. The lung is the main target organ of SARS-CoV-2; however, extrapulmonary virus distribution¹ has been observed. Skin manifestations, including skin rashes, morbilliform exanthema and chilblains,²⁻⁴ have recently been reported as possible presentations in patients with COVID-19. However, the number of such cases has been relatively small, and whether SARS-CoV-2 might infect injured skin and cause COVID-19 is still unknown. We therefore examined whether the skin is a potential host of SARS-CoV-2 by analyzing clinical, histologic, and single-cell transcriptome data.

This retrospective analysis included 3128 patients with laboratory-confirmed COVID-19. Data were collected from the Shanghai Public Health Clinical Center and Wuhan Leishenshan Hospital. Skin rashes were present in 52 patients (1.66%). Among them,

obvious skin lesions were present in 17 patients (0.54%) before the other symptoms of COVID-19 and in 35 (1.12%) in the early stages of the COVID-19 infection (Fig 1, A and Supplemental Table I, available via Mendeley at <https://data.mendeley.com/datasets/scvph5w5jr/1>). The skin rashes were urticarial in 52 patients (52%), followed by papules (15%), erythema and papules (14%), scratch (10%), rhagades (6%), and chilblains (4%).

Among the 52 patients with skin rashes, 21 patients were treated with oral corticosteroid (prednisone, 10 mg thrice daily), and the average time for skin rash recovery was 4.2 ± 2.3 days. This was significantly shorter than 8.3 ± 5.1 days in patients who were not treated with corticosteroid (Supplemental Table II). Although the use of corticosteroids in treatment of patients with COVID-19 remains controversial,⁵ our data suggested that skin lesions are associated with COVID-19 and that corticosteroid therapy is effective.

To further investigate the association of SARS-CoV-2 and skin rashes present in patients with COVID-19, we performed single-cell RNA sequencing with keratinocytes from normal human skin. The data showed that angiotensin-converting enzyme 2, the viral host cellular receptor, was highly and specifically expressed in the granulosum of the skin, whereas transmembrane serine proteases were relatively scattered in all keratinocytes and melanocytes, and in duct, Schwann, and neurocyte cells. The coexpression of angiotensin-converting enzyme 2 and transmembrane serine proteases was particularly found in the granulosum (Fig 1, B). Nucleocapsid protein was expressed in cytoplasm of epidermis from patients with COVID-19 but was not detected in normal skin tissue (Fig 1, C). These data suggested that the skin is a potential host of SARS-CoV-2. Although this hypothesis needs further study, it is intriguing to conjecture that SARS-CoV-2 may directly infect the keratinocytes in the injured skin (Fig 2).

In summary we noted in 52 patients with COVID-19, that skin manifestation can be present before the onset of fever or can coexist with fever and that angiotensin-converting enzyme 2 and transmembrane serine proteases were coexpressed in stratum granulosum keratinocytes. These findings highlight the potential risk of SARS-CoV-2 transmission via wounded skin in those with skin manifestations of the disease. Hence, recognition of skin lesions associated with COVID-19 by dermatologists and other health care professionals is essential.

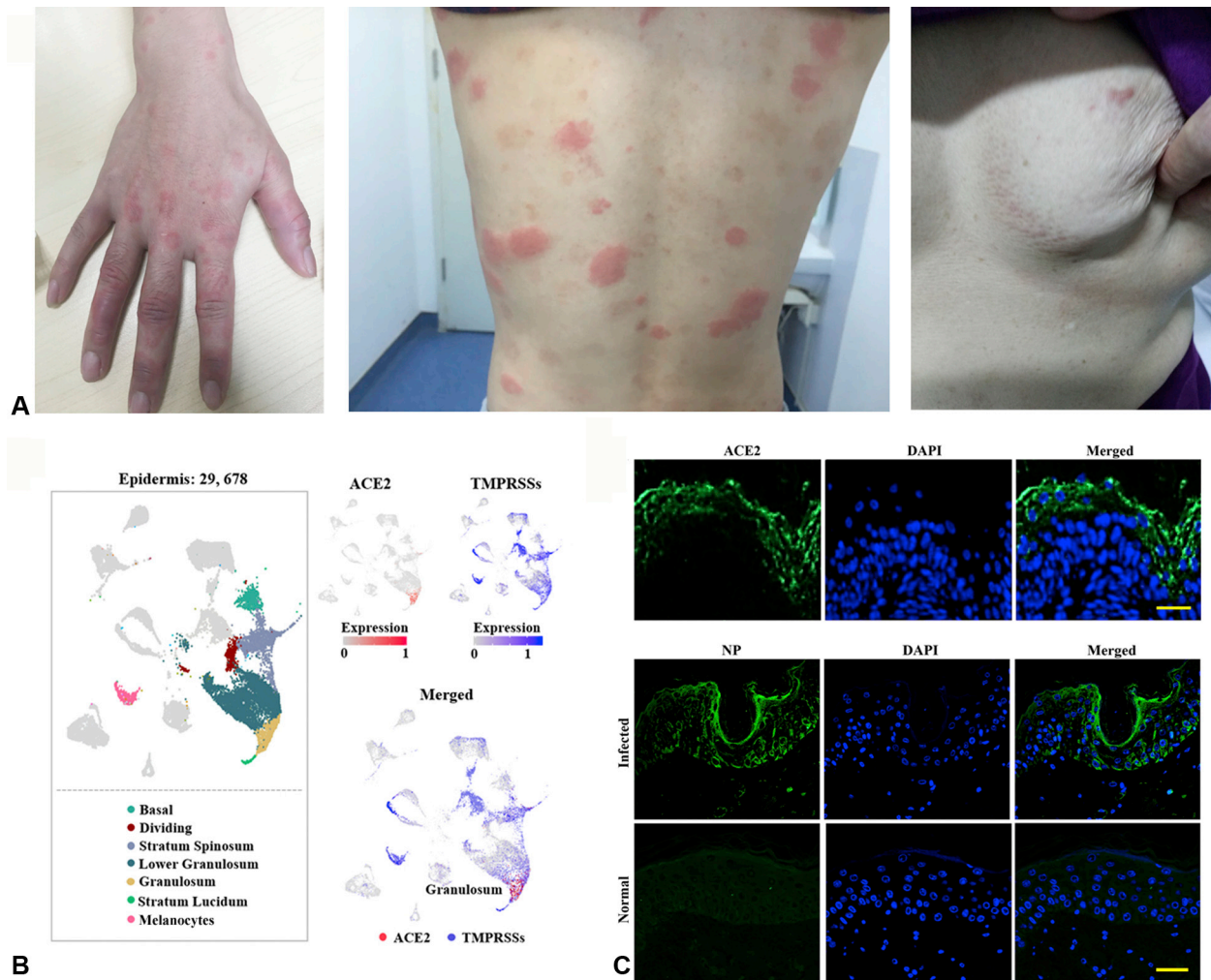


Fig 1. **A**, Presentation of skin rashes associated with patients with SARS-CoV-2. **Left**, Localized erythema and papule rash involving the hands. **Center**, Urticarial rash involving the back. **Right**, Papular rash on the breast. **B**, Uniform Manifold Approximation and Projection (UMAP) plot shows the expression levels of angiotensin-converting enzyme 2 (ACE2) and transmembrane serine proteases (TMPRSSs) family genes in skin cells. Coexpression was found in cells in the skin granulosum. **C**, ACE2 expression in human skin tissue and immunofluorescent staining of viral nucleocapsid protein (NP) in skin tissue from a healthy patient (**lower, normal**) and a patient with COVID-19 (**upper, infected**). Scale bar = 50 μ m. DAPI, 4', 6-diamidino-2-phenylindole.

Yangbai Sun, PhD,^a Renpeng Zhou, PhD,^b Hao Zhang, MD,^c Liu Rong, MD,^{d,e} Wang Zhou, PhD,^{f,g} Yimin Liang, PhD,^b and Qingfeng Li, MD^b

From the Department of Musculoskeletal Surgery, Fudan University Shanghai Cancer Center, Shanghai Medical College, Fudan University, Shanghai^a; the Department of Plastic and Reconstructive Surgery, Shanghai 9th People's Hospital, Shanghai Jiao Tong University School

of Medicine, Shanghai^b; the Department of Bone Tumor Surgery, Changzheng Hospital of Second Military Medical University, Shanghai^c; the Department of Critical Care Medicine, Shanghai General Hospital, Shanghai Jiao Tong University School of Medicine, Shanghai^d; the Department of Intensive Care Unit, Wuban Leishenshan Hospital, Wuban^e; Peking-Tsinghua Center for Life Sciences, Tsinghua University, Beijing^f; and Qiu-Jiang Bioinformatics Institute, Shanghai, China.^g

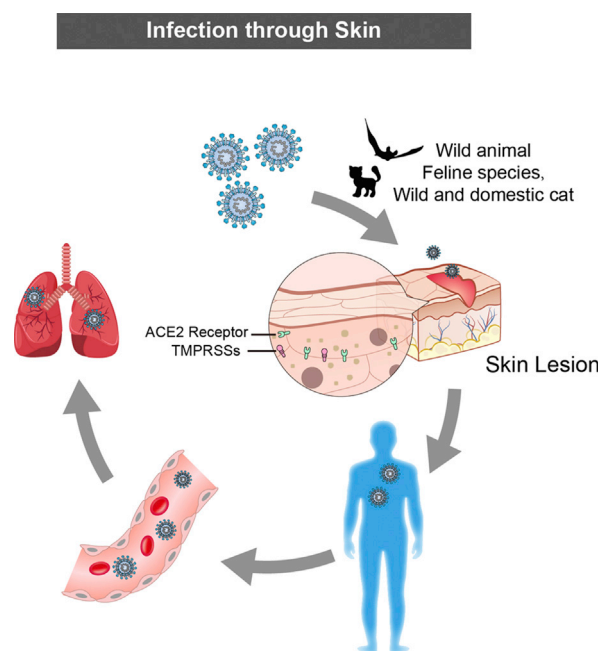


Fig 2. The potential risk of SARS-CoV-2 transmission via wounded skin causing COVID-19. ACE2, Angiotensin-converting enzyme 2; TMPRSS, transmembrane serine proteases.

Drs Sun, Zhou, and Zhang contributed equally to this work.

Funding sources: This work was supported by grants from National Natural Science Foundation of China (81701937) and Shanghai Sailing Program (20YF1422800).

Conflicts of interest: None disclosed.

IRB approval status: The work was performed in accordance with the ethical guidelines of the Institutional Review Board of the Fudan University Shanghai Cancer Center, Shanghai Medical College, Fudan University.

Reprints not available from the authors.

Correspondence to: Yangbai Sun, PhD; Wang Zhou, PhD; Yimin Liang, PhD; or Qingfeng Li, MD, Department of Plastic and Reconstructive Surgery, Shanghai Ninth People's Hospital, Shanghai JiaoTong University School of Medicine, 639 Zhi Zao Ju Road, Shanghai 200011, People's Republic of China.

E-mail: drsunnyb@fudan.edu.cn or brilliant212@163.com or acho_liang@hotmail.com or dr.liqingfeng@sbsmu.edu.com

REFERENCES

1. Xia J, Tong J, Liu M, Shen Y, Guo D. Evaluation of coronavirus in tears and conjunctival secretions of patients with SARS-CoV-2 infection. *J Med Virol*. 2020;92(6):589-594.
2. Kolivras A, Dehavay F, Delplace D, et al. Coronavirus (COVID-19) infection-induced chilblains: a case report with histopathologic findings. *JAAD Case Rep*. 2020;6(6):489-492.
3. Joob B, Wiwanitkit V. COVID-19 can present with a rash and be mistaken for dengue. *J Am Acad Dermatol*. 2020;82(5):e177.
4. Najarian DJ. Morbilliform exanthem associated with COVID-19. *JAAD Case Rep*. 2020;6(6):493-494.
5. Ye Z, Wang Y, Colunga-Lozano LE, et al. Efficacy and safety of corticosteroids in COVID-19 based on evidence for COVID-19, other coronavirus infections, influenza, community-acquired pneumonia and acute respiratory distress syndrome: a systematic review and meta-analysis. *CMAJ*. 2020;192(27):E756-E767.

<https://doi.org/10.1016/j.jaad.2020.08.057>

Ethnic skin centers in the United States: Where are we in 2020?



To the Editor: By 2044, people of color, representing Fitzpatrick's skin phototypes IV through VI, will make up more than half the US population.^{1,2} This demographic shift shows the need for dermatologists with skin of color expertise. Recognizing the unmet needs of patients with darker skin tones, Susan Taylor, MD, and others founded the Skin of Color Center at Mount Sinai St. Luke's in 1999. Over the past 20 years, 15 academic ethnic skin centers have been established in the United States to (1) further the care and research of conditions common among persons of color, (2) prepare residents to treat skin of color, and (3) educate the medical community and public (Table 1). We conducted a 13-item questionnaire sent to institutions with formal ethnic skin centers in the United States.

Ethnic skin centers average 2.3 faculty (range, 1-5) and 19 dermatology residents (range, 9-31). A previous study showed that 47.6% of residents receive no formal education regarding skin of color, demonstrating need for increased training during residency.³ In US metropolises where the majority of patients are of ethnic minorities, centers support resident training through diverse, high-volume clinics. Some centers offer disease-specific expertise: Henry Ford Ethnic Skin Care is globally recognized for vitiligo. To enhance skin of color education at institutions lacking exposure to patients with ethnic skin, faculty from ethnic skin centers accept visiting professorships.

Given the paucity of controlled studies on conditions prevalent in skin of color, research is paramount. More than one third (7/16) of ethnic skin