



# Standardizing serial photography for assessing and monitoring vitiligo: A core set of international recommendations for essential clinical and technical specifications

Nanja van Geel, MD, PhD,<sup>a</sup> Iltefat Hamzavi, MD,<sup>b</sup> Indermeet Kohli, PhD,<sup>b</sup> Albert Wolkerstorfer, MD, PhD,<sup>c</sup> Henry W. Lim, MD,<sup>b</sup> Jung Min Bae, MD, PhD,<sup>d</sup> Harvey Lui, MD, FRCPC,<sup>e,f</sup> John E. Harris, MD, PhD,<sup>g</sup> Amit G. Pandya, MD,<sup>h</sup> Steven Thng Tien Guan, MBBS, MRCP,<sup>i</sup> Marwa Abdallah, MD,<sup>j</sup> Samia Esmat, MD,<sup>k</sup> Julien Seneschal, MD, PhD,<sup>l</sup> Reinhart Speeckaert, MD, PhD,<sup>a</sup> Lynda Grine, MSc, PhD,<sup>a</sup> Hee Young Kang, MD, PhD,<sup>m</sup> Noufal Raboobee, MD,<sup>n</sup> Leihong Flora Xiang, MD, PhD,<sup>o</sup> Marcel Bekkenk, MD, PhD,<sup>c</sup> Mauro Picardo, MD,<sup>p</sup> and Alain Taieb, MD, PhD<sup>l</sup>  
*Ghent, Belgium; Detroit, Michigan; Amsterdam, The Netherlands; Seoul and Suwon, Korea; Vancouver, British Columbia, Canada; Worcester, Massachusetts; Dallas, Texas; Singapore; Cairo, Egypt; Bordeaux, France; Westville, South Africa; Shanghai, China; and Rome, Italy*

**Background:** Clinical photography is an important component of the initial assessment and follow-up of patients with vitiligo in clinical practice and research settings. Standardization of this photographic process is essential to achieve useful, high-quality, and comparable photographs over time.

From the Department of Dermatology, Ghent University Hospital, Ghent<sup>a</sup>; Department of Dermatology, Henry Ford Hospital, Detroit<sup>b</sup>; Department of dermatology, institute for pigment disorders and Infection & Immunity Institute Amsterdam UMC, Amsterdam<sup>c</sup>; Department of Dermatology, St. Vincent's Hospital, College of Medicine, The Catholic University of Korea, Seoul<sup>d</sup>; Department of Dermatology and Skin Science, University of British Columbia, Vancouver<sup>e</sup>; Photomedicine Institute, Vancouver Coastal Health Research Institute<sup>f</sup>; Department of Dermatology, The University of Massachusetts Medical School, Worcester<sup>g</sup>; Department of Dermatology, The University of Texas Southwestern Medical Center, Dallas<sup>h</sup>; Skin Research Institute of Singapore, ASTAR<sup>i</sup>; Dermatology, Andrology, and Venereology Department, Ain Shams University, Cairo<sup>j</sup>; Department of Dermatology, Faculty Of Medicine Cairo University<sup>k</sup>; INSERM U 1035, University of Bordeaux<sup>l</sup>; Department of Dermatology, Bordeaux University Hospitals<sup>l</sup>; Department of Dermatology, Ajou University School of Medicine, Suwon<sup>m</sup>; Department of Dermatology, Westville Hospital<sup>n</sup>; Department of Dermatology, Huashan Hospital, Fudan University, Shanghai<sup>o</sup>; and San Gallicano Dermatologic Institute, Rome.<sup>p</sup>

**Funding sources:** The research activities of Dr van Geel are supported by the Scientific Research Foundation—Flanders (Fonds Wetenschappelijk Onderzoek [FWO] senior clinical investigator: 1831512N) and Leo Foundation grant (Leo Foundation project reference number LF16092). Supporting sources of organizing the meetings: Vitiligo International Patient Organizations Conference (VIPOC), European Society for Pigment Cell and Melanoma Research (ESPCR) and Associazione Ricerca e Informazione sulla Vitiligine (ARIV) for the Paris meeting, Global Vitiligo Foundation (GVF) for the Detroit meeting.

**Disclosure:** Dr van Geel is a consultant and/or investigator for Pfizer, Laboratoire G  n  vrier, and Incyte. Dr Hamzavi is an

investigator for Est  e Lauder, Ferndale, Unigen, Johnson and Johnson, Bayer, Allergan, and Incyte and is a consultant for Pfizer, Johnson and Johnson, and Bayer. Dr Kohli is an investigator for Ferndale, Est  e Lauder, Unigen, Johnson and Johnson, Allergan, and Bayer and is a consultant for Pfizer, Johnson and Johnson, and Bayer. Dr Lim is a coinvestigator for Incyte. Dr Lui is an investigator/consultant for Pfizer, Johnson & Johnson, Novartis, LEO Pharma, and Sanofi-Genzyme. Dr Harris is a consultant and/or investigator for Pfizer, Genzyme/Sanofi, Stiefel/GlaxoSmithKline, Aclaris Therapeutics, Celgene, Incyte, Dermira, Rheos Medicines, Sun Pharmaceuticals, Leo Pharma, Villaris Therapeutics Inc, AbbVie, Janssen, TeVido BioDevices, EMD Serono, 3rd Rock Ventures, The Expert Institute, and BiologicsMD; has equity in TeVido Biodevices, Rheos, and Villaris Therapeutics, and is the scientific founder of Villaris Therapeutics. Dr Pandya is a consultant for Pfizer, is an investigator for Pfizer and Incyte, and serves on the board of directors of Clarify. Dr Raboobee is an advisory board member of Novartis, Janssen, and AbbVie. Drs Wolkerstorfer, Bae, Thng, Abdallah, Esmat, Seneschal, Speeckaert, Grine, Kang, Xiang, Bekkenk, Picardo, and Taieb have no conflicts of interest to declare.

**IRB approval status:** Reported at the local ethics committee at Ghent University Hospital, Belgium.

Accepted for publication October 22, 2019.

**Reprint requests:** Nanja van Geel, MD, PhD, Department of Dermatology, Ghent University Hospital, Corneel Heymanslaan 10, 9000 Ghent, Belgium. E-mail: [Nanja.vangeel@ugent.be](mailto:Nanja.vangeel@ugent.be).

Published online October 31, 2019.

0190-9622/\$36.00

   2019 by the American Academy of Dermatology, Inc. Published by Elsevier Inc. All rights reserved.

<https://doi.org/10.1016/j.jaad.2019.10.055>

**Objective:** The aim is to develop an international consensus for a core set of recommendations for standardized vitiligo clinical photography.

**Methods:** Based on an international meeting of vitiligo experts, a standard operating procedure was developed for vitiligo photography in daily practice and research settings. This protocol was subsequently reviewed by 20 vitiligo experts until agreement was reached.

**Results:** The resulting protocol includes a set of 10 and 15 photographs for clinical practice and research purposes, respectively. The photographic series are based on anatomic units included in the Vitiligo Extent Score. Furthermore, graphic representations of standardized positioning and suggestions for guidelines to standardize the process (background color, lighting, position marking, scales, materials, instruments) for both color and ultraviolet photographs are described.

**Conclusions:** This consensus-based protocol for vitiligo photography will harmonize imaging for both clinical practice, translational research, and clinical trials. It can improve outcome assessment, foster multicenter collaboration, and promote better communication with patients regarding outcomes of treatment. (J Am Acad Dermatol 2020;83:1639-46.)

**Key words:** assessment; consensus; imaging; outcome; photography; research; standardized; vitiligo.

In general, vitiligo can be readily diagnosed based on clinical evaluation that is supported by an ultraviolet (UV)-emitting Wood's lamp. Although vitiligo is visually striking, patient and clinician recall of the disease condition can be highly subjective and biased. Moreover, because the response to therapy can be very slow and is often subtle in the initial phases, serial imaging during subsequent visits of the skin is an essential tool for establishing the baseline disease extent, documenting its course, and assessing the response to treatments. It can facilitate dialogue with patients around treatment motivation, concerns, adherence, and follow-up. Moreover, digital image files can be analyzed with software from which quantitative data can be derived. With the advent of relatively inexpensive high-resolution cameras, the widespread use of cameras in dermatology has expanded. Nevertheless, to optimally exploit photography for patient management and clinical research, there is an urgent need to promote and adopt standards for achieving consistent, comparable, and informative images, not only for any given patient over time, but also for groups of patients across different institutions and practice settings.<sup>1</sup>

Unfortunately, the quality of clinical photography can be quite variable due not only to limited technical

#### CAPSULE SUMMARY

- Clinical photography is an important component of the initial assessment and follow-up of vitiligo patients, but an international standardized protocol is lacking.
- Based on an international consensus, a core set of recommendations for standardized clinical vitiligo photography is described. This will harmonize imaging for both clinical practice and trials.

proficiency but also to a somewhat arbitrary approach to deciding which specific areas to document photographically. Nonstandardized photography can be responsible for low reproducibility of clinical severity measurement, leading to high variability and imprecision in the assessment of repigmentation. Other pitfalls include impaired interrater reliability due to variations in image composition (ie, magnification, angle, perspective) or exposure (ie, luminance, contrast, white balance, focus/depth of field), which in turn, will influence research outcomes.

Standardization will improve the quality, consistency, and reproducibility of photography and facilitate our collective ability to compare individual results over time and grouped outcomes across different patients and clinical settings. In addition, a standardized procedure will increase efficiency by minimizing the time required to collect photographs and will serve as a means for teaching clinic personnel who are responsible for image acquisition. It may also facilitate the process of digital measurements performed after processing with specialized software.<sup>2</sup> Finally, standardized photography in clinical practice should facilitate comparison with validated vitiligo scoring systems such as the Vitiligo Extent Score (VES) and the Vitiligo Area Scoring Index.<sup>3,4</sup>

*Abbreviations used:*

UV: ultraviolet  
VES: Vitiligo Extent Score

This report describes a core set of recommendations and specifications for optimizing the use of photography of vitiligo lesions.

## MEETING/WORKSHOP

An imaging workshop was conducted in Detroit during the 2nd Vitiligo International Symposium (November 9-10, 2018). During this workshop, a discussion was initiated after a summary presentation on standardized photography that was based on a preliminary meeting during the first Vitiligo Imaging Workshop, organized in Paris (April 5, 2018) before the Vitiligo International Patient Organizations Conference. The presentation reviewed those items considered to be most relevant for inclusion in the imaging protocol. Examples of each item were presented and discussed. All participants were considered to be global vitiligo experts (see list at the end of this article).

Seven items were discussed (Fig 1): (1) general preparation of the patient, (2) optimal background for vitiligo photography, (3) use of a reference scale, (4) patient positioning, (5) lighting, (6) camera settings, and (7) minimum set of photographs for key anatomic regions. After the meeting, a standard protocol was created, which was subsequently reviewed by 20 vitiligo experts until final consensus was achieved.

The following recommendations were formulated after discussion and circulation of a draft.

### 1. Preparation of the patient

Before starting the photo session, make sure the patient has given consent for the photographic procedure and that he/she understands the rationale behind it and the fact it will become part of their medical record. Caution should be taken for patient privacy protection and storage of the photographs. Documented informed consent is required for any instance in which the photographs will be used for specific purposes other than the direct dermatologic care of that specific patient (eg, research, publication, and/or education). Next, prepare the patient by removing all items that can interfere with the visibility of the lesions (Table I).

### 2. Background

The patient should stand in front of a background or wall of a uniform color with no other distractions.

Preferably, the background should be even, nonreflecting, and the same each time the patient is photographed. Black, dark blue, or green is recommended for visualizing the skin because skin has a pink-red hue from blood flow that is best contrasted with cool/dark colors. Black or dark blue backgrounds can be easily combined with UV photography. In small spaces, a wall or door may be painted in a non-reflecting single color and used as a background. Alternatively, a back-drop made of fabric is suitable if space is limited, preferably made of felt, velour or other non-reflective material black or blue in color. Brown backgrounds will aid digital automated segmentation of vitiligo affected areas, especially when using broad band xenon as a light source. In the blue channel isolated image, pixels corresponding to the subject's normally pigmented skin and the brown background will both appear dark (low intensity), while depigmented skin will have associated light/high intensity pixels making automated segmentation easier.

### 3. Use of a reference scale for size

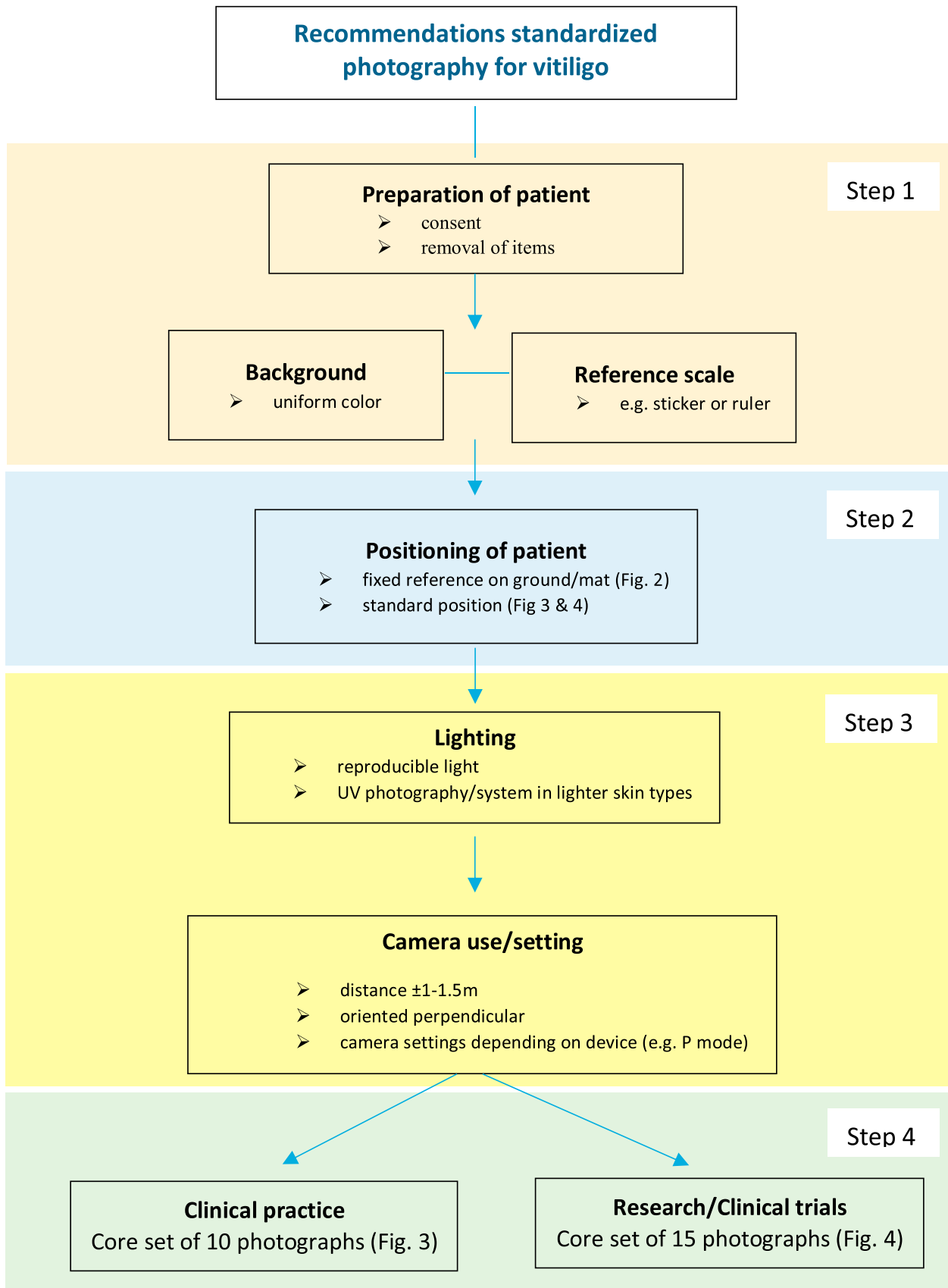
Use of a single item with known size consistently in all photos is recommended as a standard if surface measurement of lesions is required particularly for research settings. A standard reference card or other type of scale can be placed near the skin target; however preferably adjacent to a vitiligo lesion in each photographs or body area. Examples of scales include a ruler or a standard-sized adhesive sticker.<sup>5</sup> Dark blue or dark green stickers are most practical, as they can be combined with UV photography and can be used in patients with different skin photo types. The use of a commercial gray card or color chart with known sizes can be an alternative, which will also be useful for calibrating the images for white balance.

### 4. Positioning of the patient

To ensure a standard position, make use of tape or fixed lines (or drawing of feet) on the ground or a mat (Fig 2, A and B). A standardized patient position according to the VES images to enhance compatibility with the VES tool is proposed (Figs 3 and 4).<sup>1</sup> The standard anterior and posterior positions are similar. Practical additional instructions for photography per area are summarized in Table I. Some cases may require a lateral view, which can be added as an option to the standard set for better visualization of lesions on the sides of the body (Fig 2, C and D).

### 5. Lighting

Lighting is a very important factor in producing high-quality photos, and conditions should be highly



**Fig 1.** Flowchart for standardized photography in vitiligo. © 2019 VGICC and GVF.

**Table I.** Preparation and practical instructions for photography per area

Recommendations for preparation: removal of items that can interfere with the visibility of the lesions

Whenever possible or feasible:

1. Remove all clothes or use minimal coverage with underwear\*
2. Remove makeup, sunscreens, or day creams containing UV filters
3. Remove accessories (eg, jewelry,<sup>†</sup> glasses, watches)
4. Remove hair covering face, neck, or ears<sup>‡</sup>

Practical instructions for photography per area

1. Arms and hands: fully extended, stretched out toward floor. Palms facing forward. Space between body and hands of approximately 10 cm. Hands can be photographed either in standard anterior position (option 1) or with both hands next to each other (option 2) in front of a dark background.
2. Axilla: flat hands placed on top of head<sup>§</sup>
3. Feet: approximately 5 cm in between,  $\pm$  30 cm from background<sup>||</sup>
4. Face: eyes and mouth lightly closed and hair held back<sup>¶</sup>

\*Dark underwear is recommended, preferably black (white interferes with UV photography) and, if feasible, the same for serial photos. Alternatively, a black fabric may be used to cover colors that interfere with photography.

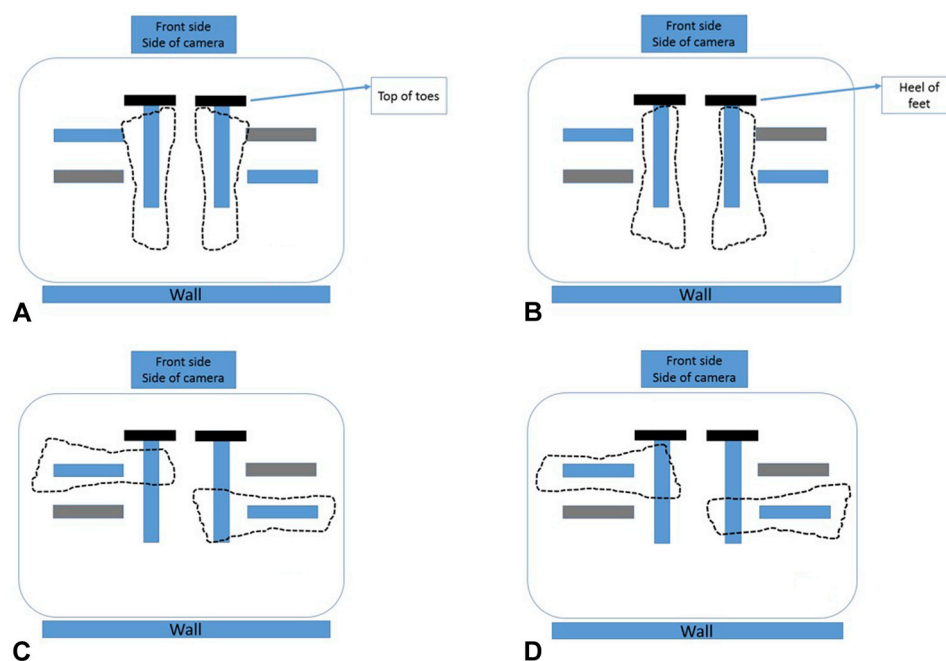
<sup>†</sup>A ring on a finger or earrings on ears may optionally be left on.

<sup>‡</sup>Move hair that covers the face, ears, or neck with a headband or hairband, or ask the patient to hold the hair back and off the face by using his/her hands during close-up photography of the face.

<sup>§</sup>Camera should be pointed toward the central concave surface of the axilla.

<sup>||</sup>More distance from the background can be helpful to focus in the right field, but space limitations in the clinic will often restrict this possibility.

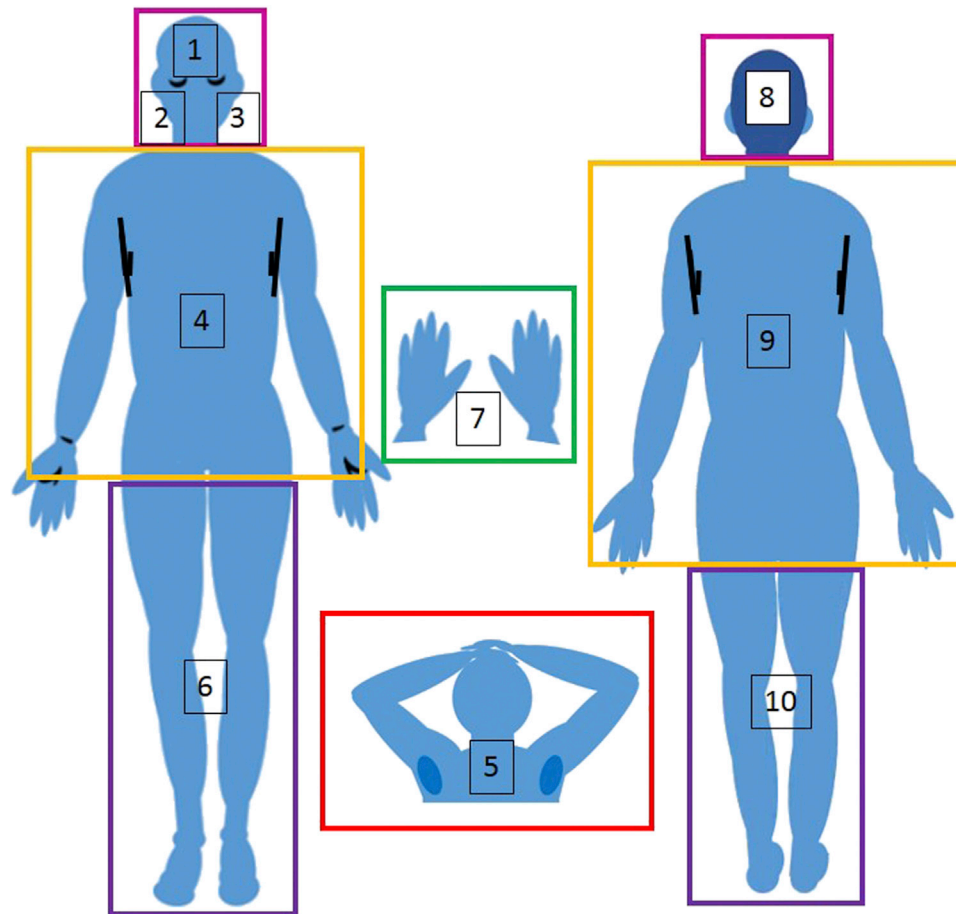
<sup>¶</sup>Ask the patient to look straight ahead or for lateral views at a 45° angle and close the eyes (colored dots on wall opposite to patients can be used as a guidance for the lateral view). © 2019 VGICC and GVF.



**Fig 2.** Vitiligo photography: examples of a mat on the floor including the marked lines for the (A) anterior and (B) posterior site. C and D, Cross lines can be optionally used for the lateral side view. © 2019 VGICC and GVF.

reproducible for each session; however, this can be quite challenging. If possible, fixed-position lights on either side of the patient should be used, although this is often available only in a photographic studio.

If this is not available, it is recommended that the windows be darkened and artificial lights used to create a reproducible light setting. We propose the use of ambient light with a light-sensitive camera or,



**Fig 3.** Vitiligo photography. Example of basic minimum set of photographs for clinical practice. Areas to include: (1) face–frontal view; (2) and (3) face from 45° angle on each side; (4) anterior trunk and arms; (5) axillae with both hands resting on head; (6) anterior legs and feet; (7) hands; (8) posterior head; (9) posterior neck, trunk and arms; (10) posterior legs. © 2019 VGICC and GVF.

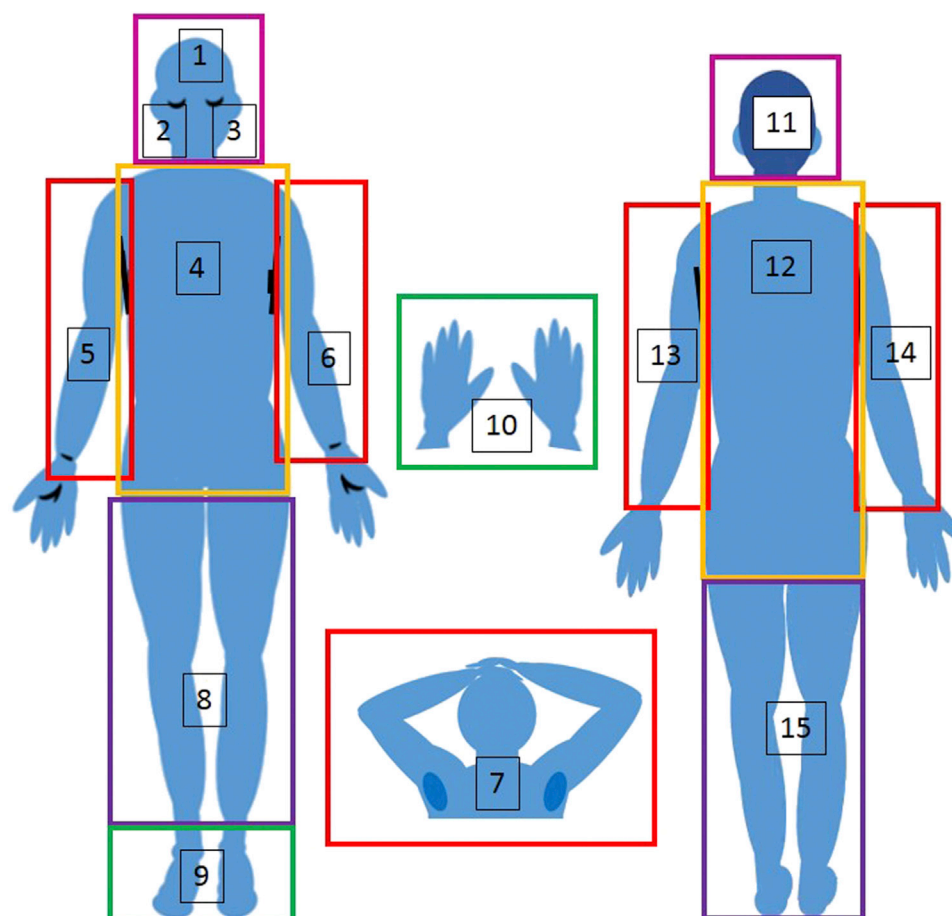
as a second option, the use of a built-in flash. The use of the camera's flash can reduce shadows in the photographs and can produce a more uniform lighting.

UV photography is recommended for patients with lighter skin types to enhance the contrast between lesional and nonlesional skin. Conventional Wood's light photography involves the use of a Wood's lamp combined with a digital camera (eg, digital single-lens reflex camera). If available, a better option is the use of a high-power UVA flash to overcome the low sensitivity of normal cameras to UVA light. Advanced UV photography involves a UVA flash and/or a special UV camera that is adapted for UV light registration while blocking visible light. However, research using advanced UV photography in dermatology is still in the early stage.<sup>6</sup> Therefore, for now, we recommend using the same optimal illumination adapted to a given UV system.

## 6. Use of camera and settings

Camera types may vary, although low light sensitivity is recommended (eg, digital single-lens reflex camera). Images are preferably captured in the camera's default raw file format (unprocessed) if available and feasible since their size are approximately 5 times bigger than JPEG files. Raw file formats retain the most image fidelity, dynamic range, and color information and are less subject to intentional or accidental corruption or manipulation. JPEG images can be batch-generated from raw files for output purposes. However, postprocessing may introduce artefacts, so generally, we recommend no corrections and preferably the raw format for this step. In the case of postprocessing manipulations, we propose that the default raw images be retained for audit or review and that the clinicians/authors specify the types of corrections or adjustments they made.





**Fig 4.** Vitiligo photography. Example basic minimum set of photographs for research/trials. Areas to include: (1) face frontal view; (2) and (3) face from 45° angle on each side; (4) anterior trunk; (5) and (6) anterior arms; (7) axillae with both hands resting on head; (8) anterior legs; (9) tops of feet; (10) hands; (11) posterior head; (12) posterior neck and trunk; (13) and (14) posterior arms; (15) posterior legs. © 2019 VGICC and GVF.

The optimal distance between patient and camera can be 1.0 to 1.5 m, depending on the focal length of the camera (eg, 18-55 mm). The camera should be oriented perpendicular to the patient's body or lesion of interest. Other angles may distort size and shape.

Take the picture in a comfortable position to stabilize the camera, and frame the area of interest in the center of the viewfinder. Check the photograph's quality immediately afterward on the display screen. Although it may be easier to use the fully automatic mode, better photographs may be achieved by using the programmed automatic mode (P mode). In P mode, the shutter speed (exposure time) and aperture are automatically adjusted, and other settings can be adapted, including the use of the flash, International Organization for Standardization setting (ISO) (eg, 100-200), white balance (daylight,

shade, cloudy, flash, tungsten, fluorescent), and exposure compensation, although adjustable sub-options may vary among brands. One can make the photograph brighter or darker by adjusting the exposure compensation value (dialing the +/- wheel).

For photography using UVA light or flash, manual setting (M mode) may be required. Specific settings depend on the device used and the intensity of the UV light or flash. UV flash requires adjustment of the ISO (eg, up to 3200), shutter speed (eg, 1/125), aperture setting (eg, F5.6), and white balance (eg, artificial light). Dimming the lights in the room allows one to reduce the power of the UV flash as much as possible. Specific UV glasses for all individuals is recommended for eye protection as well as compliance with other safety rules.

## 7. Core set of photographs

**Recommendations for clinical practice.** For clinical practice, the proposed minimal set is 10 areas (affected and unaffected areas), if possible, at each visit but in particular at baseline (Fig 3). However, if this is not feasible in clinical routine practice, photos can be limited to the affected areas only (eg, for focal, acrofacial, and segmental vitiligo). The plantar side and palms are not selected for the minimum set but can be added as an option.<sup>7</sup>

**Recommendations for research/clinical trials.** For research, a minimum set of 15 photographs corresponding to VES images (Fig 4) is recommended both at the start and end of trial. For time points in between, photographs may be limited to affected areas only. For UV photography, more photographs per area may be required, depending on the quality of UV illumination/camera.

## DISCUSSION

Following a standard operating procedure for photography will greatly improve documentation and allow comparison among different sites. These procedures may be integrated into future clinical trials to produce more efficient and reliable interpretation of results. Moreover, they may also provide deep phenotyping in combination with artificial intelligence to analyze big data and relevant information on the natural course, patterns, and prognosis of vitiligo.<sup>8</sup>

The recommendations summarized here are based on an international workshop with vitiligo experts from across the globe and represent an approach to standardize documentation across individual clinics and clinical trials.

To generate more evidence-based guidelines for vitiligo photography, prospective studies investigating different protocols are required to optimize parameters for utility and value in the diagnosis and management of vitiligo. Although the value of photographic documentation would appear to be self-evident, the scope of its use will also require validation against existing and future technologies, particularly in relation to its use for generating quantitative data.

The consensus recommendations and specifications from this study should be considered a first step in developing more robust and evidence-based approaches to optimize vitiligo photography.

We thank the Vitiligo International Patient Organizations Conference, European Society for Pigment Cell and Melanoma Research, and Associazione Ricerca e Informazione sulla Vitiligine for supporting the Paris meeting and the Global Vitiligo Foundation for supporting the Detroit meeting, and we thank the representatives of Fotofinder and Canfield for their presence at the Paris meeting.

Participants in the Paris and/or Detroit workshops: Marwa Abdallah (Egypt), Marcel Bekkenk (The Netherlands), Katia Boniface (France), Samia Esmat (Egypt), Iltefat Hamzavi (United States), John E. Harris (United States), Jung Min Bae (South Korea), Hee Young Kang (South Korea), Indermeet Kohli (United States), Henry W. Lim (United States), Harvey Lui (Canada), Amit G. Pandya (United States), Mauro Picardo (Italy), Noufal Raboobee (South Africa), Julien Seneschal (France), Alain Taieb (France), Steven Thng Tien Guan (Singapore), Nanja van Geel (Belgium), Albert Wolkerstorfer (The Netherlands), and Leihong Flora Xiang (China).

## REFERENCES

1. Tanghe E. The importance of good photography in clinical trials and in the clinic. *Br J Dermatol*. 2019;180(5):978.
2. van Geel N, Vandendriessche D, Vandersichel E, et al. Reference method for digital surface measurement of target lesions in vitiligo: a comparative analysis. *Br J Dermatol*. 2019;180(5):1198-1205.
3. van Geel N, Lommerts J, Bekkenk M, et al. Development and validation of the Vitiligo Extent Score (VES): an international collaborative initiative. *J Invest Dermatol*. 2016;136(5):978-984.
4. Hamzavi I, Jain H, McLean D, Shapiro J, Zeng H, Lui H. Parametric modeling of narrowband UV-B phototherapy for vitiligo using a novel quantitative tool: the Vitiligo Area Scoring Index. *Arch Dermatol*. 2004;140:677-683.
5. Dorn TV, Bertholdi L, Dellatorre G. Stamped adhesive ruler. *J Am Acad Dermatol*. 2019;81(4):e99.
6. Uitentuis SE, Bekkenk MW, van Geel N, de Rie MA, Wolkerstorfer A. UV light set-ups for vitiligo photography, a comparative study on image quality and ease of use. *J Eur Acad Dermatol Venereol*. 2019;33(10):1971-1975.
7. Iacovelli P, Filoni A, Martorina F, et al. Palmoplantar vitiligo: an overlooked entity. *J Eur Acad Dermatol Venereol*. 2019;33(8):e300-e303.
8. Fujisawa Y, Otomo Y, Ogata Y, et al. Deep-learning-based, computer-aided classifier developed with a small dataset of clinical images surpasses board-certified dermatologists in skin tumour diagnosis. *Br J Dermatol*. 2019;180(2):373-381.