

---

# High-precision freezing in cryotherapy by using customized and predesigned templates



Neha Taneja, MD,<sup>a</sup> Sanjeev Gupta, MD,<sup>b</sup> and Somesh Gupta, MD<sup>a</sup>  
*New Delhi and Mullana, India*

**Key words:** cryotherapy; precision; template.


## SURGICAL CHALLENGE

Cryotherapy in dermatology, though effective, is limited by its side effects,<sup>1</sup> a significant one being the lateral spread of cryogen on to the surrounding normal-appearing skin. To minimize runoff, neoprene and otoscope cones have been used, but these are expensive and available only in the shape of a circle with a limited range of sizes. The skin lesions requiring cryotherapy do not always conform to these fixed geometric dimensions and, therefore, lead to imprecise treatment areas.

## SOLUTION

We propose the use of thin, flexible polyurethane cryoshield templates, either prefenestrated in various shapes and sizes (prefenestrated template [PFT]) or cut-out identical to the dimensions of the lesion (disposable customizable template [DCT]) to prevent peripheral spread of the cryogen. PFTs are reusable (can be wiped with antiseptic solution and reused), and DCTs are disposed after use.

With PFTs, we created holes of different sizes and geometric shapes on the template that could fit regular and uniform lesions, such as verruca and seborrheic keratosis (Fig 1). With DCTs, we outlined an irregular lesion, such as a keloid, on a transparent film with a marking pen. This film is put over the template, and the marked area is cut with a no. 20 surgical blade. The template is then placed on the lesion, which protrudes from the



**Fig 1.** Reusable prefenestrated templates with holes of various shapes and sizes.

---

From the Department of Dermatology, Venereology, and Leprology, All India Institute of Medical Sciences, New Delhi<sup>a</sup>; and Department of Dermatology and Venereology, Maharishi Markandeshwar Institute of Medical Sciences and Research, Mullana.<sup>b</sup>

Funding sources: None.

Conflicts of interest: None disclosed.

---

Reprint requests: Somesh Gupta, MD, Department of Dermatology, Venereology, and Leprology, All India Institute of Medical Sciences, Ansari Nagar, New Delhi, India 110029.

E-mail: [someshgupta@hotmail.com](mailto:someshgupta@hotmail.com).

J Am Acad Dermatol 2020;83:e281-2.

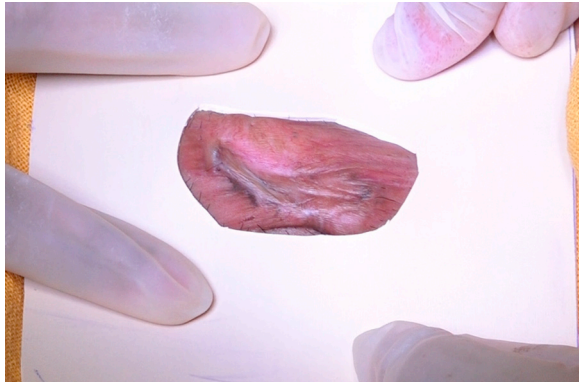0190-9622/\$36.00

© 2019 by the American Academy of Dermatology, Inc.

<https://doi.org/10.1016/j.jaad.2019.06.033>

aperture (Fig 2). Then, liquid nitrogen is sprayed (Videos 1 and 2). The template protects the surrounding skin from freezing.

Polyurethane is an ideal thermoplastic substance that does not crack or stick to the skin that can be used as a cryoshield template. It is easily available in variable thicknesses (ranging from 3/16 to 1/4 inches) at hardware stores and online shopping sites (used in surgical room flooring). It is inexpensive, stretchable (can fit the lesion and contour of the body part), and bacteriostatic.



**Fig 2.** Disposable customizable template perfectly fitting the irregular-shaped keloid.

#### REFERENCE

1. Gupta S, Yadav S, Patra S, Gupta S. Fractionated cryotherapy. *J Am Acad Dermatol.* 2017;77:e69-e71.