

Reply to: “Characterization of acute acro-ischemic lesions in non-hospitalized patients: A case series of 132 patients during the COVID-19 outbreak”



To the Editor: We read with interest the article by Fernandez-Nieto et al.¹ Cutaneous manifestations of coronavirus disease 2019 (COVID-19) are rarely reported. In their letter, Fernandez-Nieto et al¹ described an increased number of acroischemic lesions in young patients from Spain. Most patients were asymptomatic or mildly symptomatic, and none of them developed COVID-19 pneumonia or any other complication.

It is intriguing that in Italy we are observing the same uncommon increase. Italy and Spain are the 2 European countries with the highest incidence of COVID-19.² In Italy, after the outbreak onset, many general pediatricians reported on our pediatric dermatology network unusual foot injuries similar to chilblains and without any other symptoms. These lesions have never been described with this

frequency before, being usually rare. Thus, we circulated a specific online form among members of the Italian Federation of General Pediatricians to verify the possible association between chilblainlike lesions and COVID-19. Fernandez-Nieto et al¹ applied a different approach by analyzing dermatology consultations for cutaneous lesions. We reached the same results and conclusions for 100 children (Table I). The Spanish authors found 132 cases in 41 days, whereas ours were collected in 10 days. Even in our cohort, lesions were mostly located in the extremities of the limbs, with only 2 cases involving the face. We found a lower rate of systemic symptoms (16% vs 25%), but our population was slightly younger (mean age 12.5 vs 23.4 years), being likely less symptomatic.³ Almost the same number of positive SARS-CoV-2 test results (1 vs 2 patients) was described in both cohorts. Our patient with a positive result also had extracutaneous symptoms (fever and pharyngodynia). He was exposed to subjects with COVID-19 (family members), as were the COVID-19–infected Spanish patients. This confirms that the chance of finding

Table I. Characteristic of Spanish and Italian cohorts

Characteristics	Spain, n = 132	Italy, n = 100
Age, mean (range)	19.9 (1-56 y)	12.9 (3 mo-17 y)
Male sex (%)	71 (53.8)	64 (64)
Cutaneous symptoms (pain, itching, burning, swelling, erythema) (%)	NA	61 (61)
COVID-19 symptoms (%)	18 (13.6)	16 (16)
COVID-19–positive cases (%)	2 (1.5)	1 (1)
Location of skin lesions (%)	Hands: 41 (31) Feet: 108 (81.8)	Hands: 25 (25) Feet: 75 (75)
Duration of skin lesions, mean (range), d	8.7 (2-24)	Improvement at day 12 = 76%
Therapy (%)		74 (74)
Topical steroids		40
Topical antibiotics		8
Topical heparin		9
Topical antifungal		4
Systemic antibiotics	NA	2
Systemic steroids		4
Antihistamines		4
Paracetamol		6
Gentamicin + betamethasone		11
No therapy		26 (26)
Improvement by day 4 (%)		
Therapy		31 (41.9)
No therapy		13 (49.9)
Improvement by day 8 (%)		
Therapy		43 (58.1)
No therapy		19 (73.1)
Improvement by day 12 (%)		
Therapy		55 (74.3)
No therapy		21 (80.7)

COVID-19, Coronavirus disease 2019; NA, not applicable.

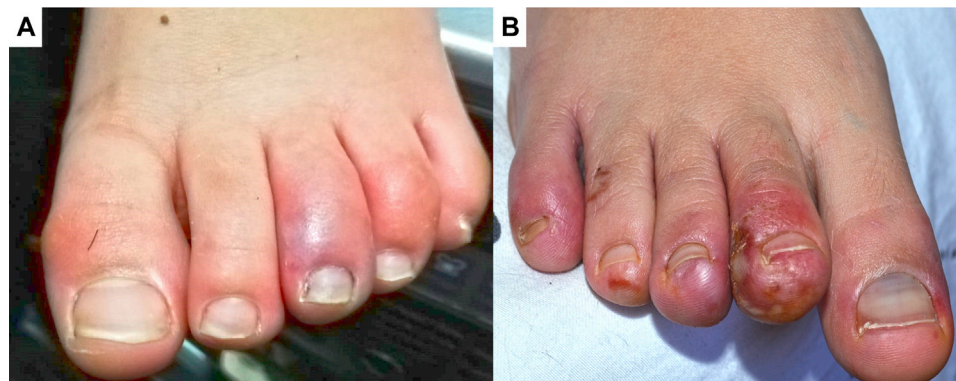


Fig 1. Photographs from 2 enrolled patients. **A**, Left foot lesions at day 0 in a 13-year-old patient with swelling, erythema, and itching. **B**, Right foot lesions at day 12 in a 13-year-old patient with pain, burning, swelling, erythema, and itching.

infected children increases if all cohabiting family members are tested after an index case. Indeed, only 11% of patients in our cohort were tested for severe acute respiratory syndrome Coronavirus 2 (Sars-CoV-2) because of the rigid testing policy in Italy. The Spanish group tested only 8%, thus confirming the difficulty in having testing in overwhelmed public health systems.

We did not differentiate between chilblainlike and erythema multiforme–like lesions. We observed and collected only lesions appearing as circumscribed erythematous edematous elements with a purplish-red color, which were thus defined as erythema perniolike lesions (Fig 1). A local or systemic therapy was considered in only 74 of 100 cases (74%) (Table I). Up to 80% of patients by day 12 had a favorable outcome regardless of the therapy used. This observation is additional evidence for a COVID-19 etiology. Indeed, it is known that chilblains can be secondary to viral infections. The likelihood of other seasonal non–COVID-19 infections was extremely low because children were having contact only with their family members because of the national lockdown.⁴

We definitively agree with Fernandez-Nieto et al¹ about the relationship between erythema perniolike acrolocated lesion onset and COVID-19. General pediatricians worldwide should pay attention to skin lesions during the COVID-19 pandemic.

We would like to thank the following persons for contributing to data collection: Biasci Paolo (Italian Federation of General Pediatricians President), Doria Mattia (National Secretary for Scientific and Ethical Activities of Italian Federation of General Pediatricians), Alfinito Mario, Amadori Annalisa, Annibali Amedeo, Battistini Alberto, Bellino Antonino, Berti Marina, Bonadies Lucia, Buffone Maria Raffaella, Buono Giovanni Carlo, Campagna Angela, Candio Francesco, Careddu Domenico, Cartiglia Maria Laura, Caruso Vincenzo, Caternolo

Maria, Ciampolini Massimo, Cocchiara Cristoforo, Contiguglia Nino, Cortesia Paolo, Costamagna Martina, Cristofanelli Palmira, De Bona Lidia, De Santis Rosamaria, Di Carlo Maria Teresa, Di Stasio Alessandra, Dolceamore Teresa Rita, Ferri Francesca Donatella, Foderi Stefania, Galioto Roberta, Galli Antonella, Gamboni Cosetta, Giacomini Annamaria, Grasso Silvana, Grasso Maria Carmela, Guaraldi Nicola, Gulino Antonino, Hensen Joanne, La Boria Maria Agata, Licordari Amalia, Longhini Federico, Lualdi Rosa, Mariani Danila, Mazzola Maria Pia, Mura Antonella, Napoli Mario, Paolini Paoletti Fabrizia, Piccione Concetta, Quinci Maria, Ravera Brunella, Romano Maria Rosaria, Sacchetti Roberto, Senesi Paolo, Simonelli Anna Rita, Sonaglia Franca, Squazzini Giuseppe, Stanzione Maria, Stramondo Prospero Sergio, Vallati Marina, Zinna Maria Concetta, Zucchi Graziano.

Giuseppe Ruggiero, MD,^a Fabio Arcangeli, MD,^b Torello Lotti, MD,^b Orsola Ametrano, MD,^c Cosimo Ruggiero, MD,^d Salvatore Cucchiara, MD, PhD,^d and Salvatore Oliva, MD, PhD^d

From the National Head of the Dermatology Study Group of the Italian Federation of General Pediatricians,^a University of Rome “Guglielmo Marconi,”^b Rome, Italy; Dermatology Unit, AORN Santobono-Pausilipon, Naples, Italy^c; and Pediatric Gastroenterology and Liver Unit, Maternal and Child Health Department, Sapienza University of Rome, Rome, Italy.^d

Funding sources: None.

Conflicts of interest: None disclosed.

Reprints not available from the authors.

Correspondence to: Salvatore Oliva, MD, PhD, Pediatric Gastroenterology and Liver Unit, Maternal and Child Health Department, Sapienza University of Rome, Viale Regina Elena 324-00161, Rome, Italy

E-mail: salvatore.oliva@uniroma1.it

REFERENCES

1. Fernandez-Nieto D, Jimenez-Cauhe J, Suarez-Valle A, et al. Characterization of acute acro-ischemic lesions in non-hospitalized patients: a case series of 132 patients during the COVID-19 outbreak. *J Am Acad Dermatol*. 2020;83(1):e61-e63.
2. World Health Organization. Coronavirus disease 2019 (COVID-19) situation report— 78. Available from: https://www.who.int/docs/default-source/coronaviruse/situation-reports/2020421-sitrep-92-covid-19.pdf?sfvrsn=38e6b06d_6. Accessed April 21, 2020.
3. Dong Y, Mo X, Hu Y, et al. Epidemiological characteristics of 2143 pediatric patients with 2019 coronavirus disease in China. *Pediatrics*. 2020;145:e20200702.
4. Lazzarini M, Barbi E, Apicella A, et al. Delayed access or provision of care in Italy resulting from fear of COVID-19. *Lancet Child Adolesc Health*. 2020;4:e10-e11.

<https://doi.org/10.1016/j.jaad.2020.05.122>