
Pernio-like skin lesions associated with COVID-19: A case series of 318 patients from 8 countries



Esther E. Freeman, MD, PhD,^{a,b} Devon E. McMahon, BA,^a Jules B. Lipoff, MD,^c Misha Rosenbach, MD,^c Carrie Kovarik, MD,^c Junko Takeshita, MD, PhD, MSCE,^c Lars E. French, MD,^d Bruce H. Thiers, MD,^e George J. Hruza, MD, MBA,^f and Lindy P. Fox, MD,^g for the American Academy of Dermatology Ad Hoc Task Force on COVID-19

Boston, Massachusetts; Philadelphia, Pennsylvania; Munich, Germany; Charleston, South Carolina; St Louis, Missouri; San Francisco, California

Background: Increasing evidence suggests pernio-like lesions are cutaneous manifestations of coronavirus infectious disease 2019 (COVID-19).

Objective: To describe clinical and pathologic findings of pernio-like lesions in patients with confirmed or suspected COVID-19.

Methods: An international dermatology registry was circulated to health care providers worldwide through the American Academy of Dermatology, International League of Dermatologic Societies, and other organizations.

Results: We documented 505 patients with dermatologic manifestations associated with COVID-19, including 318 (63%) with pernio-like lesions. Patients with pernio-like lesions were generally young and healthy, with relatively mild COVID-19. Of 318 patients with confirmed or suspected COVID-19 by providers, 23 (7%) were laboratory-confirmed COVID-19 positive, and 20 others (6%) were close contacts of patients with confirmed COVID-19. Given current testing criteria, many patients lacked COVID-19 testing access. For 55% of patients, pernio-like lesions were their only symptom. In patients with other COVID-19 symptoms, pernio-like lesions typically appeared after other symptoms. Pernio-like lesions lasted a median of 14 days (interquartile range, 10-21 days).

Limitations: A case series cannot estimate population-level incidence or prevalence. In addition, there may be confirmation bias in reporting. We cannot exclude an epiphenomenon.

Conclusions: Pernio-like skin changes of the feet and hands, without another explanation, may suggest COVID-19 infection and should prompt confirmatory testing. (J Am Acad Dermatol 2020;83:486-92.)

Key words: chilblains; COVID-19; dermatology; pernio; public health.

From the Department of Dermatology, Massachusetts General Hospital, Harvard Medical School, Boston^a; the Medical Practice Evaluation Center, Mongan Institute, Massachusetts General Hospital, Boston^b; the Department of Dermatology, University of Pennsylvania, Philadelphia^c; the Department of Dermatology, University Hospital, Munich University of Ludwig Maximilian^d; the Department of Dermatology and Dermatologic Surgery, Medical University of South Carolina, Charleston^e; the Department of Dermatology, St. Louis University^f; and the Department of Dermatology, University of California, San Francisco.^g

Funding sources: None.

Conflicts of interest: Drs Freeman, Lipoff, Rosenbach, Kovarik, Takeshita, Hruza, and Fox are part of the American Academy of Dermatology (AAD) Covid-19 Ad Hoc Task Force. Dr French is president of the International League of Dermatological Societies. Dr Hruza is immediate past president of the AAD.

Dr Thiers is the president of the AAD. Author McMahon has no conflicts of interest to disclose.

IRB approval status: The registry was reviewed by the Partners Healthcare (Massachusetts General Hospital) Institutional Review Board and was determined to not meet the definition of Human Subjects Research.

Accepted for publication May 22, 2020.

Reprints not available from the authors.

Correspondence to: Esther Freeman, MD, PhD, Massachusetts General Hospital, 55 Fruit St, Boston, MA 02114. E-mail: efreeman@mgh.harvard.edu.

Published online May 30, 2020.

0190-9622/\$36.00

© 2020 by the American Academy of Dermatology, Inc.

<https://doi.org/10.1016/j.jaad.2020.05.109>

Emerging evidence suggests that coronavirus infectious disease 2019 (COVID-19) has associated dermatologic manifestations. Many cutaneous findings of COVID-19 are nonspecific, such as morbilliform exanthems, urticarial eruptions, and vesicular lesions, and are often seen in the context of other viral infections.¹⁻³ In contrast, recent reports from around the globe highlight a striking pernio-like phenomenon in association with COVID-19.^{1,4,5} Pernio, or chilblains, is a superficial inflammatory vascular response that occurs on acral skin, usually after cold exposure, typically in children and young to middle-aged women.⁶ In this large international registry-based case series, we evaluate clinical characteristics of patients with suspected or confirmed COVID-19 who presented with pernio-like lesions on acral surfaces. Our objectives were to assess location, timing, and duration of the pernio-like lesions, and to analyze patients' comorbidities, COVID-19 severity, and disease outcomes.

METHODS

We established a registry to collect cases of COVID-19 with dermatologic manifestations reported by medical professionals, with data collected from April 8, 2020, to May 2, 2020. The registry was widely promoted to members of the American Academy of Dermatology, major dermatology subspecialty groups, the International League of Dermatologic Societies, and dermatology and general medicine groups on social media. The website (www.aad.org/covidregistry) was hosted through a Massachusetts General Hospital REDCap (Research Electronic Data Capture, Vanderbilt University, Nashville, TN) database. The registry queried patient demographics, dermatologic symptoms, COVID-19 history and symptoms, and past medical history. For this subanalysis, we included patients with new-onset pernio-like skin changes in the setting of confirmed or suspected COVID-19 and excluded patients with prior history of pernio. The deidentified patient data was analyzed using Stata 16 software (StataCorp, College Station, TX). The registry was reviewed by Partners Healthcare Institutional Review Board and was determined to not meet the definition of Human Subjects Research.

RESULTS

The registry compiled 505 cases of dermatologic manifestations associated with COVID-19 over 25 days, reported by dermatologists (50%), other physicians (37%), and midlevel practitioners (8%). There were 318 patients (63%) identified with pernio-like changes in the setting of confirmed or suspected COVID-19 (Table D). Patients were generally young and healthy, with median age of 25 years (interquartile range, 17-38 years), including 93 children and adolescents. Only 25% had medical comorbidities.

Laboratory testing confirmed 23 patients (7%) were COVID-19 positive, including 13 by polymerase chain reaction (PCR) alone, 5 by antibody testing alone, 1 by combined PCR and antibody testing, and 4 by unknown assay. Of the 5 patients confirmed by antibody testing alone, 2 were immunoglobulin (Ig)M positive and IgG negative, with other patients' antibodies not specified. The 2 IgM-positive and IgG-negative antibody-confirmed patients both tested negative by PCR. PCR testing was not available for the other 3 antibody-positive patients. In addition, 20 patients had close contact with patients with confirmed COVID-19 (eg, child of health care worker who tested positive); though in 1 case, the patient subsequently tested PCR negative for COVID-19. Most cases (72%) were in patients with suspected COVID-19 without confirmatory testing at a time with limited testing access due to current testing criteria. These cases represent novel cases of new-onset pernio in patients without prior history, temporally associated with high levels of undetected community-based severe acute respiratory syndrome coronavirus 2 (SARS-CoV-2) circulation during the COVID-19 pandemic. Some patients who did receive testing had negative results: of 318 patients with pernio-like lesions, 46 were PCR negative and 14 were antibody negative.

Other COVID-19 symptoms were present in 45% of patients with pernio-like lesions. The most common were cough (21%), headache (15%), sore throat (12%), and fever (12%). When symptoms were present, the pernio-like lesions occurred before (13%), at the same time (15%), or after (54%) the COVID-19 symptoms. Patients generally had mild COVID-19 clinical courses, with 6 patients hospitalized, 2 of whom died. Of the 4 surviving hospitalized

CAPSULE SUMMARY

- This large international registry-based case series adds to the emerging evidence that pernio-like lesions may be a cutaneous manifestation of COVID-19.
- Patients with pernio-like lesions generally had benign clinical courses. Importantly, because some of these patients may be infectious, isolation and COVID-19 testing must be considered.

Abbreviations used:

COVID-19:	coronavirus infectious disease 2019
Ig:	immunoglobulin
PCR:	polymerase chain reaction
SARS-CoV-2:	severe acute respiratory syndrome coronavirus 2

patients, 2 had uncomplicated courses, 1 patient required supplemental oxygen, and 1 required invasive mechanical ventilation. For 42 patients with the full course of pernio observed by providers, the lesions lasted for a median of 14 days (interquartile range, 10-21 days).

Pernio-like lesions affected only the feet in 84% of patients, only the hands in 5.1%, and a combination of the hands and feet in 10% (Fig 1). Associated acrocyanosis was seen in 9.2% and acral desquamation in 4.4%. Notably, 29% of patients lived in geographic regions with average March 2020 temperatures above 10°C, temperatures at which idiopathic pernio is less likely.

Dermatopathology was available for 1 PCR-positive patient, demonstrating mild vacuolar interface dermatitis with dense superficial and deep lymphocytic inflammation, consistent with pernio vs connective tissue disease. No thrombi were noted. Six other pathology reports from patients without laboratory confirmation showed findings consistent with pernio-like changes: (1) 1 with mild spongiosis, vacuolar interface change, few apoptotic epidermal keratinocytes, and perivascular and perieccrine lymphoid infiltrate, (2) 3 reporting superficial and deep perivascular, perieccrine lymphocytic or lymphohistiocytic infiltrate, without evidence of vasculitis, (3) 1 reporting a subepidermal blister with small vessel lymphocytic vasculitis without microthrombi, and (4) 1 reporting lymphocytic vasculitis with rare microthrombi and overlying epidermal necrosis.

DISCUSSION

Our registry-based, international collaborative series of patients presents the largest and most comprehensive collection of cases reported of pernio-like lesions as a cutaneous manifestation of confirmed or suspected COVID-19. Based on these data, we propose that this finding should prompt evaluation for the active or convalescent phase of infection. Patients in this case series were generally young, with few comorbidities, and had benign clinical courses. The pernio-like lesions in most patients developed either concurrently with, or after, COVID-19 symptoms, although 174 patients with

confirmed or suspected COVID-19 presented only with pernio-like skin lesions. Given these findings, at a time when there continues to be significant undetected community-based SARS-CoV-2 transmission, we propose that pernio-like lesions should be considered in testing criteria for COVID-19, with larger population-based epidemiologic studies needed to confirm or refute this association.

Given evolving understanding of COVID-19, clear public health messaging regarding these pernio-like lesions is paramount. A key implication of COVID-19 cutaneous manifestations is the opportunity to recognize patients, especially asymptomatic ones, who are at risk for spreading infection. The fact that many of our patients were otherwise asymptomatic and had not been tested for COVID-19 likely reflects limited availability of COVID-19 PCR testing at the start of the United States outbreak and variable state-by-state and country-by-country testing regulations. In many locations, testing has been limited to sicker patients, selecting against testing of patients with mild disease, including those who may develop COVID-19-associated pernio-like skin lesions.

Also important is our ability to reassure the public regarding the relatively benign clinical course observed in most of our patients. Lesions in this series resolved in a median of 2 weeks. This duration is likely an underestimate, because the clinical courses of many patients are ongoing, and the data were only available for patients with completed disease courses.

Questions remain about patients who presented with pernio-like changes and presumed COVID-19 who were ultimately PCR negative. Explanations for these patients include (1) findings were not COVID-19-related, (2) false-negative test results, or (3) testing occurred after viral clearance, with pernio-like lesions representing a late clinical finding. Although multiple possibilities exist, reports from Europe of pernio-like lesions during the COVID-19 surge suggest a true association,^{1,4,5} with pernio-like findings most commonly appearing in younger patients and later in the disease course.¹

New developments in COVID-19 antibody testing may further clarify the timing of pernio-like lesions in the COVID-19 clinical course. Of the 20 patients known to have antibody testing (IgM, IgG, unspecified, or both), only 6 (30%) tested positive. Two of these patients were PCR negative but IgM positive. Early studies have suggested that for antibody response to SARS-CoV-2, IgM peaks at day 28 whereas IgG peaks at day 49 after the onset of illness.⁷ Although there is a possibility that IgM positivity represents a false positive, if reliable, it

Table I. Clinical characteristics of patients with confirmed and suspected COVID-19 who developed pernio-like lesions on acral skin

Characteristic*	COVID-19 laboratory positive (n = 23) [†]	Close contact with COVID-19 laboratory positive (n = 20)	COVID-19 clinical suspicion (n = 229)	COVID-19 PCR negative [‡] (n = 46)	Overall (n = 318)
Age, years	41 (23-57)	24 (17-37)	24 (17-37)	27 (16-36)	25 (17-38)
Female sex [§]	11 (48)	5 (25)	118 (52)	21 (46)	155 (49)
Race/ethnicity					
White	18 (86)	17 (94)	195 (91)	38 (83)	268 (89)
Asian	1 (4.8)	1 (5.6)	14 (6.5)	6 (13)	22 (7.3)
Black/African American	0 (0.0)	0 (0.0)	1 (0.5)	1 (2.2)	2 (0.7)
Hispanic/Latino	2 (9.5)	0 (0.0)	5 (2.3)	1 (2.2)	8 (2.7)
Country of residence					
United States	22 (96)	17 (85)	212 (93)	42 (91)	293 (92)
Canada	0 (0.0)	1 (5.0)	6 (2.6)	4 (8.7)	11 (3.5)
France	0 (0.0)	1 (5.0)	4 (1.8)	0 (0.0)	5 (1.6)
United Kingdom	1 (4.3)	1 (5.0)	2 (0.9)	0 (0.0)	4 (1.3)
Italy	0 (0.0)	0 (0.0)	1 (0.4)	0 (0.0)	1 (0.3)
Mexico	0 (0.0)	0 (0.0)	1 (0.4)	0 (0.0)	1 (0.3)
Netherlands	0 (0.0)	0 (0.0)	1 (0.4)	0 (0.0)	1 (0.3)
Iran	0 (0.0)	0 (0.0)	1 (0.4)	0 (0.0)	1 (0.3)
Average monthly temperature					
Above 10°C	4 (18)	1 (5.0)	66 (29)	20 (43)	91 (29)
Below 10°C	19 (82)	19 (95)	163 (71)	26 (57)	227 (71)
Body site affected					
Foot	20 (87)	19 (95)	216 (94)	43 (93)	298 (94)
Hand	7 (30)	2 (10)	31 (14)	8 (17)	48 (15)
Dermatologic symptoms					
Asymptomatic	4 (17)	2 (10)	24 (11)	6 (13)	36 (11)
Pain/burning	16 (70)	16 (80)	144 (63)	35 (76)	211 (66)
Pruritus	8 (35)	9 (45)	99 (43)	21 (46)	137 (43)
Cold intolerance	2 (8.7)	2 (10)	17 (7.4)	1 (2.2)	22 (6.9)
Timing of dermatologic changes					
Before COVID-19 symptoms	4 (17)	0 (0.0)	12 (5.4)	3 (6.5)	19 (6.1)
After COVID-19 symptoms	11 (48)	6 (30)	48 (22)	15 (33)	80 (26)
At the same time as COVID-19	3 (13)	1 (5.0)	14 (6.3)	4 (8.7)	22 (7.1)
No other COVID-19 symptoms	5 (22)	12 (60)	132 (59)	21 (46)	170 (55)
Unknown	0 (0.0)	1 (5.0)	17 (7.6)	3 (6.5)	21 (6.7)
COVID-19 exposure					
None (community acquired)	7 (30)	0 (0.0)	126 (55)	20 (43)	153 (48)
Close contact with patient with					
Confirmed COVID-19	3 (13)	20 (100)	0 (0.0)	1 (2.1)	24 (7.5)
Suspected COVID-19	8 (35)	4 (20)	26 (11)	6 (13)	44 (14)
Presence in a health care facility where COVID-19 infections have been managed	1 (4.3)	0 (0.0)	10 (4.4)	7 (15)	18 (5.7)
COVID-19 symptoms					
Asymptomatic	5 (22)	10 (50)	140 (61)	19 (41)	174 (55)
Cough	9 (39)	3 (15)	41 (18)	14 (30)	67 (21)
Headache	7 (30)	4 (20)	27 (12)	9 (20)	47 (15)
Sore throat	5 (22)	4 (20)	21 (9.2)	8 (17)	38 (12)
Fever	9 (39)	1 (5.0)	18 (7.9)	9 (20)	37 (12)
Malaise	4 (17)	1 (5.0)	20 (8.7)	6 (13)	31 (9.7)
Shortness of breath	6 (26)	1 (5.0)	16 (7.0)	6 (13)	29 (9.1)
COVID-19 level of care					
Outpatient care only	18 (78)	20 (100)	229 (100)	45 (98)	312 (98)
Hospitalized, alive	3 (13)	1 (2.2)	4 (1.3)
Hospitalized, died	2 (8.7)	2 (0.6)

Continued

Table I. Cont'd

Characteristic*	COVID-19 laboratory positive (n = 23) [†]	Close contact with COVID-19 laboratory positive (n = 20)	COVID-19 clinical suspicion (n = 229)	COVID-19 PCR negative [‡] (n = 46)	Overall (n = 318)
Comorbid medical conditions					
None	17 (74)	12 (60)	172 (75)	36 (78)	237 (75)
Obstructive lung disease	2 (8.7)	2 (10)	12 (5.2)	1 (2.2)	17 (5.3)
Hypertension	2 (8.7)	1 (5.0)	5 (2.2)	1 (2.2)	9 (2.8)
Rheumatologic disease	2 (8.7)	...	3 (1.3)	3 (6.5)	8 (2.5)
Inflammatory bowel disease	6 (2.6)	1 (2.2)	7 (2.2)

PCR, Polymerase chain reaction.

*Data are presented as number (%) or as median (interquartile range).

[†]Two patients were COVID-19 antibody positive but polymerase PCR negative.

[‡]One patient in this group had close contact with a COVID-19 laboratory positive patient.

[§]Defined as sex assigned at birth.

^{||}Calculated using state monthly averages in the United States and country monthly averages for the other countries listed.

instead supports the theory that antibody testing would be an important part of the evaluation of pernio-like lesions to rule out COVID-19. Further, if pernio is indeed a later disease course phenomenon in at least a subset of patients, then it may be prudent to repeat antibody testing and/or seek delayed IgG testing for suspected patients.

We must critically examine with further investigation why some patients with COVID-19-associated pernio-like lesions might test negative with current antibody testing. Immunocompromised patients may fail to generate antibodies, but most patients with COVID-19-associated pernio-like lesions are otherwise healthy young patients whose skin lesions developed late in their course with theoretically sufficient time to generate IgM or IgG antibodies, or both.

There are several possible explanations. Certainly, some patients may have new-onset pernio from other non-COVID-19 causes. That may be true for some of these patients, but given the large number of new reports of pernio coincidentally with the COVID-19 pandemic, it is unlikely to explain all cases. Some patients in the registry with negative antibodies had clinical histories predictive of high pretest probability; for example, a physician caring for COVID-19 patients in Milan and a child with a PCR-positive parent. One possibility is false-negative test results, because there is significant variability in the sensitivity and specificity of current tests on the market.^{8,9} It is also possible that many patients with COVID-19 may have a delayed antibody responses. Another, more worrisome, explanation is that the antibody response in patients with relatively mild disease tends not to be as brisk.^{7,10} This explanation is concerning, because it would both question the validity of our current antibody testing and suggest that patients with mild or

asymptomatic disease may not generate antibodies (and possible immunity) upon infection with SARS-Cov-2. Finally, reliable testing combined with coordination of timing of these skin changes with COVID-19 PCR, IgG, and IgM testing results is imperative to better establish self-isolation recommendations for patients presenting with pernio-like lesions.

There are multiple potential pathophysiologic mechanisms underpinning pernio-like lesions in COVID-19. In nonepidemic settings, pernio is often idiopathic or related to underlying disease (eg, systemic lupus erythematosus or antiphospholipid antibody syndrome), and cannot easily be ascertained with histopathology alone.¹¹ The histopathology reported for 1 of the COVID-19 PCR-positive patients, as well as 4 of 6 patients with suspected COVID-19, demonstrated features consistent with pernio without evidence of vascular damage, suggesting COVID-19-associated pernio-like lesions may be simply inflammatory. The other 2 of 6 patients with suspected COVID-19 with histopathology reported vascular changes, including lymphocytic vasculitis, which can sometimes be seen in conjunction with variants of pernio. Indeed, interferon response to viral infection appears to be a clue why some patients do poorly while others fare well.^{12,13}

Less likely, but worthy of consideration, is that prothrombotic coagulopathy may be a contributing factor, as suggested by COVID-19 cases complicated by venous thromboembolism, pathologic reports of microvascular thrombosis,¹⁴ and laboratory abnormalities including elevated D-dimer and high fibrinogen.¹⁵⁻¹⁷ Furthermore, antiphospholipid antibodies have been implicated in a small case series of patients acutely ill with COVID-19¹⁸ and have previously been associated with pernio. With greater

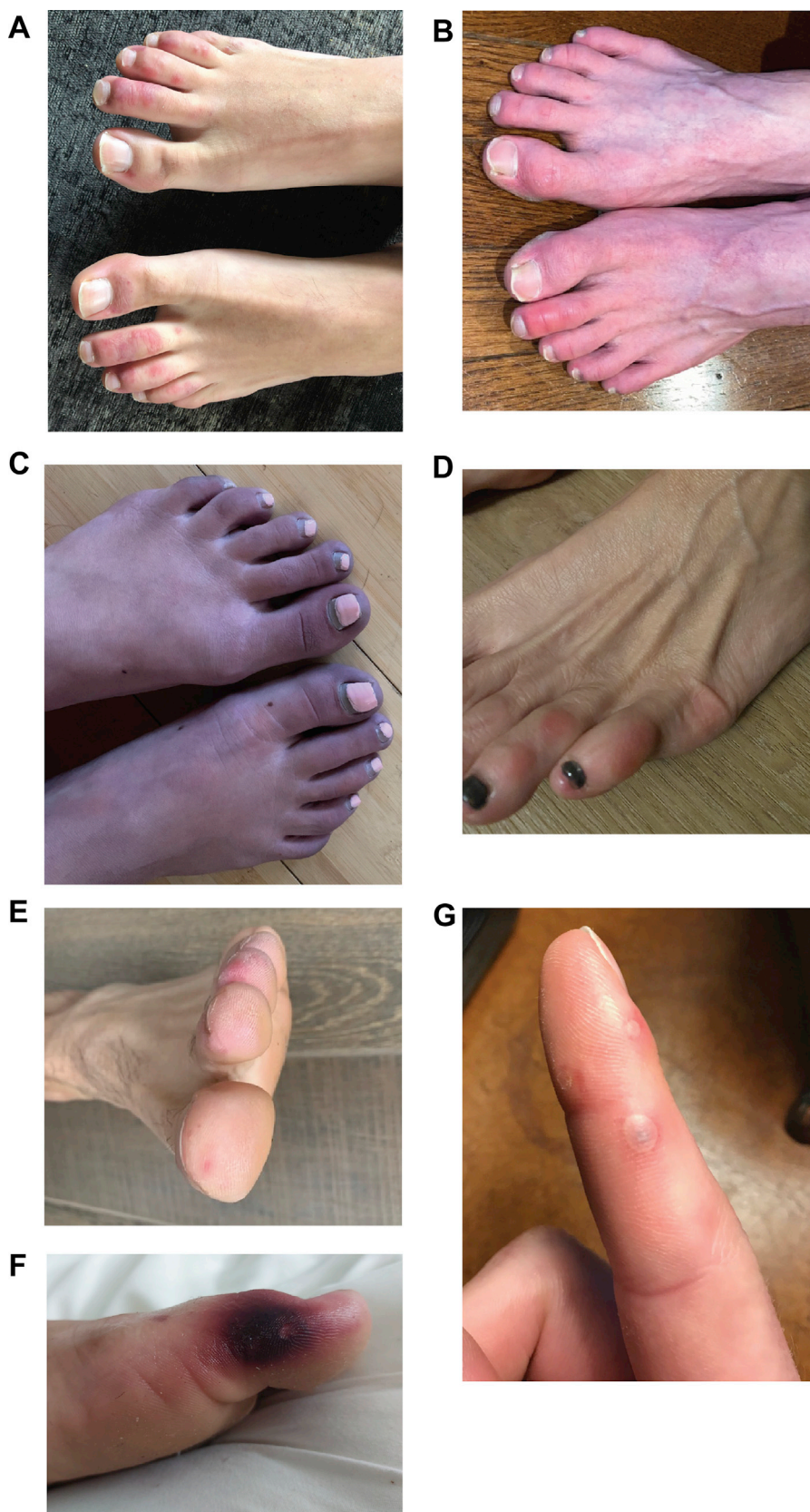


Fig 1. Pernio-like lesions on the (A-F) toes and (G) fingers in (A, C, D, E) COVID-19 polymerase chain reaction-positive patients, (E, F) antibody-positive patients, and (B, G) close contacts of COVID-19 polymerase chain reaction-positive patients.

clinical and pathologic correlation, we hope to better understand the pathophysiology, including understanding how, if at all, hypercoagulability plays a role in COVID-19-associated pernio-like lesions. Importantly, although young patients with COVID-19 have presented with stroke, we are not aware of any cases of concomitant pernio-like lesions and strokes.¹⁹

Limitations of this case series include incomplete testing for COVID-19, especially in otherwise asymptomatic patients. We are also unable to estimate the incidence or prevalence of this condition. There may be confirmation bias in reporting of cases. In addition, the background incidence of pernio from other causes in March and April is not well documented.⁶ We cannot exclude an epiphenomenon, because this case series cannot establish causation. Future studies are needed to assess the histopathology of pernio-like lesions to inform understanding of the disease process.

CONCLUSION

Our case series demonstrates pernio-like skin lesions as a manifestation of COVID-19. Patients with pernio-like lesions of COVID-19 may still be infectious and pose a public health risk, because skin lesions developed in at least 4 patients in this report before COVID-19 PCR confirmation, and the lesions developed in 14 while still PCR positive. We propose that pernio-like lesions be added to the testing criteria for COVID-19 and prompt consideration of testing for both PCR and IgM and IgG antibodies. This information will be critical to understanding the significance of these cutaneous lesions and empowering physicians and other health care providers to counsel patients appropriately.

We would like to thank Drs Philippe Dieude, Cynthia Yalowitz, Rachel Hub, Emily Arch, Ambrose Su, and Haydee Knott for providing photographs, Drs Rina Allawh, Graeme Lipper, Lynda Kauls, Lee Albert, Shannon Keiser, and Sarah Smilow for providing pathology, Dr Mariko Yasuda for her input on pathophysiologic mechanisms, and Dr Marlys Fassett for her contributions regarding antibody testing. We would like to thank the American Academy of Dermatology Ad Hoc Task Force on COVID-19 and staff at the American Academy of Dermatology for their logistical and administrative support. We would like to thank the International League of Dermatological Societies for their international collaboration. We also appreciate the COVID-19 Global Rheumatology Alliance for sharing their experience with registry development.

REFERENCES

- Galvan Casas C, Catala A, Carretero Hernandez G, et al. Classification of the cutaneous manifestations of COVID-19: a rapid prospective nationwide consensus study in Spain with 375 cases [e-pub ahead of print]. *Br J Dermatol*. <https://doi.org/10.1111/bjd.19163>; 2020. Accessed June 12, 2020.
- Recalcati S. Cutaneous manifestations in COVID-19: a first perspective. *J Eur Acad Dermatol Venereol*. 2020;34(5):e212-e213.
- Manalo IF, Smith MK, Cheeley J, Jacobs R. A dermatologic manifestation of COVID-19: transient livedo reticularis. *J Am Acad Dermatol*. 2020;83(2):700.
- Piccolo V, Neri I, Filippeschi C, et al. Chilblain-like lesions during COVID-19 epidemic: a preliminary study on 63 patients [e-pub ahead of print]. *J Eur Acad Dermatol Venereol*. <https://doi.org/10.1111/jdv.16526>; 2020. Accessed June 12, 2020.
- Fernandez-Nieto D, Jimenez-Cauhe J, Suarez-Valle A, et al. Characterization of acute acro-ischemic lesions in non-hospitalized patients: a case series of 132 patients during the COVID-19 outbreak. *J Am Acad Dermatol*. 2020;83(1):e61-e63.
- Cappel JA, Wetter DA. Clinical characteristics, etiologic associations, laboratory findings, treatment, and proposal of diagnostic criteria of pernio (chilblains) in a series of 104 patients at Mayo Clinic, 2000 to 2011. *Mayo Clin Proc*. 2014;89(2):207-215.
- Tan W, Lu Y, Zhang J, et al. Viral kinetics and antibody responses in patients with COVID-19 [preprint]. *medRxiv*. 2020. <https://doi.org/10.1101/2020.03.24.20042382>.
- Abbasi J. The promise and peril of antibody testing for COVID-19. *JAMA*. 2020;323(19):1881-1883.
- Whitman JD, Hiatt J, Mowery CT, et al. Test performance evaluation of SARS-CoV-2 serological assays [preprint]. *medRxiv*. 2020. <https://doi.org/10.1101/2020.04.25.20074856>.
- Wu F, Wang A, Liu M, et al. Neutralizing antibody responses to SARS-CoV-2 in a COVID-19 recovered patient cohort and their implications [preprint]. *medRxiv*. 2020. <https://doi.org/10.1101/2020.03.30.20047365>.
- Crowson AN, Magro CM. Idiopathic perniosis and its mimics: a clinical and histological study of 38 cases. *Hum Pathol*. 1997;28(4):478-484.
- Zhang Y, Qin L, Zhao Y, et al. Interferon-induced transmembrane protein-3 genetic variant rs12252-C is associated with disease severity in COVID-19 [e-pub ahead of print]. *J Infect Dis*. <https://doi.org/10.1093/infdis/jiaa224>; 2020. Accessed June 12, 2020.
- Fiehn C. Familial chilblain lupus-what can we learn from type I interferonopathies? *Curr Rheumatol Rep*. 2017;19(10):61.
- Magro C, Mulvey JJ, Berlin D, et al. Complement associated microvascular injury and thrombosis in the pathogenesis of severe COVID-19 infection: a report of five cases [e-pub ahead of print]. *Transl Res*. <https://doi.org/10.1016/j.trsl.2020.04.007>; 2020. Accessed May 3, 2020.
- Tang N, Li D, Wang X, Sun Z. Abnormal coagulation parameters are associated with poor prognosis in patients with novel coronavirus pneumonia. *J Thromb Haemost*. 2020;18(4):844-847.
- Yang X, Yu Y, Xu J, et al. Clinical course and outcomes of critically ill patients with SARS-CoV-2 pneumonia in Wuhan, China: a single-centered, retrospective, observational study. *Lancet Respir Med*. 2020;8(5):475-481.
- Wang D, Hu B, Hu C, et al. Clinical characteristics of 138 hospitalized patients with 2019 novel coronavirus-infected pneumonia in Wuhan, China. *JAMA*. 2020;323(11):1061-1069.
- Zhang Y, Xiao M, Zhang S, et al. Coagulopathy and anti-phospholipid antibodies in patients with Covid-19. *N Engl J Med*. 2020;382(17):e38.
- Oxley TJ, Mocco J, Majidi S, et al. Large-vessel stroke as a presenting feature of Covid-19 in the Young. *N Engl J Med*. 2020;382(20):e60.