

Reply to “COVID-19 can present with a rash and be mistaken for dengue”: Petechial rash in a patient with COVID-19 infection



To the Editor: We read with interest the article by Joob et al¹ hypothesizing that COVID-19 infection might present with a skin rash and petechiae. During the COVID-19 outbreak in China, clinical studies did obviously not focus on the skin manifestations of COVID-19. However, it is likely they exist and are probably under-recognized because of the current lack of dermatology consultations in these patients. Recently, Recalcati et al² reported the cutaneous manifestations of COVID-19 infection in Italy and described 3 main patterns: erythematous rash, urticaria, and chickenpox-like lesions. However, these 2 published articles did not include clinical images due to safety concerns with transmission of the virus or to a low suspicion of association with it.

These weeks we are living the same dramatic situation in Spain, especially in Madrid, and we are beginning to observe some skin manifestations in patients with COVID-19 infection (Fig 1).

Whether skin lesions in patients with COVID-19 infection are specific to COVID is still unclear. Viral

rashes and drug reactions are clinically and histologically similar and often hard to distinguish. The patient pictured above received hydroxychloroquine and lopinavir/ritonavir, but drug reactions are rare with these agents. In addition, it is not unlikely that COVID-19 may have cutaneous manifestations, because it occurs with other common viral infections. A thorough history of the patient must be obtained to assess the etiology, especially possible eliciting drugs, and time relationship to both drug intake and onset of the COVID-19 symptoms.

Dermatologists have a unique opportunity to study COVID-19 cutaneous manifestations during this pandemic, and illustrative images are the first step for other colleagues to start looking for them. A golden principle of medicine becomes now more important: “The more you see, the more you know; and the more you know is the more you see.”

Juan Jimenez-Caube, MD, Daniel Ortega-Quijano, MD, Marta Prieto-Barrios, MD, Oscar M. Moreno-Arrones, MD, PhD, and Diego Fernandez-Nieto, MD

From the Servicio de Dermatología, Hospital Universitario Ramon y Cajal, IRYCIS, Madrid, Spain.

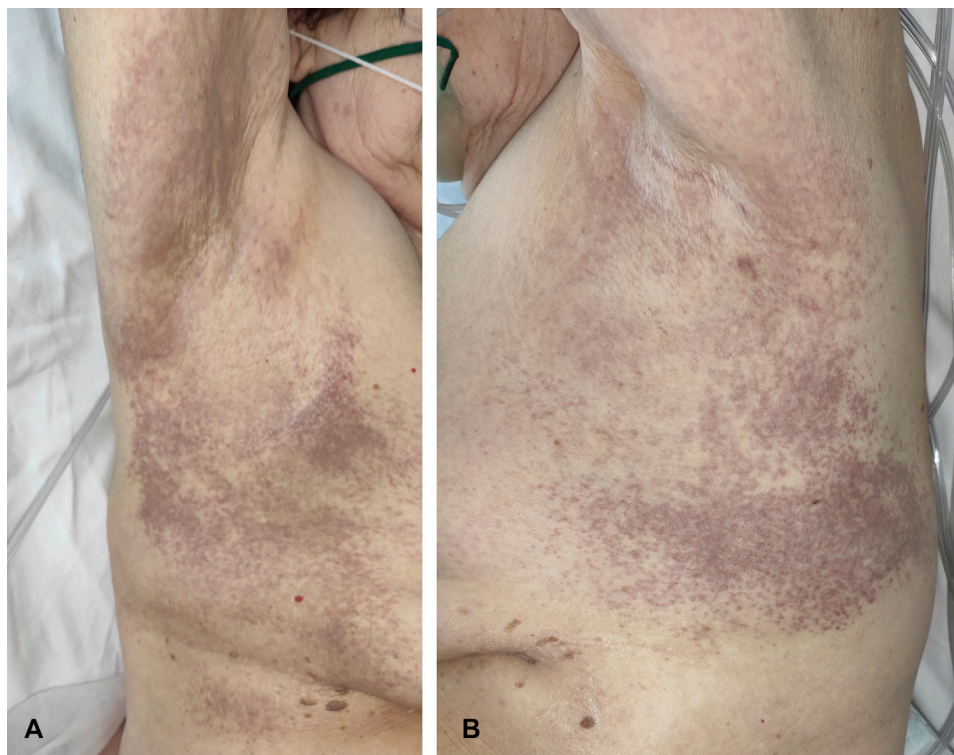


Fig 1. Purpuric skin rash in a patient with COVID-19 bilateral pneumonia, revealing purpuric, coalescing macules on (A) left and (B) right periaxillary regions.

Funding sources: None.

Conflicts of interest: None disclosed.

IRB approval status: Not applicable.

Reprints not available from the authors.

*Correspondence to: Juan Jimenez-Caube, MD,
Dermatology Department, Hospital Universitario
Ramón y Cajal, Carretera Colmenar Viejo km
9.100, 28034 Madrid, Spain*

E-mail: jjimenezc92@gmail.com

REFERENCES

1. Joob B, Wiwanitkit V. COVID-19 can present with a rash and be mistaken for dengue. *J Am Acad Dermatol.* 2020;82(5):e177.
2. Recalcati S. Cutaneous manifestations in COVID-19: a first perspective. *J Eur Acad Dermatol Venereol.* 2020;34(5): e212-e213.

<https://doi.org/10.1016/j.jaad.2020.04.016>