

# Ultrasound of the Normal Thyroid with Technical Pearls and Pitfalls



Danielle M. Richman, MD, MS\*, Mary C. Frates, MD

## KEYWORDS

- Thyroid • Thyroid anatomy • Normal anatomic variants of the thyroid • Ultrasound
- Technical pitfalls • Technical pearls

## KEY POINTS

- Ultrasound is the best screening and diagnostic test for evaluation of the thyroid gland.
- Thyroid ultrasound is best performed with the patient in a supine position with the neck hyperextended.
- The normal thyroid gland is homogeneous in appearance.
- There are a few anatomic variants to consider when imaging the thyroid gland as to not mistake normal anatomy for pathology.

## INTRODUCTION

The thyroid is a superficial structure in the anterior neck. Because of this superficial location, ultrasound is the imaging modality of choice for evaluation of the thyroid gland. It is safe, inexpensive, and an effective diagnostic test. Furthermore, the components of ultrasound of the thyroid gland are well established, including the appearance of the normal thyroid gland and thyroid pathology.

## IMAGING PROTOCOLS

The thyroid is imaged using a high-frequency linear transducer (7–15 MHz) with the patient lying supine with the neck in hyperextension. Placing a rolled towel beneath the upper shoulders can help extend the neck in larger patients or in patients with a low-lying gland. Ideally, the highest frequency available should be used to evaluate the thyroid gland; however, in certain clinical circumstances the frequency should be decreased

to optimize tissue penetration. Both lobes should be imaged in transverse and longitudinal planes, and the isthmus should be imaged in the transverse plane. Measurements should be obtained for each lobe including the anteroposterior, transverse, and sagittal dimensions. The anteroposterior dimension of the isthmus should be measured in the transverse plane. Color Doppler images are obtained to supplement gray scale images in the appropriate clinical setting (ie, suspected thyroiditis) and to help characterize a focal abnormality or nodule. Imaging should also extend superiorly in the midline to detect a pyramidal lobe or thyroglossal duct cyst.

A complete evaluation of the thyroid also includes imaging of the internal jugular lymph node chain bilaterally to assess for the presence of enlarged or abnormal-appearing lymph nodes.<sup>1</sup> The bilateral internal jugular chains are imaged in the transverse plane from the clavicle to the level of the hyoid (levels III, IV, and VI). Any enlarged benign-appearing lymph nodes or

Department of Radiology, Brigham and Women's Hospital, Harvard Medical School, 75 Francis Street, Boston, MA 02115, USA

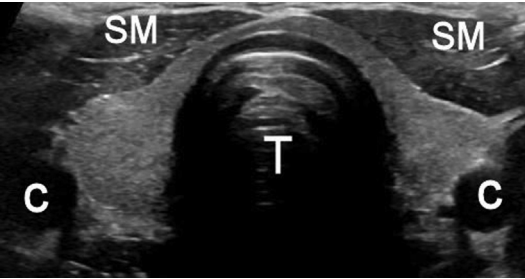
\* Corresponding author.

E-mail address: DMRichman@partners.org

Radiol Clin N Am 58 (2020) 1033–1039

<https://doi.org/10.1016/j.rcl.2020.06.006>

0033-8389/20/© 2020 Elsevier Inc. All rights reserved.



**Fig. 1.** Normal transverse thyroid on grayscale ultrasound. C = carotid artery; SM = strap muscles; T = trachea. Note the homogenous echotexture and symmetric morphology without enlargement.

abnormal-appearing lymph nodes of any size are measured in three planes (anteroposterior, transverse, sagittal). Because enlarged benign-appearing lymph nodes are commonly identified in levels IA and IB and are almost universally related to the mouth and not the thyroid, these levels are not included in the standard thyroid protocol.

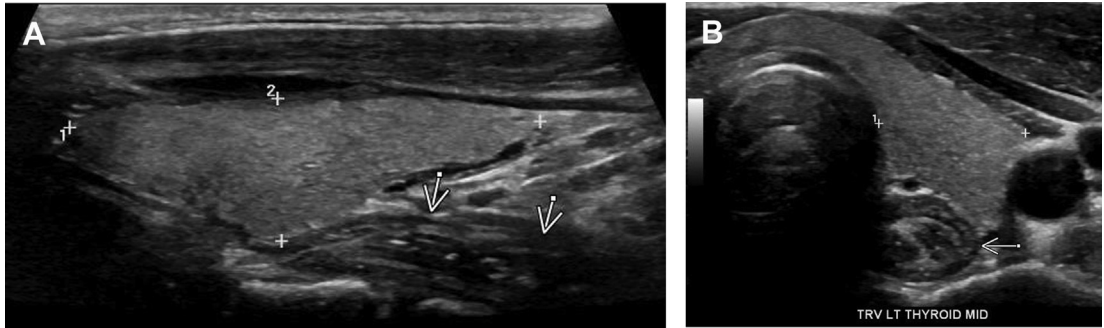
**IMAGING FINDINGS**

The thyroid is a bilobed structure in the neck that is located anterior to the trachea, with the lobes extending vertically along the right and left sides of the trachea (**Fig. 1**). The isthmus is the portion of the thyroid gland that connects the two lobes anteriorly. The trachea lies immediately posterior to the isthmus and is air-filled. Posterolateral to the thyroid lobe on each side is the carotid sheath, containing the common carotid artery medially and internal jugular vein laterally. Immediately anterior (superficial) to the thyroid are the strap muscles. The strap muscles include the sternohyoid and sternothyroid

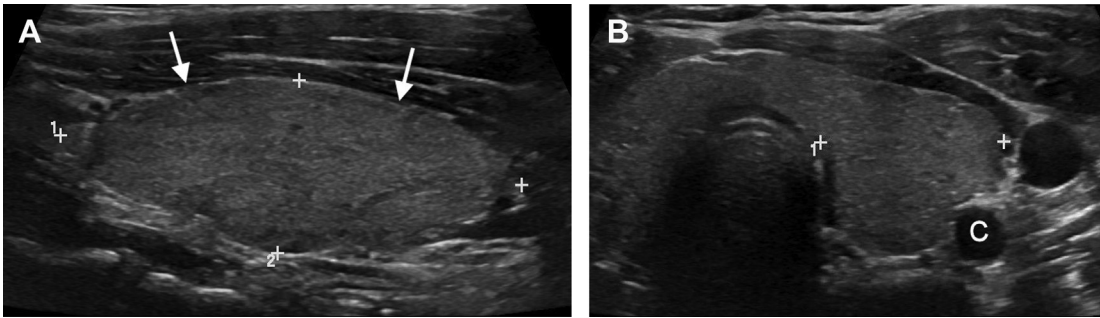
anterior to the thyroid, the sternocleidomastoid muscles anterolateral to the thyroid, and the longus colli muscles posteriorly. The esophagus is most commonly located posterior to the left lobe of the thyroid and can contain air (**Fig. 2**). When evaluating the thyroid in the context of pathology that the thyroid lacks a true capsule, it does typically have a well-defined peripheral margin.

Sonographically, the normal thyroid gland is homogeneously echogenic with increased echogenicity as compared with the adjacent strap muscles. There are no specific anatomic landmarks within the thyroid. The size of the normal thyroid gland is variable, but in adults, each lobe measures approximately 5 × 2 × 2 cm (sagittal × anteroposterior × transverse) with the isthmus measuring up to 0.3 cm in anteroposterior dimension.<sup>2-6</sup> A thyroid gland that is larger than these measurements is typically considered enlarged. An additional imaging finding that can further suggest that the thyroid is enlarged is bulging of the anterior surface of each lobe because this surface is typically symmetric and flat appearing (**Fig. 3A**). Extension of the gland over the anterior surface of the common carotid artery on a transverse image is evidence of gland enlargement (**Fig. 3B**). The normal thyroid gland can also extend over the surface of the carotid, but the anterior contour is typically flat. In children, gland shape and contour are used to indicate gland enlargement rather than size.

Sonographic evaluation of lymph nodes in the mid and low neck (levels III, IV, and VI) should be part of every thyroid ultrasound. Size and sonographic characteristics of the nodes should be assessed. Although size criteria are varied, at our institution a lymph node is considered enlarged if it measures greater than or equal to 7 mm in transverse diameter.<sup>2</sup> Size and location



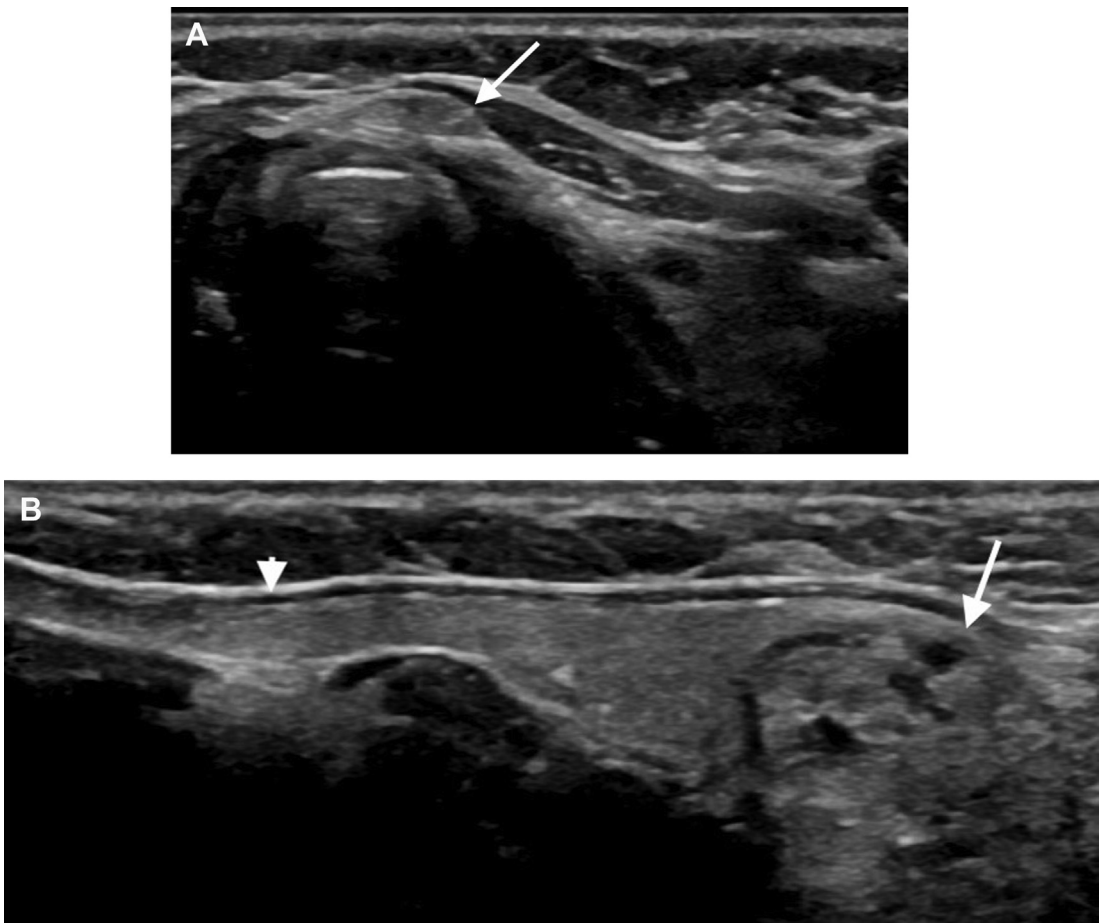
**Fig. 2.** (A) Sagittal left lobe of the thyroid on grayscale ultrasound (*calipers*). The esophagus is seen posteriorly (*arrows*). (B) Transverse image of the left lobe of the thyroid (*calipers*) with the esophagus located more posterior (*arrow*).



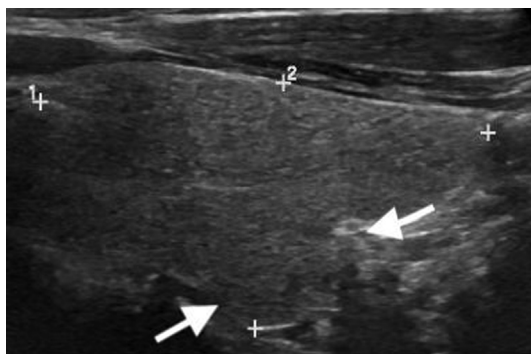
**Fig. 3.** (A) Sagittal grayscale ultrasound image of the thyroid (*calipers*) with bulging of the anterior portion (*arrows*), which suggests an enlarged gland. (B) Transverse grayscale ultrasound image of an enlarged left lobe of the thyroid (*calipers*) extending over the carotid artery (C).

of benign nodes meeting the criteria for enlargement are included in the report. Sonographic characteristics that are highly correlated with benign etiologies include an elongated shape,

tapered or pointed ends, and a thin echogenic hilum. Color Doppler is used to visualize a single vessel entering the node at the hilum and branching toward each end of the node.<sup>7</sup>



**Fig. 4.** (A) Transverse grayscale image of a pyramidal lobe (*arrow*) in a patient with surgical absence of the left lobe. (B) Sagittal grayscale image of the pyramidal lobe (*arrowhead*). The imaged portion of the right lobe contains a nodule (*arrow*).



**Fig. 5.** Sagittal grayscale image of the right lobe with normal thyroid tissue arising from the posterior margin of the gland (arrows), also known as the tubercle of Zuckerkandl. Note the similar echotexture as the rest of the gland.

### ANATOMIC VARIANTS

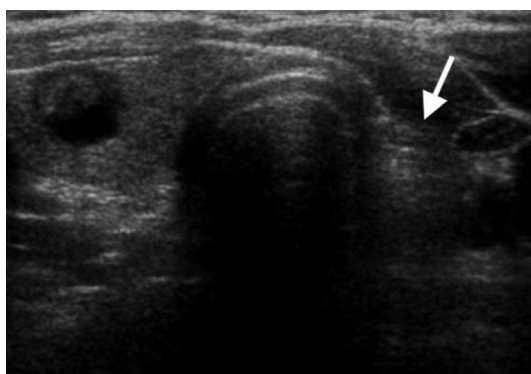
- **Pyramidal lobe:** Appears as normal thyroid tissue that arises from the isthmus and extends superiorly, anterior to the trachea. It may lay slightly to the right or left of true midline (**Fig. 4**). It is important to recognize and report this normal variant, because nodules can occur in this lobe, and it could potentially be overlooked by the surgeon during a thyroidectomy.
- **Zuckerkandl tubercle:** A protuberance of the normal thyroid tissue that arises from the posterior margin of the gland and extends posterior to the tracheoesophageal groove, most commonly on the right (**Fig. 5**). It is an important anatomic landmark for surgeons because of its relationship with the recurrent laryngeal nerve, which is typically located medial to the Zuckerkandl tubercle.<sup>8–10</sup> This normal

protuberance of tissue can mimic a thyroid nodule in the transverse plane (pseudonodule); however scanning in the sagittal plane confirms that the area is contiguous with normal thyroid tissue and is not a discrete nodule.

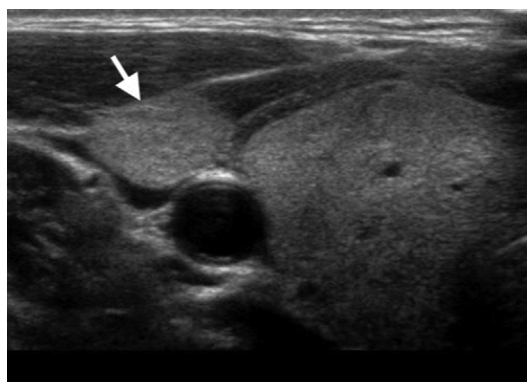
- **Thyroglossal duct remnant:** During normal embryonal development, the thyroid descends from the foramen cecum at the base of the tongue to its normal anatomic location in the low anterior neck. A remnant thyroglossal duct can remain along the path of descent, and residual thyroid tissue is seen in this area, manifested as a pyramidal lobe if connected to the gland, and as ectopic thyroid tissue if separate. If descent of the gland continues below the normal anatomic location, thyroid tissue is seen inferiorly within the mediastinum.
- **Partial or complete congenital absence of the thyroid:** Rarely, the thyroid gland is partially or completely absent at birth. In partial agenesis there may be agenesis of one lobe with resultant compensatory hypertrophy of the remaining lobe (**Fig. 6**).<sup>11</sup> There could also be sonographically normal thyroid tissue located ectopically, including laterally (**Fig. 7**), at the base of the tongue (lingual gland), in the superior mediastinum/thymus, or along the remnant thyroglossal duct (**Fig. 8**).<sup>12,13</sup> Newborn infants are routinely screened for the presence of thyroid hormone to exclude complete agenesis of the thyroid, because thyroid hormone is critical for normal development.

### IMAGING PITFALLS

- In some patients with a Zuckerkandl tubercle, if the intervening tissue is very thin, the appearance can mimic a nodule on transverse

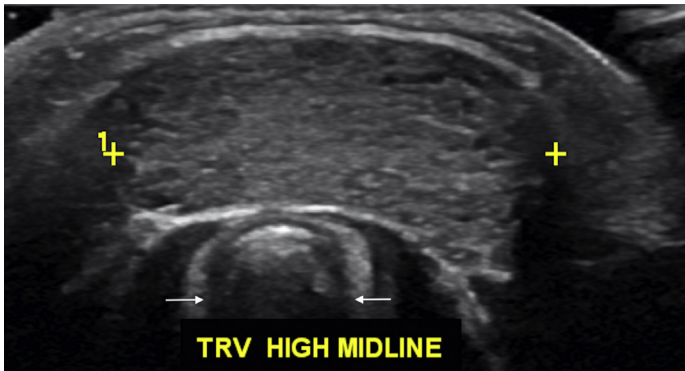


**Fig. 6.** Transverse grayscale image of the thyroid in a patient with congenital absence of the left lobe (arrow). The right lobe contains a partially cystic nodule.

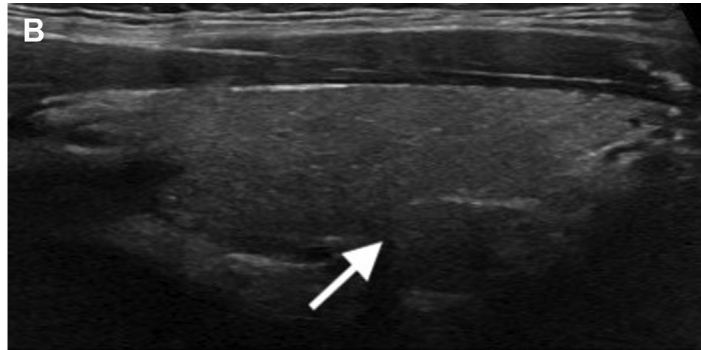
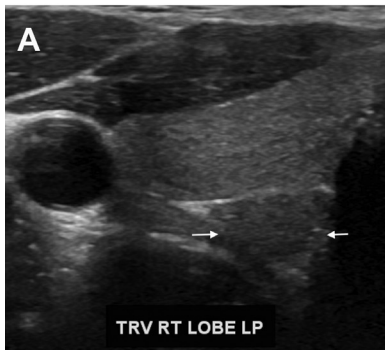


**Fig. 7.** Transverse grayscale image of the right lobe of the thyroid with ectopic thyroid tissue more lateral to the thyroid bed (arrow).

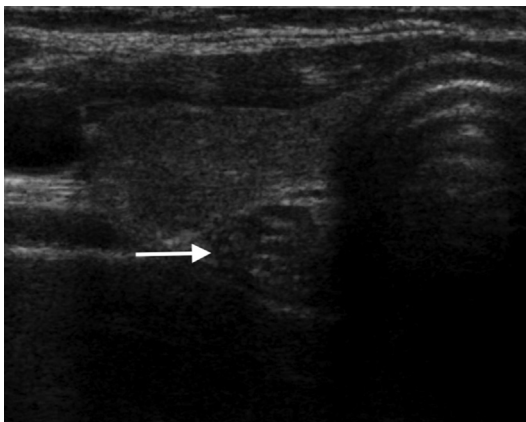




**Fig. 8.** Transverse grayscale image of the high midline neck with ectopic thyroid tissue (*calipers*) anterior to the trachea (*arrows*).

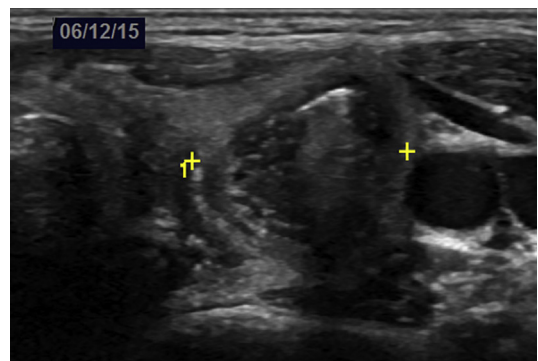


**Fig. 9.** (A) Transverse grayscale image of the right lobe with a thin echogenic interface and additional tissue noted posteriorly in the lower pole, mimicking the appearance of a posterior nodule (*arrows*). (B) Sagittal grayscale image of the right lobe demonstrates that this posterior lower pole thyroid tissue (*arrow*) is contiguous with adjacent thyroid tissue, consistent with a pseudonodule.

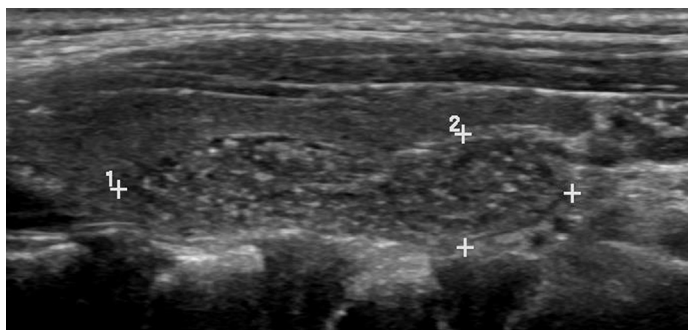


**Fig. 10.** Transverse grayscale image of the right lobe with the esophagus posterior to the thyroid (*arrow*). The esophagus may occasionally be seen to the right of the trachea.

imaging. However, on sagittal images this thyroid tissue is contiguous with the more superior thyroid tissue, and the finding is actually a pseudonodule (**Fig. 9**).



**Fig. 11.** Transverse grayscale image of the left lobe. Posterolateral to the left lobe is an esophageal duplication cyst containing gas within the lumen (*calipers*) that displaces the normal gland anteriorly.



**Fig. 12.** Sagittal grayscale image of the right lobe with thymus posterior to the thyroid gland (*calipers*).

- Occasionally, the esophagus can appear posteriorly to the right lobe and should not be mistaken for pathology (**Fig. 10**). Esophageal pathology on either side can mimic thyroid pathology (**Fig. 11**).
- In young children, the thymus is almost always visible immediately inferior to the lower poles of the thyroid in the superior mediastinum, and it should not be mistaken for pathology. The normal thymus appears heterogeneous and hypoechoic relative to normal thyroid tissue, with multiple prominent linear echogenic foci.<sup>14</sup> Normal thymic tissue can extend into the thyroid bed, typically posterior to the gland (**Fig. 12**).<sup>15</sup> Occasionally, thymic tissue is located within the gland and mimics a nodule.<sup>16</sup>

### TECHNICAL PEARLS

- Place a towel roll or pad behind the shoulders to improve neck hyperextension, particularly in larger patients or those with a short neck.
- In obese patients or patients with a thyroid that extends into the superior mediastinum, a lower frequency probe is used for increased penetration.
- Consider imaging the soft tissue superior to the thyroid isthmus to look for normal anatomic variants, such as a pyramidal lobe, or pathology, such as a thyroglossal duct cyst.

### SUMMARY

Ultrasound is the best imaging modality for a comprehensive evaluation of the thyroid. The thyroid is best imaged using a high-frequency linear probe with the patient in a supine position with the neck hyperextended. Normal thyroid is homogeneous in appearance without defining anatomic landmarks within the gland. A few anatomic variants can occur, and it is important for the sonographer and radiologist to be aware of these variants, to avoid misidentifying them as a pathology.

### DISCLOSURE

No disclosures.

### REFERENCES

1. AIUM-ACR-SPR-SRU Practice Parameter for the Performance and Interpretation of a Diagnostic Ultrasound Examination of the Extracranial Head and Neck. *J Ultrasound Med* 2018;37:E6–12.
2. Frates MC. Thyroid and parathyroid and other glands. In: McGahan JP, Goldberg BB, editors. *Diagnostic ultrasound: a logical approach*. New York: Informa Healthcare USA, Inc; 2008. p. 211–34.
3. Solbiati L, Livraghi T, Ballarati E, et al. Thyroid gland. In: Solbiati L, Rizzatto G, editors. *Ultrasound of superficial structures: high frequencies, Doppler and interventional procedures*. New York: Churchill Livingstone; 1995. p. 49–85.
4. Nachiappan AC, Metwalli ZA, Hailey BS, et al. The thyroid: review of imaging features and biopsy techniques with radiologic-pathologic correlation. *Radiographics* 2014;34(2):276–93.
5. Loevner LA. Imaging of the thyroid gland. *Semin Ultrasound CT MR* 1996;17(6):539–62.
6. Yalcin B, Tatar I, Ozan H. The Zuckerkandl tubercle and the recurrent laryngeal nerve. *Am J Surg* 2008; 196:311–2.
7. Prativadi R, Dahiya N, Kamaya A, et al. Ultrasound characteristics of benign vs malignant cervical lymph nodes. *Semin Ultrasound CT MR* 2017;38: 506–15.
8. Won HJ, Won HS, Kwak DS, et al. Zuckerkandl tubercle of the thyroid gland: correlations between findings of anatomic dissections and CT imaging. *AJNR Am J Neuroradiol* 2017;38(7):1416–20.
9. Lee TC, Selvarajan SK, Curtin H, et al. Zuckerkandl tubercle of the thyroid: a common imaging finding that may mimic pathology. *AJNR Am J Neuroradiol* 2012;33(6):1134–48.
10. Mirilas P, Skandalakis JE. Zuckerkandl's tubercle: Hannibal ad Portas. *J Am Coll Surg* 2003;196(5): 796–801.

11. Chang J, Gerscovich EO, Dublin AB, et al. Thyroid hemiagenesis: a rare finding. *J Ultrasound Med* 2011;30:1309–10.
12. Muir A, Daneman D, Daneman A, et al. Thyroid scanning, ultrasound and serum thyroglobulin in determining the origin of congenital hypothyroidism. *Am J Dis Child* 1988;142:214–8.
13. Ueda D, Mitamura R, Suzuki N, et al. Sonographic imaging of the thyroid gland in congenital hypothyroidism. *Pediatr Radiol* 1992;22:102–5.
14. Nasseri F, Eftekhari F. Clinical and radiologic review of the normal and abnormal thymus: pearls and pitfalls. *Radiographics* 2010;30(2):413–28.
15. Costa NS, Laor T, Donnelly LF. Superior cervical extension of the thymus: a normal finding that should not be mistaken for a mass. *Radiology* 2010;256:238–42.
16. Frates MC, Benson CB, Dorfman DM, et al. Ectopic intrathyroidal thymic tissue mimicking thyroid nodules in children: case series and review. *J Ultrasound Med* 2018;37:783–91.