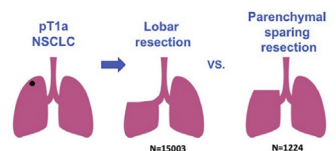


Thoracic Articles in AATS Journals

Readers who found these articles interesting may also like to read these thoracic papers that can be found in recent issues of AATS journals.

THORACIC

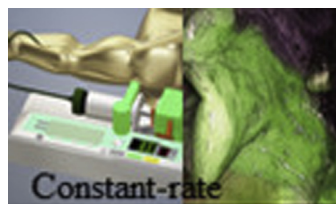
Lung Cancer



Equivalent 5-year overall survival, RR=1.08 (95% CI: 0.99-1.18)

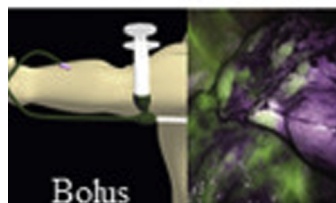
STCVS: Oncological outcomes of lobar resection, segmentectomy, and wedge resection for t1a non-small-cell lung carcinoma: A systematic review and meta-analysis. *Ijsseldijk MA, Shoni M, Siegert C, et al. Semin Thorac Cardiovasc Surg. 2020; in press.*

Commentary: Selecting appropriate patients for sublobar resection. *Sbrocchi AJ, Denlinger CE. Semin Thorac Cardiovasc Surg. 2020; in press.*



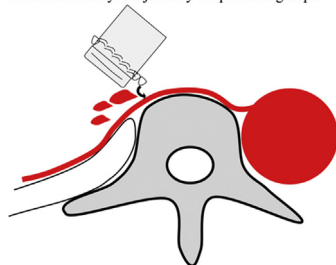
JTCVS TECHNIQUES: Constant-rate intravenous infusion of indocyanine green leading to high fluorescence intensity in infrared thoracoscopic segmentectomy. *Misaki N, Tatakawa K, Soo CS, Go T, Yokomise H. J Thorac Cardiovasc Surg Tech. 2020; in press.*

Commentary: Demarcating the intersegmental fissure... Please cut along the dotted line. *Sihag S. J Thorac Cardiovasc Surg Tech. 2020; in press.*



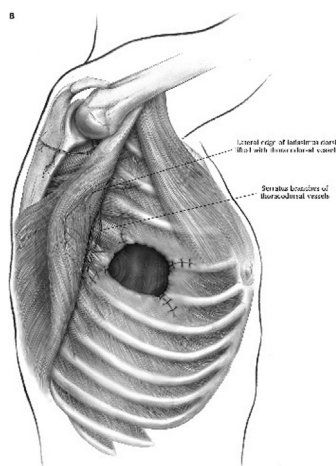
Commentary: Is it always greener on the other side? *Chan EG, Schuchert MJ. J Thorac Cardiovasc Surg Tech. 2020; in press.*

Intercostal artery is injured by the protruding staple



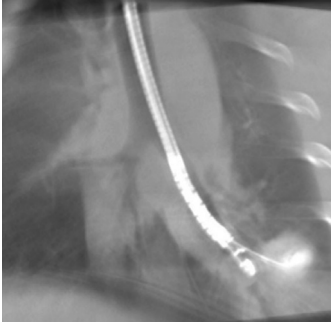
JTCVS TECHNIQUES CASE REPORT: A novel cause of late bleeding after lobectomy: Erosion of the bronchial staple-line in the chest wall. *Takamori S, Oizumi H, Suzuki J, Sadahiro.*

Commentary: Is there preventive measure for postoperative bleeding caused by the erosion of the bronchial staple-line in the chest wall? *Hu X, Chen C.*



OpTechs: A stepwise approach for postlobectomy bronchopleural fistula. *Gritsiuta AY, Eguchi T, Jones DR, Rocco G. Oper Tech Thorac Cardiovasc Surg. 2020;25(2):85-104.*

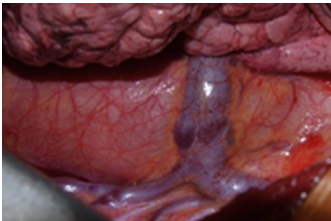
Lung Cancer: Basic Science



STCVS: Endobronchial ultrasound-guided radiofrequency ablation of lung tumors and mediastinal lymph nodes: A preclinical study in animal lung tumor and mediastinal adenopathy models. *Motooka Y, Fujino K, Gregor A, et al. Semin Thorac Cardiovasc Surg. 2020; in press.*

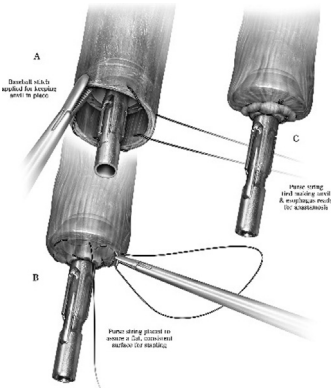
Commentary: Has the time finally arrived for radiofrequency ablation to enter the game? *Seder CW. Semin Thorac Cardiovasc Surg. 2020; in press.*

Esophageal Cancer



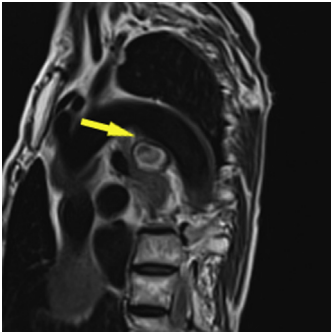
STCVS CASE REPORT: Not just your ordinary tumor: A solitary fibrous tumor of the esophagus. *Zamora AK, Chopra S, Sahakian A, Kim AW. Semin Thorac Cardiovasc Surg. 2020;32:176-178.*

Commentary: Solitary fibrous tumor of the esophagus—Rare but with typical characteristics. *Yeung J, de Perrot M. Semin Thorac Cardiovasc Surg. 2020;32:179-180.*



OpTechs: Esophagogastric anastomotic techniques for minimally invasive and robotic Ivor Lewis operations. *Caso R, Wee JO. Oper Tech Thorac Cardiovasc Surg. 2020;25(2):105-123. doi:10.1053/j.optechstcvs.2020.04.002.*

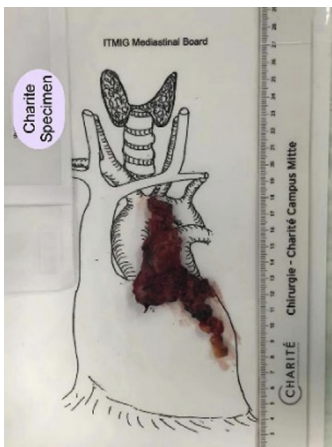Mediastinum



JTCVS TECHNIQUES CASE REPORT: Bronchial artery aneurysm mimicking aortic arch aneurysm or aortic dissection. *Ishida S, Koike W, Fujita T, Yagami K. J Thorac Cardiovasc Surg Tech. 2020; in press.*

Commentary: Magnetic resonance imaging for diagnosing vascular pathology. *Piechura LM, Sabe AA, Mallidi HR. J Thorac Cardiovasc Surg Tech. 2020; in press.*

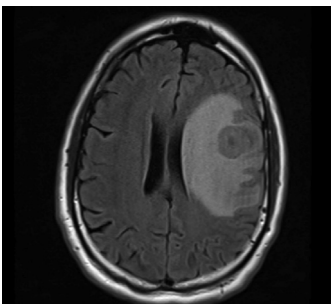
Thymus



STCVS: Robotic-extended rethymectomy for refractory myasthenia gravis: A case series. *Li F, Li Z, Takahashi R, et al. Semin Thorac Cardiovasc Surg. 2020; in press.*

Commentary: Robotic-re-thymectomy: a surgical effective chance to treat refractory myasthenia gravis. *Filosso PL, Lyberis P, Guerrero F, Ruffini E. Semin Thorac Cardiovasc Surg. 2020; in press.*

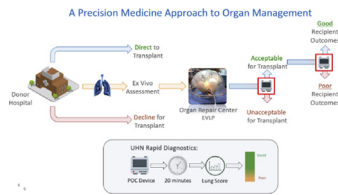
Pleura



JTCVS TECHNIQUES CASE REPORT: Successful treatment of a patient with oligometastatic mesothelioma to the brain. *J Thorac Cardiovasc Surg Tech. 2020; in press.*

Commentary: When cancer is oligometastatic even mesothelioma is curable. *J Thorac Cardiovasc Surg Tech. 2020; in press.*

Lung Transplant



JTCVS OPEN INVITED EXPERT OPINION: Human organ repair centers: Fact or fiction? *Keshavjee S.* J Thorac Cardiovasc Surg Open. 2020; in press.

Commentary: Quo vadis EVLP – regionalization or centralization? *Hoetzenecher K.* J Thorac Cardiovasc Surg Open. 2020; in press.

Commentary: Changing the equation by boosting the numerator. *Najmeh S, Hartwig MG.* J Thorac Cardiovasc Surg Open. 2020; In press.

Perioperative Management

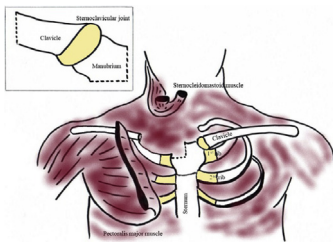
- Screening patients 24-48 hours prior to surgery using nasopharyngeal swab PCR testing and low-dose chest CT scan.
- Port-access surgical approach where possible.
- Device for intraoperative CO₂ insufflation with continuous smoke/aerosol removal and filtration.
- Desufflation of the thoracic cavity prior to all instrument changes and specimen removal.
- Minimization of instrument changes for lymph node removal using a simple bagging method.
- Use of a continuous suction system with filtration in thoracotomy cases.

JTCVS TECHNIQUES SURGICAL TECHNIQUE: COVIDSafe thoracic surgery: Minimizing intraoperative exposure to aerosols. *Seco M, Wood J, Wilson MK.* J Thorac Cardiovasc Surg Tech. 2020; in press.

Commentary: A breath of fresh air for thoracic surgeons in the covid era. *Wightman SC, David EA.* J Thorac Cardiovasc Surg Tech. 2020; in press.

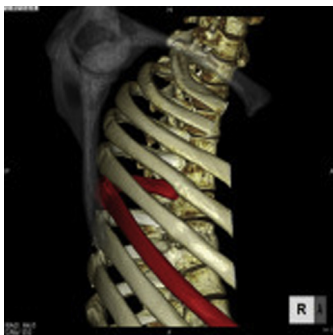Commentary: This port's for YOU! *Ceppa DP.* J Thorac Cardiovasc Surg Tech. 2020; in press.

Thoracic: Other



STCVS: Sternoclavicular joint infections: Improved outcomes with myocutaneous flaps. *Ali B, Shetty A, Qeadan F, Demas C, Schwartz JD.* Semin Thorac Cardiovasc Surg. 2020;32(2): 369-376. doi:10.1053/j.semtcvs.2019.12.007.

Commentary: One and done. *Weber F.* Semin Thorac Cardiovasc Surg. 2020;32(2):377. doi:10.1053/j.semtcvs.2020.02.014.



JTCVS TECHNIQUES CASE REPORT: Snapping scapula due to traumatic costal fractures: A case report. *Nakamoto K, Sumiura S, Hashiyada H, Kiya S.* J Thorac Cardiovasc Surg Tech. 2020; in press.

Commentary: Scapulocostal syndrome after trauma: A snap caused by a break. *Weksler B.* J Thorac Cardiovasc Surg Tech. 2020; in press.

Commentary: The complete cardiothoracic surgeon: give me a rib - - - plate. *Lazzaro R, Patton B.* J Thorac Cardiovasc Surg Tech. 2020; in press.