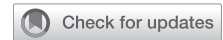


See Article page 544.



## Commentary: Fluorodeoxyglucose–positron emission tomography/computed tomography for cervical adenopathy in esophageal carcinoma, an option for the selective surgeon

Wayne Hofstetter, MD

There are juxtaposed opinions in the literature as to the efficacy of fluorodeoxyglucose–positron emission tomography/computed tomography (FDG-PET/CT) for evaluating cervical lymph nodes in esophageal cancer. Much of this debate resides within a larger, more contentious issue—the potential treatment options for the cervical nodal basin. On one hand, 3-field dissection performed by experienced surgeons historically emerged as superior to lesser dissection. The vast experience of Akiyama and colleagues<sup>1</sup> was described in their manuscript from 1994, in which patients treated with 3-field esophagectomy were found to have frequent incidence of cervical adenopathy (27%). In that study, patients who harbored disease in the cervicothoracic nodes who had undergone aggressive surgery showed survival that was comparable with other sites of regional disease but superior compared with 2-field dissection. These findings were recapitulated in an American study by Altorki and Skinner,<sup>2</sup> indicating that occult disease in cervicothoracic nodes was as high as 36% even in patients with disease in the lower esophagus. Advocates of 3-field dissection cite reasonable survival in the face of stage IV disease with en bloc surgery alone and groups that practice in this manner do not need further studies to detect disease above the



Wayne Hofstetter, MD

### CENTRAL MESSAGE

In locally advanced esophageal cancer, PET alone may be adequate for stage. Patients who lack a PET or have early proximal disease may benefit from neck ultrasound as an alternative staging modality.

clavicles. Need for PET in these situations would be limited to discovery of metastatic disease or for prognosis.

On the other hand, perioperative morbidity related to injury of the recurrent nerves and an increase in perioperative mortality reported with 3-field dissection have steered some surgeons to advocate for selective dissection of the recurrent laryngeal and cervical nodes. Widespread adoption of multimodality therapy for locally advanced cancers has similarly led surgeons away from extensive 3-field dissections. In using a selective approach to nodal basins, surgeons need to decide on the management of the cervicothoracic areas, and this is reiterated for the radiation oncologist if one chooses multimodality therapy. We need reliable clinical outcomes data and staging modalities upon which to base the decision as to where regional treatment extends. Stiles and colleagues<sup>3</sup> have advocated that any locally advanced squamous cancer or upper thoracic adenocarcinoma should undergo 3-field dissection, yet there is still debate as to what a locally advanced cancer should be defined as. As exemplified in the paper of Akiyama and colleagues,<sup>1</sup> even T1b depth of invasion should be considered a dangerous cancer. In defining patients at risk for cervical nodal spread, one variable was a common finding in both Altorki and Akiyama's data; overall number of involved nodes is clearly an indicator of prognosis and cervical nodal involvement, and this was independent of tumor location.<sup>4,5</sup> We are left to conclude

From the Department of Thoracic and Cardiovascular Surgery, University of Texas, MD Anderson Cancer Center, Houston, Tex.

Disclosures: Consulting for Johnson and Johnson and Ethicon, research funding from Neuwave.

Received for publication Nov 26, 2019; revisions received Nov 26, 2019; accepted for publication Nov 27, 2019; available ahead of print Dec 14, 2019.

Address for reprints: Wayne Hofstetter, MD, Department of Thoracic and Cardiovascular Surgery, University of Texas, MD Anderson Cancer Center, Houston, TX.

J Thorac Cardiovasc Surg 2020;160:551-2

0022-5223/\$36.00

Copyright © 2019 by The American Association for Thoracic Surgery

<https://doi.org/10.1016/j.jtcvs.2019.11.110>

that disease beyond cN1 has a greater likelihood of upper thoracic and cervical adenopathy, but histology and disease location also play a role in the finding of occult disease in the cervical and upper thoracic nodes. Therefore, one method of determining treatment extent could be based on pretreatment clinical variables alone.

Imaging methods may also help refine which patients require more extensive fields of treatment. In the current paper by Li and colleagues,<sup>6</sup> the performance of FDG-PET/CT was evaluated for accuracy in detecting disease spread to cervicothoracic nodes. The authors note that PET was not accurate in their patient population and did not add any value over a less-expensive neck ultrasound. These findings are in contrast to other recent publications. In a recent paper by Goense and colleagues,<sup>7</sup> PET/CT was found to be both sensitive and specific for disease located in cervical nodes (82% and 91%, respectively). However, as opposed to the study by Li and colleagues,<sup>6</sup> an ultrasound-directed node biopsy revealing tumor in cervical nodes was preclusive of surgery in this group's study.<sup>7</sup> Outside of their study, surgeons from the study by Li and colleagues<sup>6</sup> selectively use 3-field dissection based on findings from imaging and ultrasound. These conflicting findings between the 2 studies are not altogether exclusive nor unanticipated if we adjust for clinical stage and expected prevalence of disease. Although clinical stage was not captured as a data point in the study by Li and colleagues,<sup>6</sup> they did report that in patients with clinical suspicion of cervical nodal involvement that the sensitivity and specificity of PET increased to 78% and 86%. These data are entirely aligned with data from our study indicating that in early-stage disease, FDG/PET CT accuracy of nodal disease was very poor.<sup>8</sup> Based on available data, we would expect that earlier clinical stage disease would pull PET

accuracy down based on false +/- findings, but the negative predictive value of cervicothoracic involvement in locally advanced disease can be fairly reliable.

In summary, the data seem to indicate that for more advanced disease, an FDG/PET-CT may be used as a clinical tool. However, if one chooses to avoid using PET, an ultrasound is cheaper, may be more reliable for early disease, and can function as image guidance for a biopsy that may change the modality of therapy being considered. For those surgeons who perform 3-field dissection routinely, the current study would not change practice.

## References

1. Akiyama H, Tsurumaru M, Udagawa H, Kajiyama Y. Radical lymph node dissection for cancer of the thoracic esophagus. *Ann Surg.* 1994;220:364-72; discussion 372-3.
2. Altorki NK, Skinner DB. Occult cervical nodal metastasis in esophageal cancer: preliminary results of three-field lymphadenectomy. *J Thorac Cardiovasc Surg.* 1997;113:540-4.
3. Stiles BM, Mirza F, Port JL, Lee PC, Paul S, Christos P, et al. Predictors of cervical and recurrent laryngeal lymph node metastases from esophageal cancer. *Ann Thorac Surg.* 2010;90:1805-11; discussion 1811.
4. Altorki N, Kent M, Ferrara C, Port J. Three-field lymph node dissection for squamous cell and adenocarcinoma of the esophagus. *Ann Surg.* 2002;236:177-83.
5. Kunisaki C, Makino H, Kimura J, Oshima T, Fujii S, Takagawa R, et al. Impact of lymph-node metastasis site in patients with thoracic esophageal cancer. *J Surg Oncol.* 2010;101:36-42.
6. Li B, Li N, Liu S, Li Y, Qian B, Zhang Y, et al. Does [18F] fluorodeoxyglucose-positron emission tomography/computed tomography have a role in cervical nodal staging for esophageal squamous cell carcinoma? *J Thorac Cardiovasc Surg.* 2020;160:544-50.
7. Goense L, Meziani J, van Rossum PSN, Wessels FJ, Lam MGEH, van Hellegersberg R, et al. Cervical ultrasonography has no additional value over negative (18)F-FDG PET/CT scans for diagnosing cervical lymph node metastases in patients with oesophageal cancer. *Eur Radiol.* 2018;28:2031-7.
8. Cuellar SL, Carter BW, Macapinlac HA, Ajani JA, Komaki R, Welsh JW, et al. Clinical staging of patients with early esophageal adenocarcinoma: does FDG-PET/CT have a role? *J Thorac Oncol.* 2014;9:1202-6.