



# Severe Acute Respiratory Syndrome Coronavirus 2 Infection and Thrombosis: Phlegmasia Cerulea Dolens Presenting with Venous Gangrene in a Child

Gautam K. Visveswaran, MD<sup>1</sup>, Kavita Morparia, MD<sup>2</sup>, Shalu Narang, MD, MPH<sup>2</sup>, Cindy Sturt, MD<sup>3</sup>, Michael Divita, MD<sup>1</sup>, Brett Voigt, DO<sup>3</sup>, Amer Hawatmeh, MD<sup>1</sup>, Derrick McQueen, MD<sup>2</sup>, and Marc Cohen, MD<sup>1</sup>

A 12-year-old girl with severe acute respiratory syndrome coronavirus 2 infection presented as phlegmasia cerulea dolens with venous gangrene. Emergent mechanical thrombectomy was complicated by a massive pulmonary embolism and cardiac arrest, for which extracorporeal cardiopulmonary resuscitation and therapeutic hypothermia were used. Staged ultrasound-assisted catheter-directed thrombolysis was used for treatment of bilateral pulmonary emboli and the extensive lower extremity deep vein thrombosis while the patient received extracorporeal membrane oxygenation support. We highlight the need for heightened suspicion for occult severe acute respiratory syndrome coronavirus 2 infection among children presenting with unusual thrombotic complications. (*J Pediatr* 2020;226:281-4).

**P**hlegmasia cerulea dolens (PCD) is characterized by extensive venous thrombosis and severe venous outflow obstruction presents with painful limb swelling, cyanosis, and gangrene in extreme cases. Occurrence of PCD in healthy pediatric patients is rare.<sup>1-3</sup> Potential protective mechanisms cited include a decreased capacity for thrombin generation, increased alpha-2 macroglobulin inhibition of thrombin, and the antithrombotic potential of the vessel wall.<sup>2</sup> Among adult and pediatric patients, malignancy, sepsis, surgery, hypercoagulable state, and vascular injury (indwelling central lines) predispose to PCD.<sup>2-4</sup>

Coronavirus disease associated with the severe acute respiratory syndrome coronavirus 2 (SARS-CoV-2) is associated with a hypercoagulable state among adults, as is the multisystem inflammatory syndrome in children.<sup>5-8</sup> We report the case of a girl with PCD and venous gangrene in association with SARS-CoV-2 infection.

## Case Description

A 12-year-old previously healthy girl (body mass index of 20.1 kg/m<sup>2</sup>) had acute onset of painful swelling of her left leg without dyspnea or fever. She was evaluated 5 days prior for painful erythema of the left thigh of 5 days' duration,

which was diagnosed as cellulitis and treated with oral trimethoprim-sulfamethoxazole. No intercurrent illness, sick contacts, long distance travel, familial thrombophilia, or trauma were reported. Vital signs on admission were blood pressure of 135/76 mm Hg, heart rate of 140 b/minute (sinus tachycardia), respiratory rate of 20 breaths/minute, and temperature of 98.2°F. Examination revealed marked swelling of the entire left leg that was cool to the touch. Her left foot was ecchymotic with decreased sensation and inability to flex toes, but dorsalis pedis and posterior tibial pulses were palpable (**Figure 1**). Laboratory tests before unfractionated heparin administration showed thrombocytopenia (126 000/ $\mu$ L), prolonged prothrombin time of 18 seconds (normal high, 13.4 seconds), partial thromboplastin time of 88.3 seconds (normal high, 36.6 seconds), elevated D-dimer 1953 ng/mL (high normal,  $\leq$ 243 ng/mL), and factor VIII activity 259.4% (normal range, 62%-194%). Her erythrocyte sedimentation rate was >130 mm/hour (normal high, 13 mm/hour) and C-reactive protein was 14.8 mg/dL (normal high, 0.5 mg/dL).

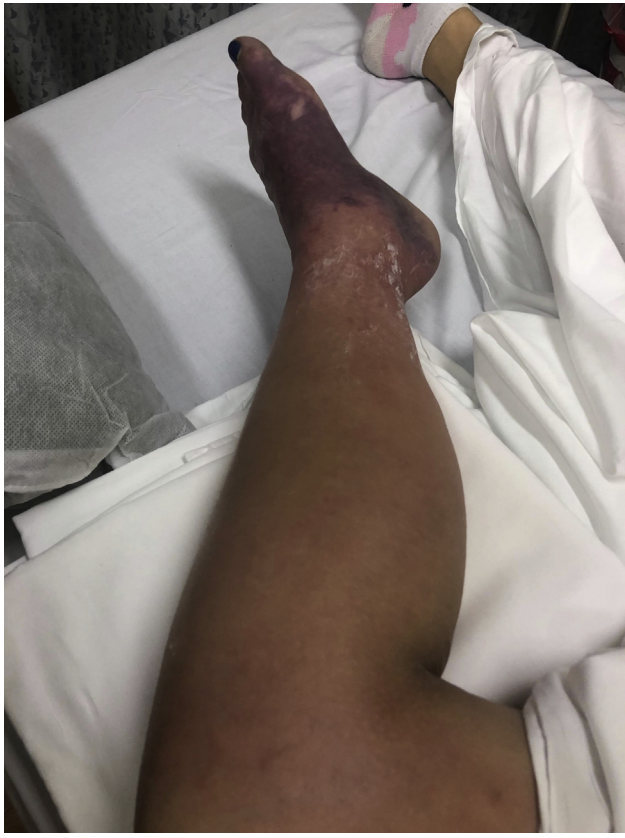Because catheter-directed lysis requires hours for revascularization, we proceeded to percutaneous mechanical venous thrombectomy. Venography confirmed extensive popliteal-to-common iliac vein thrombosis and excluded inferior vena cava (IVC) clot (**Video 1** and **Video 2**; available at [www.jpeds.com](http://www.jpeds.com)). ClotTrier mechanical thrombectomy (Inari Medical, Irvine, California) retrieved a white and red fibrin-rich clot. Thrombectomy was complicated by hypotension, bradycardia, and pulseless electrical activity, for which cardiopulmonary resuscitation was initiated.

APLA	Antiphospholipid antibodies
APS	Antiphospholipid syndrome
COVID-19	Coronavirus disease 19
DIC	Disseminated intravascular coagulation
ECMO	Extracorporeal membrane oxygenation
IVC	Inferior vena cava
PCD	Phlegmasia cerulea dolens
PE	Pulmonary embolism
RV	Right ventricular
SARS-CoV-2	Severe acute respiratory syndrome coronavirus 2
TPA	Tissue plasminogen activator
UCDT	Ultrasound-assisted catheter-directed thrombolysis

From the <sup>1</sup>Division of Cardiology; <sup>2</sup>Children's Hospital of New Jersey; and <sup>3</sup>Division of Vascular Surgery, Newark Beth Israel Medical Center, Newark, NJ

The authors declare no conflicts of interest.

0022-3476/\$ - see front matter. © 2020 Elsevier Inc. All rights reserved.  
<https://doi.org/10.1016/j.jpeds.2020.07.032>



**Figure 1.** Severely swollen, painful, cyanotic left lower extremity on presentation.

Echocardiogram revealed severe right ventricular (RV) dilation with severe hypokinesia consistent with acute massive pulmonary embolism (PE). A multidisciplinary decision was made to initiate peripheral venoarterial extracorporeal membrane oxygenation (ECMO). Unfractionated heparin adjusted to an activated clotting time of 190-200 seconds was continued throughout the ECMO run. Given prolonged resuscitation of about 30-45 minutes, we initiated therapeutic hypothermia via the ECMO circuit. Admission SARS-CoV-2 nasopharyngeal reverse transcriptase-polymerase chain reaction testing was negative. Fibrinogen level drawn post ECMO initiation was 191 mg/dL (normal range, 210-400 mg/dL). Her initial thrombophilia workup was negative for most risk factors but was positive for antiphospholipid antibodies (APLA) (Table).

Day 1 echocardiogram revealed persistent severe RV systolic dysfunction. Continued need for high-dose epinephrine (0.08  $\mu\text{g}/\text{kg}/\text{min}$ ), milrinone (0.5  $\mu\text{g}/\text{kg}/\text{min}$ ) with narrow arterial pulse pressure (20 mm Hg) while on ECMO support (flow, 2.5-2.7 L/hour; 60 mL/kg/min) prompted us to undertake EkoSonic ultrasound-assisted catheter-directed thrombolysis (UCDT) of the PE. Pulmonary angiography confirmed extensive emboli in the superior, middle, and inferior segments of the right lung; the lingular segment of the left lung; and interlobular pulmonary arteries. Bilateral

**Table. Thrombophilia investigation**

Thrombophilic risk factors	Results
Factor V Leiden	Negative
Prothrombin gene mutation	Negative
<i>MTHFR</i> gene mutation	Positive for 1 copy of C677T variant
Protein C	67% (67%-141%)
Protein S, free	28%* (55%-124%)
Antithrombin III	55% (72%-129%)
Lupus anticoagulant: DRVVT; lupus anticoagulant ratio	79.6 seconds (28-48); 1.5 (0.8-1.2)
Cardiolipin antibody	IgA <11, IgG 73 ( $\leq 14$ ), IgM 31 ( $\leq 12$ )
Beta 2 glycoprotein 1	IgA <9, IgG 58 ( $\leq 20$ ), IgM <9
Lipoprotein (a)	67.3 nmol/L (<75)

DRVVT, dilute Russell's viper venom time.

Normal range, if applicable, in parentheses.

\*Repeat in 4 weeks was normal at 89%.

UCDT catheters infusing tissue plasminogen activator (TPA) at 1 mg/lung/hour for 6 hours (12 mg total dose) facilitated thrombolysis.<sup>9</sup> Epinephrine was discontinued within 24 hours of thrombolysis and a 40 mm Hg arterial pulse pressure was noted with echocardiogram confirming improvement in RV size and function. Given hemodynamic improvement, we undertook venous thrombolysis to improve limb prognosis. An infrahepatic venous filter was deployed after excluding an IVC clot. Venography confirmed extensive thrombosis from the posterior tibial vein to the common iliac vein (Figure 2, A-C; available at [www.jpeds.com](http://www.jpeds.com)). Rheolytic thrombectomy (Angiojet [Boston Scientific, Marlborough, Massachusetts] with powerpulse) was undertaken using TPA in solution (20 mg total).<sup>10</sup> EkoSonic UCDT catheters were positioned via the common femoral vein traversing beyond the common iliac vein, and a second catheter via the posterior tibial vein extending into the common femoral vein (0.5 mg/hour/catheter for an hourly dose of 1 mg). Mild acute disseminated intravascular coagulation (DIC) mandated TPA discontinuation at 7 hours of UCDT and transfusion support corrected the DIC. Venoarterial ECMO was decannulated after 64 hours of support with primary repair of the arteries. Venography demonstrated improved venous outflow into the IVC with markedly decreased thrombus burden. Paralytics and sedation were weaned on day 4 and she awoke, followed commands, and was successfully extubated to oxygen via nasal cannula. Complete normalization of her RV function was noted on day 7 echocardiogram (Video 3; available at [www.jpeds.com](http://www.jpeds.com)).

The patient was given solumedrol 1 g (23 mg/kg) daily for 3 doses, followed by a taper. Plasmapheresis was undertaken daily for 5 days, and 3 times afterward for a total of 8 treatments. Empiric antibiotics with vancomycin and cefepime were administered for 5 days. Cyanosis subsequently was isolated to the toes, with improved perfusion to the mid foot. The SARS-CoV-2 IgG and IgM antibody titers drawn on hospital day 5, after 3 plasmapheresis sessions, were negative. Repeat testing using paired sera (hospitalization day 16/day 20) revealed up trending positive SARS-CoV-2 IgM antibody titers 28.8 units (day16) to 43.2 units (day 20) (reference

valve, <9.0 units) and negative SARS-CoV-2 IgG titers.<sup>11</sup> She underwent hyperbaric oxygen treatments with improvement in sensorimotor deficits, but with continued severe cyanosis of all toes. She was discharged home on day 20 of hospitalization without neurologic deficits (Pediatric Cerebral Performance Category 1) on amlodipine, a prednisone taper, therapeutic enoxaparin, and gabapentin for continued neuropathic pain.

## Discussion

Coronavirus disease 19 (COVID)-19 respiratory syndrome is associated with a hypercoagulable state in adults.<sup>5,6</sup> Severe hypoxia, systemic inflammation, sepsis, cytokine surge, and an “endothelitis” prompting prothrombotic states have been postulated mechanisms.<sup>12,13</sup> An elevated D-dimer, low normal or normal fibrinogen level, elevated fibrin degradation products, mild thrombocytopenia, and mildly elevated partial thromboplastin time in adults with severe COVID-19 has led some investigators to postulate the occurrence of a compensated DIC syndrome.<sup>14,15</sup> Nonsurvivors met International Society of Thrombosis and Hemostasis criteria for DIC in 71.4% of patients vs 0.6% among COVID-19 survivors in 1 intensive care unit study.<sup>15</sup> Admission coagulation tests were markedly abnormal in our patient. She met International Society of Thrombosis and Hemostasis criteria for nonovert DIC; International Society of Thrombosis and Hemostasis DIC score 4: prolonged prothrombin time (1 point) and severely elevated D-dimer (3 points).<sup>16</sup> Importantly, her investigation for acute infection was negative. Thrombophilia workup was positive for APLA. Pediatric primary antiphospholipid syndrome (APS) is rare, and disease onset before age 15 years is reported in only 2.8% of all pediatric APS. Although arterial thrombosis is more often associated with primary APS, deep vein thrombosis is predominantly seen with secondary APS.<sup>17</sup> Adult COVID-19-associated APLA and lupus anticoagulant have been reported.<sup>18,19</sup> With repeat confirmatory APS testing pending, given the rarity of pediatric PCD, admission DIC score of 4 with positive APLA and anti-SARS-CoV-2 IgM assay, we opine that the PCD likely was the result of a community-acquired SARS-CoV-2-induced hypercoagulable state. Phlegmasia in an adult COVID-19 patient managed with unfractionated heparin has recently been reported.<sup>20</sup>

SARS-CoV-2 infection is now known to cause pediatric multisystem inflammatory syndrome-children (with significant associated morbidity and mortality).<sup>21-23</sup> Chilblain-like lesions, labeled “COVID toes,” are the predominant dermatologic manifestation reported among otherwise healthy older children with a strong epidemiologic association with COVID-19.<sup>24</sup> Predominantly involving bilateral toes and feet, COVID toes are characterized by erythematous macules/papules, purpuric lesions with pruritis, and mild pain with rare acroischemia reported.<sup>24,25</sup> Reports indicate that most patients test negative on nasopharyngeal reverse transcriptase-polymerase chain reaction tests and for IgG and IgM antibodies to SARS-CoV-2.<sup>24</sup> Coagulation studies

and lupus anticoagulant tests usually are normal.<sup>26</sup> Vascular microthrombus formation is suspected. Spontaneous resolution without significant sequelae is common.<sup>24,26</sup>

Our patient presented with venous gangrene and an acutely threatened limb. Emergent mechanical thrombectomy was complicated by a massive PE and cardiac arrest. Absence of an IVC clot, her adolescent age, known complications of IVC filters, and the purported design advantages of the ClotTriever with a coring element and a nitinol collection bag for distal protection biased our decision not to insert a prophylactic IVC filter.<sup>27,28</sup> In retrospect, filter placement likely would have captured dislodged emboli and prevented cardiac arrest.<sup>29</sup> Systemic thrombolysis was considered but, given the nonperfusing rhythm and add on time (TPA bolus over ~15 minutes plus time for TPA action), institution of venoarterial ECMO was warranted clinically. Improved survival (40% vs 27%) and survival with favorable neurologic outcome (27% vs 18%) have been reported with use of extracorporeal cardiopulmonary resuscitation vs conventional cardiopulmonary resuscitation in pediatric in-hospital cardiac arrest.<sup>30</sup> Central nervous system events (ischemic stroke, intracranial hemorrhage, and brain death) and bleeding negatively impact extracorporeal cardiopulmonary resuscitation outcomes.<sup>31,32</sup> Therapeutic hypothermia likely contributed to her complete neurologic recovery. A staged EkoSonic UCdT for bilateral PE facilitated early ECMO decannulation.<sup>33</sup> UCdT has been shown to decrease the burden of pulmonary embolus, decrease pulmonary pressures and facilitate early RV recovery.<sup>9,34</sup> Rheolytic thrombectomy plus UDCT significantly improved venous outflow and prevented major amputation. Systemic or catheter-directed thrombolysis also has been shown to decrease the risk of post-thrombotic syndrome in children.<sup>35</sup> Adjunctive corticosteroid therapy and plasmapheresis was undertaken upon the finding of APLA. Plasmapheresis likely confounded SARS-CoV-2 antibody testing. Repeated serology confirmed our suspicion of relationship to SARS-CoV-2 infection.

SARS-CoV-2 infection should be considered in the differential diagnosis for children with unusual thrombotic presentations. Earlier detection and treatment of coagulopathy may prevent severe complications of the nature described here. ■

*We thank the dedicated nursing staff of the pediatric intensive care unit, surgical, and catheterization laboratory for the exceptional care delivered.*

Submitted for publication Jun 10, 2020; last revision received Jul 6, 2020; accepted Jul 8, 2020.


Reprint requests: Gautam K. Visveswaran, MD, Division of Cardiology, Newark Beth Israel Medical Center, Newark, NJ 07112. E-mail: [gaukart2925@gmail.com](mailto:gaukart2925@gmail.com)

## References

1. Kuo I, Smith J, Abou-Zamzam AM. A multimodal therapeutic approach to phlegmasia cerulea dolens in a pediatric patient. *J Vasc Surg* 2011;53: 212-5.

2. Spentzouris G, Scriven RJ, Lee TK, Labropoulos N. Pediatric venous thromboembolism in relation to adults. *J Vasc Surg* 2012;55:1785-93.
3. Tran J, Rafique Z. Phlegmasia cerulea dolens in the pediatric population: a life-threatening condition. *J Emerg Med* 2015;49:e111-4.
4. Ibrahim H, Krouskop R, Jeroudi M, McCulloch C, Parupia H, Dhanireddy R. Venous gangrene of lower extremities and Staphylococcus aureus sepsis. *J Perinatol* 2001;21:136-40.
5. Middeldorp S, Coppens M, van Haaps TF, Foppen M, Vlaar AP, Müller MCA, et al. Incidence of venous thromboembolism in hospitalized patients with COVID-19. *J Thromb Haemost* 2020;18:1995-2002.
6. Klok FA, Kruip MJHA, van der Meer NJM, Arbous MS, Gommers DAMPJ, Kant KM, et al. Incidence of thrombotic complications in critically ill ICU patients with COVID-19. *Thromb Res* 2020;191:145-7.
7. Capone CA, Subramony A, Sweberg T, Schneider J, Shah S, Rubin L, et al. Characteristics, cardiac involvement, and outcomes of multi-system inflammatory syndrome of childhood associated with severe acute respiratory syndrome coronavirus 2 infection. *J Pediatr* 2020;224:141-5.
8. Kaushik S, Aydin SI, Derespina KR, Bansal PB, Kowalsky S, Trachtman R, et al. Multisystem inflammatory syndrome in children associated with severe acute respiratory syndrome coronavirus 2 infection (MIS-C): a multi-institutional study from New York City. *J Pediatr* 2020;224:24-9.
9. Tapson VF, Sterling K, Jones N, Elder M, Tripathy U, Brower J, et al. A randomized trial of the optimum duration of acoustic pulse thrombolysis procedure in acute intermediate-risk pulmonary embolism: the OPTALYSE PE Trial. *JACC Cardiovasc Interv* 2018;11:1401-10.
10. Rao AS, Konig G, Leers SA, Cho J, Rhee RY, Makaroun MS, et al. Pharmacomechanical thrombectomy for iliofemoral deep vein thrombosis: an alternative in patients with contraindications to thrombolysis. *J Vasc Surg* 2009;50:1092-8.
11. Sethuraman N, Jeremiah SS, Ryo A. Interpreting Diagnostic Tests for SARS-CoV-2. *JAMA* 2020.
12. Boccia M, Aronne L, Celia B, Mazzeo G, Ceparano M, D'Agnano V, et al. COVID-19 and coagulative axis: review of emerging aspects in a novel disease. *Monaldi Arch Chest Dis* 2020;90:271-6.
13. Varga Z, Flammer AJ, Steiger P, Haberecker M, Andermatt R, Zinkernagel AS, et al. Endothelial cell infection and endotheliitis in COVID-19. *Lancet* 2020;395:1417-8.
14. Thachil J, Tang N, Gando S, Falanga A, Cattaneo M, Levi M, et al. ISTH interim guidance on recognition and management of coagulopathy in COVID-19. *J Thromb Haemost* 2020;18:1023-6.
15. Tang N, Li D, Wang X, Sun Z. Abnormal coagulation parameters are associated with poor prognosis in patients with novel coronavirus pneumonia. *J Thromb Haemost* 2020;18:844-7.
16. Taylor F, Toh C-H, Hoots K, Wada H, Levi M. Towards definition, clinical and laboratory criteria, and a scoring system for disseminated intravascular coagulation. *Thromb Haemost* 2001;86:1327-30.
17. Kenet G, Aronis S, Berkun Y, Bonduel M, Chan A, Goldenberg NA, et al. Impact of persistent antiphospholipid antibodies on risk of incident symptomatic thromboembolism in children: a systematic review and meta-analysis. *Semin Thromb Hemost* 2011;37:802-9.
18. Zhang Y, Xiao M, Zhang S, Xia P, Cao W, Jiang W, et al. Coagulopathy and antiphospholipid antibodies in patients with Covid-19. *N Engl J Med* 2020:1-3.
19. Bowles L, Platton S, Yartey N, Dave M, Lee K, Hart DP, et al. Lupus anticoagulant and abnormal coagulation tests in patients with Covid-19. *N Engl J Med* 2020;383:288-90.
20. Morales MH, Leigh CL, Simon EL. COVID-19 infection with extensive thrombosis: a case of phlegmasia cerulea dolens. *Am J Emerg Med* 2020 [Epub ahead of print].
21. Shekerdeman LS, Mahmood NR, Wolfe KK, Riggs BJ, Ross CE, McKiernan CA, et al. Characteristics and outcomes of children with coronavirus disease 2019 (COVID-19) infection admitted to US and Canadian pediatric intensive care units. *JAMA Pediatr* 2020 [Epub ahead of print].
22. Riphagen S, Gomez X, Gonzalez-Martinez C, Wilkinson N, Theocharis P. Hyperinflammatory shock in children during COVID-19 pandemic. *Lancet* 2020;395:1607-8.
23. Belhadjer Z, Bonnet D. Acute heart failure in multisystem inflammatory syndrome in children (MIS-C ) in the context of global SARS-CoV-2 pandemic. *Circulation* 2020;33.
24. El Hachem M, Diociaiuti A, Concato C, Carsetti R, Carnevale C, Ciofi Degli Atti M, et al. A clinical, histopathological and laboratory study of 19 consecutive Italian paediatric patients with chilblain-like lesions: lights and shadows on the relationship with COVID-19 infection. *J Eur Acad Dermatol Venereol* 2020 [Epub ahead of print].
25. Mazzotta F, Troccoli T. Acute acro-ischemia in the child at the time of Covid-19. *Dermatologia Pediatr* 2020;3-5.
26. Andina D, Noguera-Morel L, Bascuas-Arribas M, Gaitero-Tristán J, Alonso-Cadenas JA, Escalada-Pellitero S, et al. Chilblains in children in the setting of COVID-19 pandemic. *Pediatr Dermatol* 2020;37:406-11.
27. Mouawad NJ. Effective single-session percutaneous nonpharmacologic mechanical thrombectomy for phlegmasia cerulea dolens. *J Vasc Surg Cases Innov Tech* 2020;6:212-5.
28. Benarroch-Gampel J, Pujari A, Aizpuru M, Rajani RR, Jordan WD, Crawford R. Technical success and short-term outcomes after treatment of lower extremity deep vein thrombosis with the ClotTriever system: a preliminary experience. *J Vasc Surg Venous Lymphat Disord* 2020;8:174-81.
29. Lee SH, Kim HK, Hwang JK, Kim SD, Park SC, Kim JI, et al. Efficacy of retrievable inferior vena cava filter placement in the prevention of pulmonary embolism during catheter-directed thrombectomy for proximal lower-extremity deep vein thrombosis. *Ann Vasc Surg* 2016;33:181-6.
30. Lasa J, Rogers R, Localio R, Shults J, Raymond T, Gaies M, et al. Extracorporeal-cardiopulmonary resuscitation (E-CPR) during pediatric in-hospital cardiopulmonary arrest is associated with improved survival to discharge: a report from the American Heart Association's Get With the Guidelines®-Resuscitation Registry (GWT). *Circulation* 2016;133:165-76.
31. Barbaro RP, Paden ML, Guner YS, Raman L, Ryerson LM, Alexander P, et al. Pediatric Extracorporeal Life Support Organization Registry International Report 2016. *ASAIO J* 2017;63:456-63.
32. Brunetti MA, Gaynor JW, Retzlaff LB, Lehigh JL, Banerjee M, Amula V, et al. Characteristics, risk factors & outcomes of extracorporeal membrane oxygenation use in pediatric cardiac intensive care units: a report from the PC4 Registry. *Pediatr Crit Care Med* 2018;19:544-52.
33. Bavare AC, Naik SX, Lin PH, Poi MJ, Yee DL, Bronicki RA, et al. Catheter-directed thrombolysis for severe pulmonary embolism in pediatric patients. *Ann Vasc Surg* 2014;28:1794.e1-7.
34. Piazza G, Hohlfelder B, Jaff MR, Ouriel K, Engelhardt TC, Sterling KM, et al. A prospective, single-arm, multicenter trial of ultrasound-facilitated, catheter-directed, low-dose fibrinolysis for acute massive and submassive pulmonary embolism: the SEATTLE II Study. *JACC Cardiovasc Interv* 2015;8:1382-92.
35. Goldenberg NA, Durham JD, Knapp-Clevenger R, Manco-Johnson MJ. Athrombolytic regimen for high-risk deep venous thrombosis may substantially reduce the risk of postthrombotic syndrome in children. *Blood* 2007;110:45-53.





**Figure 2.** Extensive venous thrombosis of the **A**, left posterior tibial **B**, femoral vein to **C**, left common iliac vein.