

Multiplex immunohistochemistry/immunofluorescence (mIHC/IF) for PD-L1 testing in triple-negative breast cancer: a translational assay compared with conventional IHC

Joe Yeong ^{1,2,3} Tira Tan,⁴ Zi Long Chow,^{1,5} Qing Cheng,⁶ Burnett Lee,³ Amanda Seet,⁴ Johnathan Xiande Lim,¹ Jeffrey Chun Tatt Lim,² Clara Chong Hui Ong,^{1,7} Aye Aye Thike,¹ Sahil Saraf,¹ Benjamin, Yong Cheng Tan,¹ Yong Cheng Poh,⁸ Sidney Yee,⁸ Jin Liu,⁶ Elaine Lim,⁴ Javed Iqbal,¹ Rebecca Dent,⁴ Puay Hoon Tan¹

► Additional material is published online only. To view please visit the journal online (<http://dx.doi.org/10.1136/jclinpath-2019-206252>).

For numbered affiliations see end of article.

Correspondence to

Dr Joe Yeong, Pathology, Singapore General Hospital, Singapore 169856, Singapore; joe.yeong.p.s@sgh.com.sg Professor Puay Hoon Tan; tan.puay.hoon@singhealth.com.sg

JY and PHT are joint senior authors.

Received 6 October 2019
Revised 23 December 2019
Accepted 31 December 2019
Published Online First
22 January 2020

ABSTRACT

Background Programmed death-ligand 1 (PD-L1) monoclonal antibody therapy has recently gained approval for treating metastatic triple-negative breast cancer (TNBC), in particular in the PD-L1⁺ patient subgroup of the recent IMpassion130 trial. The SP142 PD-L1 antibody clone was used as a predictive assay in this trial, but this clone was found to be an outlier in previous harmonisation studies in lung cancer.

Aims To address the comparability of PD-L1 clones in TNBC, we evaluated the concordance between conventional immunohistochemistry (IHC) and multiplex immunohistochemistry/immunofluorescence (mIHC/IF) that allowed simultaneous quantification of three different PD-L1 antibodies (22C3, SP142 and SP263).

Methods Our cohort comprised 25 TNBC cases, 12 non-small-cell lung carcinomas and 8 other cancers. EpCAM labelling was used to distinguish tumour cells from immune cells.

Results Moderate-to-strong correlations in PD-L1 positivity were found between results obtained through mIHC/IF and IHC. Individual concordance rates in the study ranged from 67% to 100%, with Spearman's rank correlation coefficient values up to 0.88.

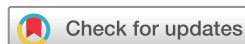Conclusions mIHC/IF represents a promising tool in the era of cancer immunotherapy, as it can simultaneously detect and quantify PD-L1 labelling with multiple antibody clones, and allow accurate evaluation of tumour and immune cells. Clinicians and pathologists require this information to predict patient response to anti-PD-1/PD-L1 therapy. The adoption of this assay may represent a significant advance in the management of therapeutically challenging cancers. Further analysis and assay harmonisation are essential for translation to a routine diagnostic setting.

INTRODUCTION

Triple-negative breast cancer (TNBC) is characterised by a lack of *cerbB2*-(HER2), oestrogen and progesterone receptor expression, and has a relatively poor prognosis compared with other types of breast cancer. For this reason, novel and effective treatments are urgently required. The recent phase

III IMpassion130 trial demonstrated progression-free survival (PFS) in patients with TNBC treated with upfront atezolizumab–nab-paclitaxel treatment, compared with placebo–nab-paclitaxel treatment.¹ As a result, The United States Food and Drug Administration (FDA) granted accelerated approval for atezolizumab in combination with nab-paclitaxel in programmed death-ligand 1 (PD-L1)⁺, non-resectable TNBC.² However, the IMpassion130 trial conducted immunohistochemistry (IHC) with the SP142 PD-L1 antibody clone to identify PD-L1⁺ patients, as a companion diagnostic kit. This particular clone was found to be an outlier in previous IHC harmonisation studies performed in lung cancer,^{3–6} compared with SP263, 22C3 and other clones. Schats *et al*^{7,8} reported that the SP142 clone uniquely binds to PD-L1 isoform 2, which lacks AA 19–132. Whether breast cancer cells express this particular isoform remains unclear. However, in contrast to other clones, SP142 tends to recognise PD-L1 expression on immune cells; other clones predominantly label PD-L1 on tumour cells. Furthermore, PD-L1 expression on immune cells, not tumour cells, predicts outcome in atezolizumab-treated TNBC,¹ but accurate scoring of PD-L1 expression in immune cells remains challenging for pathologists.^{4,6,9} Previous studies have shown that pathologists are typically unable to report the immune count (IC) accurately or reproducibly, with an interclass correlation coefficient between 0.19 and 0.28.^{4,6,10}

In addition, the staining protocol for the SP142 clone differs from that used for other clones in terms of both methodology and equipment. At present, three IHC-based companion diagnostic assays have been approved for PD-L1 monoclonal antibody therapies, which use separate staining platforms and scoring systems to predict patient response to anti-PD-1/PD-L1 immunotherapy. The 22C3 clone is detected using the Dako Autostainer Link 48 platform (Dako; Agilent Technologies, Santa Clara, California, USA), whereas the SP263 and SP142 clones are detected with the Ventana BenchMark ULTRA platform (Ventana Medical Systems; Roche Diagnostics, Basel, Switzerland). However, all these



© Author(s) (or their employer(s)) 2020. No commercial re-use. See rights and permissions. Published by BMJ.

To cite: Yeong J, Tan T, Chow ZL, *et al*. *J Clin Pathol* 2020;**73**:557–562.

assays are limited by interobserver and intraobserver variability. Even relatively well-studied cancers, such as non-small-cell lung cancer (NSCLC), are subject to this limitation during diagnostics. With PD-L1 scoring of immune cells being specifically required for TNBC prognostics, this may be more challenging than in other cancers such as NSCLC and melanoma, where PD-L1 expression on tumour cells can be used instead. As reported by Cooper *et al*,¹¹ pathologists are typically consistent when scoring tumour cells with a 1% cut-off, although more training may be required for a 50% cut-off. When scoring immune cells, however, training did little to solve the discrepancy between SP142 scoring and that of other clones.^{4 6 7 10} For instance, Rimm *et al*⁴ recently conducted a reanalysis of the National Comprehensive Cancer Network PD-L1 companion diagnostic assay study for lung cancer using the same scoring method as the IMpassion130 trial, and reported that there was still poor agreement between assays and pathologists when scoring immune cell PD-L1 expression.⁷ These findings are subsequently supported by the post hoc analysis of IMpassion130 trial tissue by using PD-L1 clone 22C3 as well as SP263.¹² It is clear that novel techniques with greater accuracy and reproducibility are necessary to identify patients who might benefit from immunotherapy, especially in the context of TNBC.

Multiplex immunohistochemistry/immunofluorescence (mIHC/IF) is a relatively new technique that allows simultaneous antibody-based detection and quantification of the expression of up to six protein markers, plus a nuclear counterstain, on a single tissue section.^{13–16} In a recent study, Lu *et al*¹⁷ demonstrated that mIHC/IF seems to be associated with improved performance in predicting response to programmed cell death-ligand 1 (PD-L1)/programmed cell death receptor 1 (PD-1) treatment in different solid tumour types when compared with PD-L1 immunohistochemistry (IHC), tumour mutational burden or gene expression profiling alone. This was shown through the meta-analysis of studies involving tumour specimen assays of over 10 different solid tumour types in 8135 patients and the results were correlated with anti-PD-1/PD-L1 immunotherapy response. It is an unmet clinical need to bring such a technique forward for translation to a routine diagnostic assay for cancer immunotherapy.

This technique provides the opportunity to acquire gold-standard diagnostic and prognostic information. The use of a single section saves tissue when this is scant and allows the standardisation of multiple assays. In TNBC, which may be histologically heterogeneous, standardisation is of particular importance. mIHC/IF may also enable pathologists to refine the diagnostic criteria used in pathology and to assess the predictive value of biomarkers in specific cell types present in the tumour microenvironment. mIHC/IF has previously been used to identify quantitative and spatial immune parameters in tumours and is both reliable and reproducible when detecting tumour biomarker co-expression.^{13–16 18–23} Furthermore, Lim *et al*²⁴ have reported a fully automated staining protocol for mIHC/IF that uses a widely available and accessible clinical diagnostic autostainer, the Leica Bond Max (Leica Biosystems, Wetzlar, Germany). This discovery was of technical significance to the field, demonstrating that a routinely-used diagnostic autostainer could standardise the production of high-quality, seven-colour mIHC/IF slides that can translate to the clinical setting.

In the present study, we used an optimised automated mIHC/IF staining protocol to develop an assay that simultaneously labelled PD-L1 with three commercially available antibody clones (SP142, SP263 and 22C3), as well as epithelial cell adhesion molecule (EpCAM). The latter molecule assists in distinguishing

Table 1 Antibody details

Antibody	Clone	Source	Cat. no.
PD-L1	22C3	Dako; Agilent Technologies	SK006
PD-L1	SP142	Ventana Medical Systems; Roche Diagnostics	741–4860
PD-L1	SP263	Ventana Medical Systems; Roche Diagnostics	790–4905
EpCAM	9C2	Biolegend	324202

EpCAM, epithelial cell adhesion molecule; PD-L1, programmed death-ligand 1.

tumour cells from immune cells. This was followed by a digital pathological evaluation to report the combined positive score (CPS), tumour proportion score (TPS) and IC on a single tissue section. We analysed a total of 45 samples, and compared the automated scoring results to standard, manual PD-L1 scoring by pathologists using conventional IHC staining. We identified a moderate-to-strong correlation between the two techniques, suggesting a potential clinical application for mIHC/IF in the era of cancer immunotherapy.

MATERIALS AND METHODS

Patients and tumours

The analysis was conducted on 45 archival formalin-fixed, paraffin-embedded (FFPE) specimens from a mixed cohort encompassing 25 patients with TNBC, 12 non-small-cell lung carcinomas and other cancers such as 1 gastric adenocarcinoma, 1 oesophageal adenocarcinoma, 1 parotid adenocarcinoma, 1 colon adenocarcinoma, 3 lung small cell carcinomas and 1 urothelial carcinoma. All cases were diagnosed at the Department of Anatomical Pathology, Division of Pathology, Singapore General Hospital. The Centralised Institutional Review Board of SingHealth provided ethical approval for the use of patient materials in this study (CIRB ref: 2013/664/F, 2015/2199 and 2011/441/B).

IHC protocol

FFPE tissue sections (4 µm thick) were labelled with three different anti-PD-L1 clones (SP142, SP263 and 22C3; see [table 1](#) for details). The antibody clones were scored separately (0% to 100%), based on CPS, TPS and IC, as previously described.^{1 25–32} CPS is defined as the percentage of total PD-L1⁺ cells (tumour cells and immune cells) divided by the total number of tumour cells. TPS is defined as the percentage of tumour cells with membranous PD-L1 expression. IC is defined as the proportion of tumour area occupied by PD-L1⁺ tumour-infiltrating immune cells. Consecutive tissue sections from patients were labelled to allow the quantification of CPS, TPS and IC.

To generate the scores, images of labelled slides were captured using an IntelliSite Ultra-Fast Scanner (Philips Research, Eindhoven, the Netherlands) prior to examination by pathologists (PHT, YCT, SS and JY). All pathologists were blinded to both clinicopathological information and the PD-L1 scoring obtained using mIHC/IF. Scoring was performed independently. Where discordant, the cases were reviewed and a consensus score was given.

mIHC/IF protocol

mIHC/IF was performed using an Opal Multiplex fIHC kit (PerkinElmer Inc, Waltham, Massachusetts, USA), as previously described by our group and in other studies.^{13–16 18–23 33} Slides were labelled with three different anti-PD-L1 clones (SP142, SP263, 22C3) and EpCAM, followed by appropriate secondary antibodies (see [table 1](#) for details). Particularly for this panel,

we followed the detailed protocol that our group previously reported as protocol manuscript³³ and hereby briefly described.

FFPE tissue sections were cut onto Bond Plus slides (Leica Biosystems Richmond) and heated at 60°C for 20 min.^{19 34} Tissue slides were then subjected to deparaffinisation, rehydration and heat-induced epitope retrieval (HIER) using a Leica Bond Max autostainer (Leica Biosystems Melbourne), prior to endogenous peroxidase blocking (Leica Biosystems Newcastle). The slides were incubated with a single clone of PD-L1 or EpCAM primary antibody followed by the application of polymeric Horseradish peroxidase (HRP)-conjugated secondary antibodies (Leica Biosystems Newcastle). An appropriate Opal fluorophore-conjugated TSA (PerkinElmer, USA) was then added at 1:100 dilution. The slides were rinsed with washing buffer after each step. Following TSA deposition, the slides were again subjected to HIER to strip the tissue-bound primary/secondary antibody complexes and ready for labelling of the next marker. These steps were repeated until all four markers were labelled and finally added with spectral 4',6-diamidino-2-phenylindole (DAPI) (PerkinElmer, USA) at 1:10 dilution. The slides were mounted in ProLong Diamond Anti-fade Mountant (Molecular Probes, Life Technologies, USA) and cured in the dark at room temperature for 24 hours. Ten images (viable tumour regions were selected randomly by pathologists) were acquired for each case using a Vectra 3 pathology imaging system microscope (PerkinElmer Inc) and analysed using inForm software (V.2.4.2; PerkinElmer Inc).^{13 24 35}

As with IHC, consecutive tissue sections from tumours were labelled to allow the quantification of CPS, TPS and IC. The CPS, TPS and IC of individual slides were separately scored during mIHC/IF using the EpCAM-labelled tumour as a reference. This allowed the accurate quantitation of tumour cell counts.

Statistical analysis

Statistical analysis was performed using GraphPad Prism 8.0.0 for Windows (GraphPad Software Inc, San Diego, California, USA). Correlations between IHC and mIHC/IF scoring were analysed using Spearman's rank correlations. Krippendorff's α is a statistical measurement of agreement among observers, with the value of α ranging from 0 to 1, with 0 representing total disagreement and 1 total agreement.³⁶ Values of >0.8 indicate good reliability, whereas values in between can be interpreted tentatively, but still elicit acceptable conclusions.³⁷ A p value <0.05 was considered to indicate a statistically significant difference.

RESULTS

As shown by the representative images presented in figure 1, the mIHC/IF-based assay that used in the present study has been optimised and detailed in the Materials and Methods section such that it can simultaneously label PD-L1 with three commercially available antibody clones (SP142, SP263 and 22C3) and EpCAM, distinguishing tumour cells from immune cells, and digital pathological reporting of CPS, TPS and IC can be conducted on a single tissue section. The whole slide images of figure 1 are shown in the online supplementary figure 1. The scores between mIHC/IF and conventional IHC of this particular case are provided in the online supplementary table 1.

mIHC/IF and conventional IHC scoring for each PD-L1 clone for the mixed cohort (n=25) were compared using Spearman's rank correlations. As shown in table 2, when using a cut-off of 1% for PD-L1 positivity, SP263 CPS achieved the highest concordance rate (100%), whereas SP142 TPS achieved the highest R coefficient (0.77). In terms of concordance rate, SP263 IC was

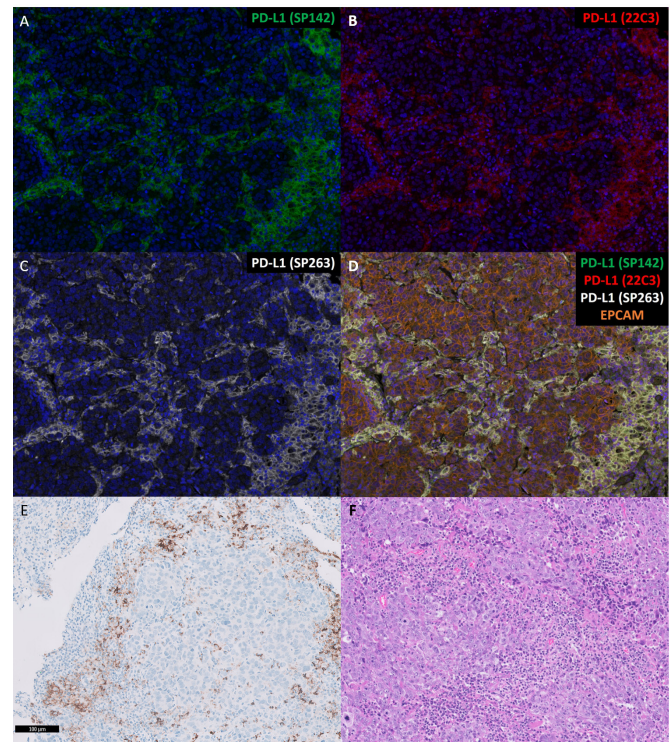


Figure 1 Representative images of TNBC tissue sections labelled with mIHC/IF. (A–D) Five-colour, multiplex immunofluorescent images of human TNBC tissue sections demonstrating the spatial distribution of different immune lineages and markers within the stroma and tumour regions. The technique labels five channels as follows: PD-L1 SP142 clone (green), PD-L1 22C3 clone (red), PD-L1 SP263 clone (white), EpCAM (orange) and DAPI (blue). (E) conventional IHC staining for the PD-L1 SP142 clone. (F) H&E staining (magnification, $\times 200$). EpCAM, epithelial cell adhesion molecule; mIHC/IF, multiplex immunohistochemistry/immunofluorescence; PD-L1, programmed death-ligand 1; TNBC, triple-negative breast cancer.

the second highest at 95%, whereas in terms of R coefficient, SP263 TPS achieved second place (0.73).

To investigate whether similar concordance rates could be achieved on pure TNBC samples, we further evaluated the comparison with a cohort (n=25) that included only TNBC cases. As shown in table 3, with a cut-off of 1% for PD-L1 positivity, SP263 CPS and SP142 IC displayed the highest concordance rates (100% and 96%, respectively). SP263 CPS showed the highest concordance in terms of R coefficient (0.88), followed by SP142 TPS, which achieved 0.78.

Finally, we used Krippendorff's α ^{36 37} to investigate the concordance among the three PD-L1 antibody clones. As shown in table 4, regardless of whether IHC or mIHC/IF was used, the Krippendorff's α value ranged from 0.527 to 0.695. This suggested a moderate reliability. The highest reliability was achieved on TPS IHC score when the 1% cut-off was applied (among 3 PD-L1 clones) followed by CPS IHC score with 1% cut-off (among 3 PD-L1 clones). For mIHC/IF, CPS achieved the highest Krippendorff's α (0.551) followed by IC (Krippendorff's $\alpha=0.546$).

DISCUSSION

In light of the recent IMpassion130 TNBC trial, which demonstrated significantly improved outcomes in patients with TNBC treated with atezolizumab, and the resultant FDA approval of

Table 2 Correlations between programmed death-ligand 1 scoring generated by mIHC/IF and conventional IHC in a cohort comprised TNBC, NSCLC, gastric cancer, oesophageal cancer, parotid and colonic adenocarcinomas, and urothelial carcinoma

Statistic	SP142 CPS	SP142 TPS	SP142 IC	22C3 CPS	22C3 TPS	22C3 IC	SP263 CPS	SP263 TPS	SP263 IC
Concordance rate	84.5%	69%	89%	70%	67%	70%	100%	80%	95%
R (Spearman)	0.61	0.77	0.41	0.50	0.56	0.46	0.60	0.73	0.60
P value (Spearman)	0.003	0.0002	0.009	0.030	0.008	0.040	0.007	0.0002	0.006

Data were analysed using Spearman's rank correlations (n=25).

CPS, combined positive score; IC, immune count; mIHC/IF, multiplex immunohistochemistry/immunofluorescence; NSCLC, non-small-cell lung carcinoma; TNBC, triple-negative breast cancer; TPS, tumour proportion score.

this treatment for non-resectable, advanced PD-L1⁺ TNBC, we developed a mIHC/IF-based assay to simultaneously evaluate the efficacy of 3 PD-L1 antibody clones in TNBC. We demonstrated good concordance with the results of manual scoring performed by pathologists following conventional IHC.

Previous studies have demonstrated that commercially available PD-L1 clones have different concordance rates in different tumour types. For example, Rimm *et al*⁴ reported that SP142 identified only 50% of patients with TNBC identified by 28-8, 22C3 and E1L3N. This lower rate of detection by SP142 was consistent with that in other studies involving NSCLC.^{3-6 38-40} Moreover, SP142 detected fewer PD-L1⁺ immune cells compared with 28-8 and E1L3N, which was consistent with the results of the Blueprint studies.^{3 4 6} A recent multicentre study evaluated 22C3, 28-8 and SP263 in NSCLC and found that these clones may be interchangeable when scoring tumour cells, but not immune cells; again in concordance with the results of the Blueprint studies among others.^{3 6 10 41} However, in melanoma, Schats *et al*¹³ demonstrated that SP142 successfully labelled PD-L1⁺ immune cells.³⁹ It is clear that these discrepancies warrant further investigation, particularly in more heterogeneous cancers such as TNBC.

Sun *et al*²⁷ previously evaluated PD-L1 detection in TNBC using the E1L3N, 28-8 and SP142 antibody clones and found that SP142 detected fewer tumour and immune cells and had a relatively low concordance rate with the other clones.²⁶ Another study conducted by Karnik *et al*¹⁴ revealed that the performance of the SP263, 22C3 and RbM CAL10 clones was comparable, but SP142 was not studied. This apparent discordance across PD-L1 clones may lead to potential missed opportunities for patients to receive appropriate anti-PD-1/PD-L1 therapy. For instance, one TNBC case that scored 0% for clone 22C3 could have received a score of 10% with SP142, suggesting that this patient might benefit from atezolizumab treatment.

Further complicating the situation in TNBC is the fact that PD-L1⁺ immune cells rather than tumour cells are of predictive value.¹² This is of particular relevance for atezolizumab therapy, as this targets PD-L1 also. Unfortunately, PD-L1 scoring on immune cells is often subject to significant interobserver variation, even more so than scoring on tumour cells.^{4 6 7 9 10} The recent report by Rimm *et al*⁹ highlighted this issue along with the low sensitivity of SP142 clone, raising significant concern for pathologists aiming to provide accurate and reproducible companion

diagnostic results for PD-L1 in TNBC.⁷ The study suggested re-evaluating the IMpassion 130 tissues with multiple assays, especially for the SP263 assay, which is produced by the same vendor as the SP142 assay. Subsequently, Rugo *et al* reported a post hoc analysis of the IMpassion130 tissues with PD-L1 clone 22C3 and SP263 to compare with the clone SP142.¹² The study not only suggested that there are differences between the assays chosen to assess PD-L1 status, but also demonstrated that double-positive assay results (SP142+/22C3+ or SP142+/SP263+) were associated with superior PFS and overall survival compared with single-positive or double-negative results.¹² These further support our initiative to make full use of the limited tissue to better understand the PD-L1 scoring from each PD-L1 assay and the potential of clinical benefit.

Thus, we embarked on the present study, which used mIHC/IF as an objective, standardised staining and analytic pipeline to overcome interobserver variability. Reproducibility of such a technique has been reported by our group and others for various markers including PD-L1.^{25 42-44} This approach may also be applicable in other types of cancer treated with immunotherapy that also require PD-L1 scoring on immune cells specifically, such as urothelial carcinoma⁴⁵ and gastric cancer.⁴⁶ Herbst *et al*⁴² previously identified an array of tumour types in which PD-L1⁺ immune cells are of predictive value to anti-PD-L1 therapy, including renal cell carcinoma, colorectal cancer, non-small cell carcinoma, head and neck squamous cell carcinoma, gastric cancer, pancreatic cancer and melanoma. This suggests that this mIHC/IF-based PD-L1 scoring technique could have applications far beyond TNBC alone.

To the best of our knowledge, the present study is the first to provide evidence suggesting that mIHC/IF results are concordant to those obtained through traditional IHC methods, supporting the imminent translation of mIHC/IF to clinical practice. mIHC/IF is not subject to the same observer variability as manual scoring methods and is highly reproducible. mIHC/IF with EpCAM as a tumour marker allowed accurate differentiation and quantitation of immune cells from tumour cells while labelling PD-L1. Another benefit of mIHC/IF is that it can conserve patient tissue: these are often scant in diagnostics, especially when obtained through needle biopsy methods. mIHC/IF permits a single section to be stained simultaneously with multiple anti-PD-L1 clones, both saving tissue with comparable turnaround time and cost to conventional IHC on multiple sections.

Table 3 Correlations between programmed death-ligand 1 scoring generated by mIHC/IF and conventional IHC in triple-negative breast cancer

Statistic	SP142 CPS	SP142 TPS	SP142 IC	22C3 CPS	22C3 TPS	22C3 IC	SP263 CPS	SP263 TPS	SP263 IC
Concordance rate	92.0%	72%	96%	70%	68%	70%	100%	88%	95%
R (Spearman)	0.76	0.78	0.58	0.50	0.58	0.46	0.60	0.88	0.60
P value (Spearman)	<0.0001	<0.0001	0.001	0.030	0.0013	0.040	0.007	<0.0001	0.006

Data were analysed using Spearman's rank correlations (n=25).

CPS, combined positive score; TPS, tumour proportion score; IC, immune count; mIHC/IF, multiplex immunohistochemistry/immunofluorescence.

Table 4 Concordance of the 3 PD-L1 antibody clones by using IHC and mIHC/IF respectively

	CPS IHC	CPS mIHC/IF	TPS IHC	TPS mIHC/IF	IC IHC	IC mIHC/IF
Krippendorff's alpha (with 1% cut-off)	0.542	0.551	0.695	0.527	0.634	0.546

Data were analysed using Krippendorff's α ($n=45$).

CPS, combined positive score; TPS, tumour proportion score; IC, immune count; mIHC/IF, multiplex immunohistochemistry/immunofluorescence; IHC, immunohistochemistry.

Furthermore, in certain cancers such as TNBC, PD-L1 testing in non-immunotherapeutic or standard-of-care settings might have additional prognostic value. High PD-L1 expression in breast cancer is generally associated with a relatively poor prognosis, based on the results of previous meta-analyses.^{47,48} However, in the context of TNBC specifically, high PD-L1 expression may indicate a relatively good prognosis.^{25,49–52} Immune cell PD-L1 expression has also been found to have clinical value when evaluating breast cancers, suggesting that the assessment of both tumour and ICs is warranted in clinical practice.⁵³ Additional investigation is clearly warranted to fully elucidate the prognostic role of PD-L1 expression in TNBC.

One limitation of this study is that the mIHC/IF method described in this study captures regions of interest in the entire section of tissue, whereas conventional IHC and manual scoring in contrast is scored in the entire stained tissue section. As part of the clinical validation and future work, we are testing the evaluation of mIHC/IF whole slide images instead of the region of interest in which the technical portion (as research setting) is working (online supplementary figure 1). The key hurdles of implementing that as a clinical/translational platform would be the speed of analysis, turnaround time, computing power, server and storage which could pose a challenge for most clinical pathology laboratories. Last but not least, mIHC/IF remains technically an IHC-based platform that can be easily adopted into clinical diagnostic settings; the system does provide pseudo-IHC images in parallel to the fluorescent images which might help pathologists to better appreciate the images (online supplementary figure 2).

In conclusion, further analysis and harmonisation of assays are required to establish mIHC/IF PD-L1 testing as a complementary diagnostic method in TNBC or other cancers. Nevertheless, the capacity for simultaneous detection and quantitation of multiple PD-L1 clones in both the tumour and immune cell compartments is highly promising. This new tool warrants more standardised clinical validation on larger cohorts prior to widespread adoption in clinical practice. Once established, however,

the information provided by mIHC/IF will be invaluable when stratifying patients who may benefit from anti-PD-1/PD-L1 immunotherapy.

Author affiliations

- ¹Division of Pathology, Singapore General Hospital, Singapore, Singapore
- ²Integrative Biology for Therapeutics, Institute of Molecular Cell Biology, Agency of Science, Technology and Research (A*STAR), Singapore, Singapore
- ³Singapore Immunology Network (SigN), Agency of Science, Technology and Research (A*STAR), Singapore, Singapore
- ⁴Division of Medical Oncology, National Cancer Centre Singapore, Singapore, Singapore
- ⁵University of Tasmania, Hobart, Tasmania, Australia
- ⁶Duke-NUS Medical School, Duke-NUS Medical School, Singapore, Singapore
- ⁷Department of Anatomical Pathology, Singapore General Hospital, Singapore, Singapore
- ⁸Diagnostics Development (DxD) Hub, Agency of Science, Technology and Research (A*STAR), Singapore, Singapore

Handling editor Check Soon Lee.

Contributors PHT and JY: designed and directed the study; drafted the manuscript, which was commented on and revised by all authors. JY, TT and ZLC: coordinated the study. JCTL, JL, AAT and CO: acquired the data. JY, SS, YCT and PHT: did conventional IHC and manual scoring. CQ, BL and JL: did analysis. JJ, YCP and SY: provided advice from technical perspectives. TT, AS, EL and RD: provided advice from clinical perspectives.

Funding This study was funded by the A*STAR Biomedical Research Council, National Medical Research Council Stratified Medicine Programme Office (grant no. SMPO201302), awarded to Dr PHTn. Dr JJ is a recipient of the Transition Award from the Singapore National Medical Research Council (grant no. NMRC/TA/0041/2015).

Competing interests ZLC is a medical student from the University of Tasmania on a research elective posting with the Department of Anatomical Pathology Singapore General Hospital, supported by the Royal College of Pathologists of Australasia (RCPA) medical students' scholarship. BL is part of the SigN Immunomonitoring platform (supported by a BMRC IAF 311006 grant and BMRC transition funds #H16/99/b0/011).

Patient consent for publication Not required.

Ethics approval The Centralised Institutional Review Board of Singhealth provided ethical approval for the use of patient materials in the present study (CIRB ref: 2013/664/F, 2015/2199 and 2011/441/B).

Provenance and peer review Not commissioned; externally peer reviewed.

Data availability statement Data are available upon reasonable request. Data will be made available upon reasonable request to correspondent authors, JY and PHT.

ORCID iD

Joe Yeong <http://orcid.org/0000-0002-6674-7153>

REFERENCES

- Schmid P, Adams S, Rugo HS, *et al.* Atezolizumab and Nab-paclitaxel in advanced triple-negative breast cancer. *N Engl J Med* 2018;379:2108–21.
- Administration USFaD. FDA approves atezolizumab for PD-L1 positive unresectable locally advanced or metastatic triple-negative breast cancer, 2019. Available: <https://www.fda.gov>
- Hirsch FR, McElhinny A, Stanforth D, *et al.* Pd-L1 immunohistochemistry assays for lung cancer: results from phase 1 of the blueprint PD-L1 IHC assay comparison project. *J Thorac Oncol* 2017;12:208–22.
- Rimm DL, Han G, Taube JM, *et al.* A prospective, multi-institutional, Pathologist-Based assessment of 4 immunohistochemistry assays for PD-L1 expression in non-small cell lung cancer. *JAMA Oncol* 2017;3:1051–8.
- Xu H, Lin G, Huang C, *et al.* Assessment of concordance between 22C3 and SP142 immunohistochemistry assays regarding PD-L1 expression in non-small cell lung cancer. *Sci Rep* 2017;7:16956.

Take home messages

- To the best of our knowledge, this is the first study to report on an optimised multiplex immunohistochemistry/immunofluorescence (mIHC/IF) assay that combines multiple different programmed death-ligand 1 (PD-L1) antibody clones applied to a single tissue section.
- mIHC/IF-based assay results are concordant to those obtained through traditional IHC methods, and this suggests the potential for translation of mIHC/IF to clinical practice.
- To our knowledge, this is also the first study on triple-negative breast cancer showing moderate-to-strong correlations using multiple PD-L1 antibody clones including SP142, SP263 and 22C3, conducted after the Food and Drug Administration approval of atezolizumab for PD-L1⁺, non-resectable TNBC.

- 6 Tsao MS, Kerr KM, Kockx M, *et al.* Pd-L1 immunohistochemistry comparability study in real-life clinical samples: results of blueprint phase 2 project. *J Thorac Oncol* 2018;13:1302–11.
- 7 Rimm DL, Han G, Taube JM, *et al.* Reanalysis of the NCCN PD-L1 companion diagnostic assay study for lung cancer in the context of PD-L1 expression findings in triple-negative breast cancer. *Breast Cancer Res* 2019;21:72.
- 8 Schats K, Van Vre EA, Schrijvers D, *et al.* Epitope mapping of PD-L1 primary antibodies (28-8, SP142, SP263, E1L3N). *Journal of Clinical Oncology* 2017;35:3028.
- 9 Ma J, Li J, Qian M, *et al.* Pd-L1 expression and the prognostic significance in gastric cancer: a retrospective comparison of three PD-L1 antibody clones (SP142, 28-8 and E1L3N). *Diagn Pathol* 2018;13:91.
- 10 Hendry S, Byrne DJ, Wright GM, *et al.* Comparison of four PD-L1 immunohistochemical assays in lung cancer. *J Thorac Oncol* 2018;13:367–76.
- 11 Cooper WA, Russell PA, Cherian M, *et al.* Intra- and interobserver reproducibility assessment of PD-L1 biomarker in Non-Small cell lung cancer. *Clin Cancer Res* 2017;23:4569–77.
- 12 Rugo SL HS, Adams S, Schmid P, *et al.* Performance of PD-L1 immunohistochemistry (IHC) assays in unresectable locally advanced or metastatic triple-negative breast cancer (mTNBC): Post-h. *Annals of Oncology* 2019;30:v851–934.
- 13 Abel EJ, Bauman TM, Weiker M, *et al.* Analysis and validation of tissue biomarkers for renal cell carcinoma using automated high-throughput evaluation of protein expression. *Hum Pathol* 2014;45:1092–9.
- 14 Feng Z, Jensen SM, Messenheimer DJ, *et al.* Multispectral imaging of T and B cells in murine spleen and tumor. *J Immunol* 2016;196:3943–50.
- 15 Lovisa S, LeBleu VS, Tampe B, *et al.* Epithelial-to-mesenchymal transition induces cell cycle arrest and parenchymal damage in renal fibrosis. *Nat Med* 2015;21:998–1009.
- 16 Stack EC, Wang C, Roman KA, *et al.* Multiplexed immunohistochemistry, imaging, and quantitation: a review, with an assessment of Tyramide signal amplification, multispectral imaging and multiplex analysis. *Methods* 2014;70:46–58.
- 17 Lu S, Stein JE, Rimm DL, *et al.* Comparison of biomarker modalities for predicting response to PD-1/PD-L1 checkpoint blockade: a systematic review and meta-analysis. *JAMA Oncol* 2019. [Epub ahead of print: 18 Jul 2019].
- 18 Garnelo M, Tan A, Her Z, *et al.* Interaction between tumour-infiltrating B cells and T cells controls the progression of hepatocellular carcinoma. *Gut* 2017;66:342–51.
- 19 Yeong J, Thihe AA, Lim JCT, *et al.* Higher densities of Foxp3+ regulatory T cells are associated with better prognosis in triple-negative breast cancer. *Breast Cancer Res Treat* 2017;163:21–35.
- 20 Lim JCT, Yeong JPS, Lim CJ, *et al.* An automated staining protocol for seven-colour immunofluorescence of human tissue sections for diagnostic and prognostic use. *Pathology* 2018;50:333–50.
- 21 Esbona K, Inman D, Saha S, *et al.* COX-2 modulates mammary tumor progression in response to collagen density. *Breast Cancer Research* 2016;18:35.
- 22 Mlecnik B, Bindea G, Kirilovsky A, *et al.* The tumor microenvironment and immunoscore are critical determinants of dissemination to distant metastasis. *Sci Transl Med* 2016;8:327ra26.
- 23 Nghiem PT, Bhatia S, Lipson EJ, *et al.* PD-1 blockade with pembrolizumab in advanced Merkel-cell carcinoma. *N Engl J Med* 2016;374:2542–52.
- 24 Feng Z, Bethmann D, Kappler M, *et al.* Multiparametric immune profiling in HPV– oral squamous cell cancer. *JCI Insight* 2017;2.
- 25 Yeong J, Lim JCT, Lee B, *et al.* Prognostic value of CD8+PD-1+ immune infiltrates and PDCD1 gene expression in triple negative breast cancer. *J Immunother Cancer* 2019;7:34.
- 26 Sun WY, Lee YK, Koo JS. Expression of PD-L1 in triple-negative breast cancer based on different immunohistochemical antibodies. *J Transl Med* 2016;14:173.
- 27 Karnik T, Kimler BF, Fan F, *et al.* Pd-L1 in breast cancer: comparative analysis of 3 different antibodies. *Hum Pathol* 2018;72:28–34.
- 28 Adams S, Schmid P, Rugo HS, *et al.* Pembrolizumab monotherapy for previously treated metastatic triple-negative breast cancer: cohort a of the phase II KEYNOTE-086 study. *Ann Oncol* 2019;30:397–404.
- 29 Barrett MT, Lenkiewicz E, Malasi S, *et al.* The association of genomic lesions and PD-1/PD-L1 expression in resected triple-negative breast cancers. *Breast Cancer Res* 2018;20:71.
- 30 Schmid P, Cortes J, Bergh JCS, *et al.* KEYNOTE-522: phase III study of pembrolizumab (pembro) + chemotherapy (chemo) vs placebo + chemo as neoadjuvant therapy followed by pembro vs placebo as adjuvant therapy for triple-negative breast cancer (TNBC). *J Clin Oncol* 2018;36:TPS602–TPS.
- 31 Emens LA, Cruz C, Eder JP, *et al.* Long-Term clinical outcomes and biomarker analyses of Atezolizumab therapy for patients with metastatic triple-negative breast cancer: a phase 1 StudyAtezolizumab therapy for patients with metastatic triple-negative breast cancerAtezolizumab therapy for patients with metastatic triple-negative breast cancer. *JAMA oncology* 2019;5:74–82.
- 32 Vennapusa B, Baker B, Kowanetz M, *et al.* Development of a PD-L1 complementary diagnostic immunohistochemistry assay (SP142) for Atezolizumab. *Appl Immunohistochem Mol Morphol* 2019;27:92–100.
- 33 Lim JCT, Yeong JPS, Lim CJ, *et al.* An automated staining protocol for seven-colour immunofluorescence of human tissue sections for diagnostic and prognostic use. *Pathology* 2018;50:333–41.
- 34 Yeong J, Lim JCT, Lee B, *et al.* High densities of tumor-associated plasma cells predict improved prognosis in triple negative breast cancer. *Front Immunol* 2018;9:1209.
- 35 Fiore C, Bailey D, Conlon N, *et al.* Utility of multispectral imaging in automated quantitative scoring of immunohistochemistry. *J Clin Pathol* 2012;65:496–502.
- 36 Krippendorff K. *Computing Krippendorff's Alpha-Reliability*, 2011.
- 37 Krippendorff K. Content analysis. *International encyclopedia of communication* 1989;1:403–7.
- 38 Kim H, Kwon HJ, Park SY, *et al.* PD-L1 immunohistochemical assays for assessment of therapeutic strategies involving immune checkpoint inhibitors in non-small cell lung cancer: a comparative study. *Oncotarget* 2017;8:98524–32.
- 39 Schats KA, Van Vre EA, Boeckx C, *et al.* Optimal evaluation of programmed death ligand-1 on tumor cells versus immune cells requires different detection methods. *Arch Pathol Lab Med* 2018;142:982–91.
- 40 Scheel AH, Dietel M, Heukamp LC, *et al.* Harmonized PD-L1 immunohistochemistry for pulmonary squamous-cell and adenocarcinomas. *Mod Pathol* 2016;29:1165–72.
- 41 Adam J, Le Stang N, Rouquette I, *et al.* Multicenter harmonization study for PD-L1 IHC testing in non-small-cell lung cancer. *Ann Oncol* 2018;29:953–8.
- 42 Hoyt C, Roman K, Engle L, *et al.* Abstract LB-318: multi-institutional TSA-amplified multiplexed immunofluorescence reproducibility evaluation (MITRE study): reproducibility assessment of an automated multiplexed immunofluorescence slide staining, imaging, and analysis workflow. *Cancer Research* 2019;79:LB-318.
- 43 Wong PF, Wei W, Gupta S, *et al.* Multiplex quantitative analysis of cancer-associated fibroblasts and immunotherapy outcome in metastatic melanoma. *J Immunother Cancer* 2019;7:194.
- 44 Martinez-Morilla S, McGuire J, Gaule P, *et al.* Quantitative assessment of PD-L1 as an analyte in immunohistochemistry diagnostic assays using a standardized cell line tissue microarray. *Lab Invest* 2020;100:4-15.
- 45 Powles T, Durán I, van der Heijden MS, *et al.* Atezolizumab versus chemotherapy in patients with platinum-treated locally advanced or metastatic urothelial carcinoma (IMvigor211): a multicentre, open-label, phase 3 randomised controlled trial. *The Lancet* 2018;391:748–57.
- 46 Kulangara K, Zhang N, Corigliano E, *et al.* Clinical utility of the combined positive score for programmed death ligand-1 expression and the approval of pembrolizumab for treatment of gastric cancer. *Arch Pathol Lab Med* 2019;143:330–7.
- 47 Zhang M, Sun H, Zhao S, *et al.* Expression of PD-L1 and prognosis in breast cancer: a meta-analysis. *Oncotarget* 2017;8:31347–54.
- 48 Wang C, Zhu H, Zhou Y, *et al.* Prognostic value of PD-L1 in breast cancer: a meta-analysis. *Breast J* 2017;23:436–43.
- 49 Botti G, Collina F, Scognamiglio G, *et al.* Programmed death ligand 1 (PD-L1) tumor expression is associated with a better prognosis and diabetic disease in triple negative breast cancer patients. *Int J Mol Sci* 2017;18:459.
- 50 Li X, Wetherilt CS, Krishnamurti U, *et al.* Stromal PD-L1 expression is associated with better disease-free survival in triple-negative breast cancer. *Am J Clin Pathol* 2016;146:496–502.
- 51 Guo L, Li W, Zhu X, *et al.* Pd-L1 expression and CD274 gene alteration in triple-negative breast cancer: implication for prognostic biomarker. *Springerplus* 2016;5.
- 52 Mori H, Kubo M, Yamaguchi R, *et al.* The combination of PD-L1 expression and decreased tumor-infiltrating lymphocytes is associated with a poor prognosis in triple-negative breast cancer. *Oncotarget* 2017;8.
- 53 Kim HM, Lee J, Koo JS. Clinicopathological and prognostic significance of programmed death ligand-1 expression in breast cancer: a meta-analysis. *BMC Cancer* 2017;17:690.