

safety of TACE combined with microwave ablation (MWA) versus TACE combined with cryoablation (CRA) in treating unresectable HCC.

Methods From January 2011 to December 2018, 108 patients diagnosed with unresectable HCC were divided into either the TACE-MWA group (n = 48) or TACE-CRA group (n = 60). Overall survival (OS) and time to progression (TTP) were compared between the two groups. Complications were observed. Kaplan-Meier survival curves were constructed and compared using the log-rank test.

Results Baseline characteristics of the two groups were basically balanced. The median OS was 20.9 months (95% CI 14.3–27.6 months) in the TACE-MWA group and 13.0 months (95% CI 8.8–17.1 months) in the TACE-CRA group (P=.096). The median TTP was 8.8 months (95% CI 4.3–13.4 months) in the TACE-MWA group and 9.3 months (95% CI 7.1–11.5 months) in the TACE-CRA group (P=.675) (figure 1). The overall incidence rate of ablation-related complications was lower in the TACE-MWA group than in the TACE-CRA group (66.7% vs. 88.3%, P =.006). Multivariate analysis showed that the presence of portal vein tumor thrombus (PVTT) and the maximum diameter of the intrahepatic tumor were significant prognostic factors for OS and TTP.

Conclusions The efficacy of TACE-MWA and TACE-CRA in the treatment of unresectable HCC was comparable. TACE-MWA was more promising because of a lower complication rate, especially with regard to thrombocytopenia. Further prospective randomized controlled trials are required to validate our findings.

IDDF2020-ABS-0064

THREE-DAY POSTOPERATIVE ANTIMICROBIAL PROPHYLAXIS CAN REDUCE THE INCIDENCE OF POSTOPERATIVE INFECTION IN PRIMARY HEPATOCELLULAR CARCINOMA: A MULTICENTER RETROSPECTIVE STUDY

¹Zebin Chen*, ¹Yuanqi Wang, ²Ruiming Liang, ³Jiaming Lai, ¹Dongming Li, ¹Shaoqiang Li, ¹Kai Lei, ²Qian Zhou, ¹Baogang Peng. ¹Department of Liver Surgery, the First Affiliated Hospital, Sun Yat-sen University, China; ²Clinical Trials Unit, the First Affiliated Hospital, Sun Yat-sen University, China; ³Department of Pancreato-biliary Surgery, the First Affiliated Hospital, Sun Yat-sen University, China

10.1136/gutjnl-2020-IDDF.147

Background Postoperative infection in primary hepatocellular carcinoma (HCC) may cause bad consequences, even affect overall survival. But the evidence of using postoperative antimicrobial prophylaxis (AMP) in HCC was not sufficient enough. We aimed to explore the relationship between postoperative AMP and infection after hepatectomy.

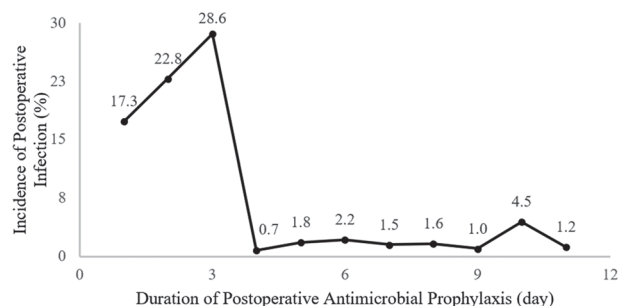
Methods We retrospectively collected 1648 HCC patients who underwent hepatectomy from three tertiary hospitals. The incidences of postoperative infection, including surgical site infection (SSI) and remote site infection (RI) were recorded and calculated. Univariable and multivariable Cox regression analyses were performed to explore risk factors of postoperative infection. Inverse probability of treatment weighting (IPTW) analysis was also performed to reduce the selection bias.

Results The overall infection rate was 9.7% (160/1648), including 8.1% of SSI and 2.3% of RI. Multivariable analysis revealed that the duration of postoperative AMP was negatively related to the incidence of postoperative infection significantly (OR 1.39, 95 per cent c.i. 1.28 to 1.52; P < 0.01).

And 3-day regimen seemed to be the shortest duration of postoperative AMP to gain the lowest incidence of postoperative infection. In the subgroup analysis between patients received 0-day and 3-day postoperative AMP, using postoperative AMP for 3 days was an independent protective factor of infection (OR 0.04, 95 per cent c.i. 0.01 to 0.29; P < 0.01). IPTW analysis showed consistent results with those of previous analysis (P=0.01).

Conclusions Postoperative AMP is necessary for HCC patients to prevent postoperative infection. Using antibiotics based on the experience of surgeons for 3 days after surgery might be proper.

(Figure 1)



Abstract IDDF2020-ABS-0064 Figure 1 Duration of postoperative antimicrobial prophylaxis (day)

IDDF2020-ABS-0065

SAFETY AND EFFICACY OF LAPAROSCOPIC MICROWAVE ABLATION AND PORTAL VEIN LIGATION FOR STAGED HEPATECTOMY (LAPS) IN PATIENTS WITH HBV-RELATED HEPATOCELLULAR CARCINOMA

¹Kai Lei*, ¹Zebin Chen, ²Shuling Chen, ³Ruiming Liang, ³Zhenwei Peng, ³Sui Peng. ¹Department of Liver Surgery, The First Affiliated Hospital of Sun Yat-sen University, China; ²Division of Interventional Ultrasound, The First Affiliated Hospital of Sun Yat-sen University, China; ³Clinical Trials Unit, The First Affiliated Hospital of Sun Yat-sen University, China

10.1136/gutjnl-2020-IDDF.148

Background Associating liver partition and portal vein ligation for staged hepatectomy (ALPPS) has high morbidity and mortality. In this study, the safety and efficacy of a modification of ALPPS (laparoscopic microwave ablation and portal vein ligation for staged hepatectomy, LAPS) were compared with the classic ALPPS in patients with HBV-related hepatocellular carcinoma (HCC).

Methods Patients who were diagnosed with HCC and were considered to have insufficient future liver remnant (FLR) were enrolled. In stage I, a microwave ablation (MWA) device was used to cauterise along the planned transection plane to form a coagulum avascular area. When the FLR reached above 40%, hepatectomy was performed in stage II along the coagulum area established previously. After two stages, operative morbidity, mortality, increase in FLR, operative time and blood loss were evaluated.

Results Between April 2013 and September 2019, 7 patients with HBV-related HCC were treated with the LAPS procedure, and 14 patients were treated with the ALPPS procedure. No major complications (Clavien-Dindo IIIa) occurred after 1 stages of the LAPS group, while the ALPPS group were 21.4% (3/14). Completion rate of secondary surgery of the