

# Initial High-Dose Prophylaxis and Extended Taper for Mushroom Keratoplasty in Vascularized Herpetic Scars



ANGELI CHRISTY YU, ASAF FRIEHMANN, JAMES MYERSCOUGH, SERGIU SOCEA, LUCA FURIOSI, GUISEPPE GIANNACCARE, CRISTINA BOVONE, AND MASSIMO BUSIN

- **PURPOSE:** To report the outcomes of initial high-dose and extended taper of antiviral and steroid prophylaxis for the treatment of eyes with high-risk vascularized herpetic corneal scars that underwent 2-piece mushroom keratoplasty (MK).
- **DESIGN:** Prospective interventional case series.
- **METHODS:** In this single-center study, 52 consecutive eyes with vascularized ( $\geq 2$  quadrants) herpetic corneal scars underwent 2-piece microkeratome-assisted MK. Initial high-dose and extended taper of combined oral and topical antiviral and steroid prophylaxis was administered. Outcome measures were best spectacle-corrected visual acuity (BSCVA), refractive astigmatism (RA), endothelial cell density, immunologic rejection, herpetic recurrence, and graft failure rates.
- **RESULTS:** Excluding patients with vision-impairing comorbidities, baseline BSCVA ( $1.73 \pm 0.67$  logMAR) significantly improved annually during the first 2 years ( $P < .001$ ,  $P = .016$ ), reaching  $0.17 \pm 0.18$  logMAR at year 2, and remaining stable up to 10 years ( $P = .662$ ). At 2 years, 86% of eyes saw  $\geq 20/40$ , 55% saw  $\geq 20/25$ , and 18% saw  $\geq 20/20$  Snellen BSCVA. RA exceeded 4.5 diopters in 7% of cases after wound revision for high-degree astigmatism in 7 cases. Endothelial cell loss was 40.9% at 1 year with an annual decline of 3.1% over 10 years. The 10-year cumulative risk for immunologic rejection, herpetic recurrence, and graft failure was 9.7%, 7.8%, and 7.6%, respectively.
- **CONCLUSIONS:** Initial high dose and extended taper of antiviral and steroid prophylaxis for MK in high-risk, vascularized herpetic corneal scars achieves clinical out-

comes that remain stable for up to 10 years after surgery with minimal risk of immunologic rejection, herpetic recurrence and graft failure. (*Am J Ophthalmol* 2020;217:212–223. © 2020 Elsevier Inc. All rights reserved.)

**A**DVANCED HERPETIC CORNEAL INFECTIONS WITH deep stromal scarring and corneal vascularization cause significant visual morbidity and pose significant management challenges. Although penetrating keratoplasty (PK) can be performed for visual rehabilitation of these eyes, it often provides suboptimal results, including poor visual outcomes and limited graft survival.<sup>1–3</sup> Immunologic rejection in the setting of extensive vascularization and herpetic recurrence are the main reasons for the increased incidence of failure after PK.<sup>2,3</sup>

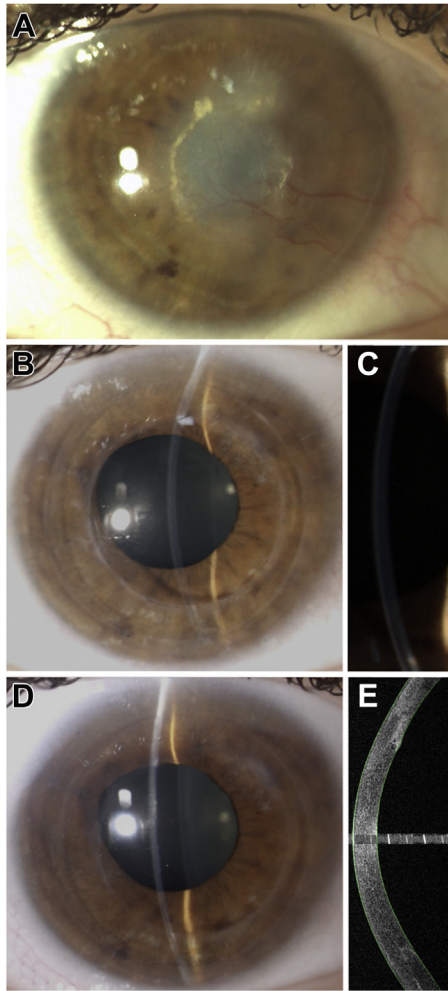
Since immune reactivity and the tendency toward graft rejection is highest soon after corneal transplantation, systemic steroids have been combined with topical therapy for the prophylaxis of immunologic rejection.<sup>4,5</sup> In addition, antiviral prophylaxis has shown a significant reduction in the incidence of herpetic recurrence.<sup>1,6</sup> Prolonged antiviral prophylaxis theoretically addresses the indefinite potential for recurrence, even years after corneal transplantation.

To eliminate the risk of endothelial immunologic rejection, deep anterior lamellar keratoplasty (DALK) has been used as an alternative to PK.<sup>7</sup> However, the success of pneumatic dissection is significantly lower in corneal scars with deep stromal involvement. Extensive scarring often results in higher rates of intraoperative Descemet's membrane perforation requiring conversion to PK in a significant number of cases.<sup>8</sup> In order to obtain the refractive advantage of large-diameter DALK,<sup>9</sup> yet allow limited removal of the central recipient endothelium, we have introduced 2-piece microkeratome-assisted mushroom keratoplasty (MK) into our routine clinical practice. In a previous study, the use of this technique in vascularized corneas has resulted in greater than 90% rate of 3-year graft survival with excellent visual outcomes.<sup>10</sup> In this ongoing prospective study, we investigated the outcomes of initial high-dose and extended taper of antiviral and steroid prophylaxis for the treatment of eyes with vascularized herpetic scars that underwent 2-piece microkeratome-assisted MK.

Accepted for publication Apr 16, 2020.

From the Department of Morphology, Surgery and Experimental Medicine, University of Ferrara, Ferrara, Italy (A.C.Y., L.F., C.B., M.B.); Department of Ophthalmology, Ospedali Privati Forlì "Villa Igea", Forlì, Italy (A.C.Y., A.F., J.M., S.S., L.F., C.B., M.B.); Istituto Internazionale per la Ricerca e Formazione in Oftalmologia, Forlì, Italy (A.C.Y., A.F., J.M., S.S., L.F., C.B., M.B.); Department of Ophthalmology, Meir Medical Center, Kfar Saba, Israel (A.F.); Sackler Faculty of Medicine, Tel Aviv University, Tel Aviv, Israel (A.F.); Department of Ophthalmology, Southend University Hospital, Southend, UK (J.M.); Department of Ophthalmology, Rambam Health Care Campus, Haifa, Israel (S.S.); Department of Ophthalmology, University of Magna Graecia, Catanzaro, Italy (G.G.).

Inquiries to Massimo Busin, Department of Ophthalmology, Ospedali Privati Forlì "Villa Igea", 47122 Forlì, Italy; e-mail: [mbusin@yahoo.com](mailto:mbusin@yahoo.com)



**FIGURE 1.** Preoperative clinical picture of a central herpetic corneal scar with vascularization in the supero- and inferotemporal quadrants. (A) Two years postoperatively the corneal graft is perfectly clear and well-adapted (B), the interface is barely detectable at the slit-lamp (C), and compatible with excellent vision (Snellen visual acuity 20/20). Ten years postoperatively, the graft is equally clear (D) and the anterior segment optical coherence tomography does not show any interface line (E).

## METHODS

THIS IS AN INTERVENTIONAL CASE SERIES CONDUCTED AT A single tertiary care referral center (Ospedali Privati Forlì, Forlì, Italy), evaluating 52 consecutive eyes with vascularized herpetic corneal scars that underwent MK between January 2005 and September 2014. Results of the initial 8 grafts included in this study have been reported previously.<sup>10</sup> This study was compliant with the tenets of the Declaration of Helsinki and prospectively approved by the Institutional Review Board/Ethics Committee of Ospedali Privati Forlì, Forlì, Italy. Written informed consent for the surgery and research was obtained from all participants.

- **INCLUSION CRITERIA:** Herpetic corneal scars were clinically diagnosed and classified as high risk (Figure 1), consistent with the criteria from the Collaborative Corneal Transplant Studies (CCTS) (vascularization  $\geq 2$  corneal quadrants in the recipient cornea).<sup>11</sup> Of note, we performed confirmatory herpes simplex virus (HSV) polymerase chain reaction testing on the recipient corneal button after keratoplasty in 7 (13%) cases. Testing was not performed in eyes that were medically treated with documented response to antivirals prior to surgery.

In all cases, MK was indicated for visual acuity loss due to full-thickness high-risk herpetic corneal scars involving the optical zone in the presence of otherwise healthy endothelium. The procedure was performed only after the eye had remained quiescent without episodes of reactivation or inflammation for a period of 6 months or longer. This series did not include eyes with persistent epithelial defects, nonhealing corneal ulcer (moderate (Stage II) to severe (Stage III) neurotrophic keratitis clinically graded on the basis of the Mackie classification for neurotrophic keratitis)<sup>12</sup> nor previous graft failure.

- **MAIN OUTCOME MEASURES:** The main outcome measures were best spectacle-corrected visual acuity (BSCVA), refractive astigmatism (RA), endothelial cell density (ECD), as well as rates of immunologic rejection, herpetic recurrence, and graft survival.

Prior to the surgery, each patient underwent a complete ophthalmologic evaluation including BSCVA testing, refraction, slit-lamp examination, tonometry, and funduscopy. Corneal vascularization was evaluated through slit-lamp biomicroscopy for extension and depth. BSCVA was recorded using the Snellen visual acuity chart and RA was determined by manifest refraction with the cross cylinder technique. Donor endothelial cell density (ECD) was evaluated by the eye bank through vital staining with 0.25% trypan blue and hypotonic sucrose solution, and light microscopy at 100 $\times$  magnification using the fixed-frame analysis technique.<sup>13</sup> Postoperative ECD was assessed by noncontact specular microscopy (EM-3000; Tomey GmbH, Erlangen, Germany) using automatic focusing and digital capture of 15 images of the central cornea. In post-keratoplasty eyes, this method has been shown to produce reliable ECD readings comparable with those obtained with manual cell identification.<sup>14</sup> Operated eyes were evaluated at least once every year for up to 10 years after surgery. Follow-up data were recorded and prospectively collected.

Inflammation secondary to herpetic recurrence versus that attributable to immunologic rejection was distinguished by assessing whether the ocular signs were limited to the graft or extend to the recipient cornea. Graft rejection was defined as the presence of epithelial, stromal and/or endothelial rejection exclusively involving the corneal graft (epithelial rejection line in otherwise clear graft; unilateral subepithelial infiltrates confined to the donor and

**TABLE 1.** Prophylaxis Protocol

Duration	Drug	Dose
Month –3 to surgery	Acyclovir	800 mg <sup>a</sup> 2× daily orally
	Ganciclovir	0.15% ophthalmic gel 1× daily
0 to Week 2	Acyclovir	800 mg <sup>a</sup> 5× daily orally
	Ganciclovir	0.15% ophthalmic gel 4× daily
	Dexamethasone	0.1% ophthalmic drops every 2 hours
Week 2 to Month 3	Acyclovir	800 mg <sup>a</sup> 5× daily orally
	Ganciclovir	0.15% ophthalmic gel 3× daily
	Dexamethasone	0.1% ophthalmic drops every 3 hours
Month 3 to Month 6	Acyclovir	800 mg <sup>a</sup> 3× daily orally
	Ganciclovir	0.15% ophthalmic gel 3× daily
	Dexamethasone	0.1% ophthalmic drops 4× daily
Month 6 to Month 12	Acyclovir	800 mg <sup>a</sup> 2× daily orally
	Ganciclovir	0.15% ophthalmic gel 2× daily
	Dexamethasone	0.1% ophthalmic drops 4× daily
Month 12 to Month 24	Acyclovir	400 mg <sup>a</sup> 2× daily orally
	Ganciclovir	0.15% ophthalmic gel 1× daily
	Dexamethasone	0.1% ophthalmic drops 1× daily
Month 24 onwards	Ganciclovir	0.15% ophthalmic gel 1× daily
	Dexamethasone	0.1% ophthalmic drops 1× daily

<sup>a</sup>Maximum dose; Modifications made were based on renal function and body weight as recommended by the manufacturer.

not associated with conjunctivitis; and inflammation, namely keratic precipitates diffuse or linear and/or an increase in anterior chamber cells from a previous visit with or without any clinically apparent change in recipient stromal thickness or clarity). On the other hand, herpetic recurrence was considered as the presence of ocular signs that were not confined to the graft margins, including typical epithelial dendritic figures, geographic ulcers, persistent epithelial defects, stromal inflammation, or endothelial precipitates.<sup>15</sup> Of note, the difference between recurrent endotheliitis and endothelial rejection is often indistinguishable. The management for these indeterminate cases required assuming the “worse” case and, therefore, treatment for immunologic rejection with steroids and antiviral cover was initiated. Graft failure involved the occurrence of a regrant for any reason or, in the absence of regrant, a cornea that was initially clear after surgery and subsequently became irreversibly opaque.

• **INTERVENTION:** MK was performed by 2 surgeons (M.B., C.B.) using our standard technique, as previously described and summarized as follows.<sup>16</sup>

After performing an initial 9-mm-diameter trephination and anterior lamellar dissection, the central 6-mm optical zone was excised full thickness. The donor cornea was split into anterior and posterior lamellae using a 250-µm microkeratome head and punched to 9 mm and 6 mm, respectively. The donor posterior donor stem was placed into the central hole of the recipient bed without sutures, and the anterior lamellar head was placed on top and sutured

**TABLE 2.** Treatment for Endothelial Immunologic Rejection

Drug	Dose
Dexamethasone	0.2% ophthalmic drops up to every hour tapered over 6 months
Methylprednisolone acetate	40 mg subconjunctivally at 2-week interval
Prednisone	1.5 mg/kg/day orally tapered over 3 months

onto the recipient bed. Combined open-sky extracapsular cataract extraction with intraocular lens implantation was performed in 4 eyes. In all patients, complete suture removal was performed within 12 months postoperatively. Wound revision for reduction of high-degree astigmatism after complete suture removal was performed in 7 eyes.

Antiviral prophylaxis treatment protocol was initiated prior to the surgery and extended indefinitely postoperatively (Table 1). In addition, prednisone (Deltacortene; Bruno Farmaceutici SpA, Roma, Italy), 1.0 mg/kg body weight daily, was started 3 days before surgery, then tapered off and discontinued within 3 months.

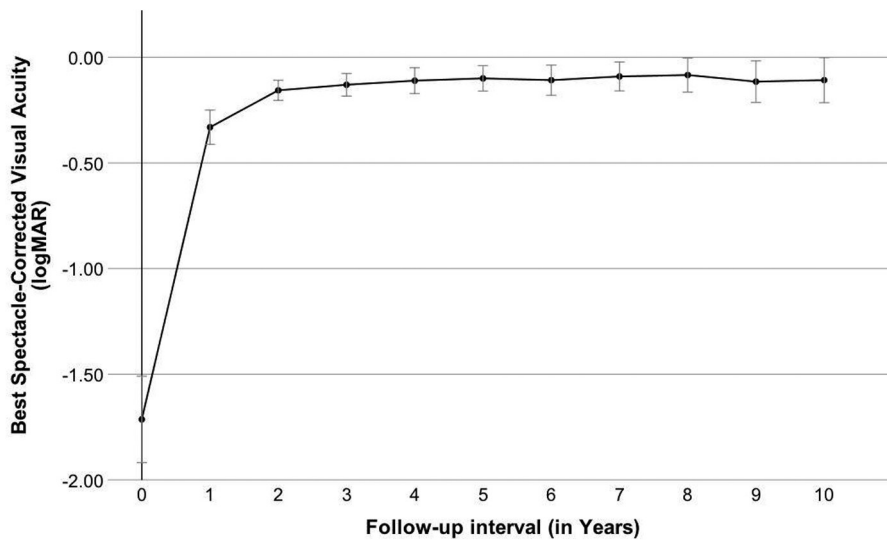
In cases of endothelial immunologic rejection, combined topical, subconjunctival, and/or oral steroids were started and tapered accordingly (Table 2).

• **DATA COLLECTION AND STATISTICAL ANALYSIS:** A total of 52 eyes with vascularized herpetic scars underwent 2-

**TABLE 3. Eyes Available for Analysis per Follow-up Interval**

Follow-up interval from date of mushroom keratoplasty (years)	1	2	3	4	5	6	7	8	9	10
Total number of eyes potentially available	52	52	52	52	52	48	42	40	30	21
Number of eyes evaluated (%) <sup>a</sup>	49 94%	44 85%	38 73%	35 69%	31 65%	31 65%	29 69%	28 70%	20 67%	15 71%
Number of eyes excluded (%) <sup>a</sup>	3 6%	8 15%	14 27%	17 31%	17 35%	17 35%	13 31%	12 30%	10 33%	6 29%
Deceased (%) <sup>a</sup>	3 6%	4 8%	4 8%	4 10%	5 10%	5 10%	4 10%	2 5%	1 3%	0 0%
Regraft (%) <sup>a</sup>	0 0%	0 0%	0 0%	0 0%	0 0%	0 0%	0 0%	1 3%	2 7%	1 5%
Lost to follow-up (%) <sup>a</sup>	0 0%	4 8%	10 19%	13 21%	12 25%	12 25%	9 21%	9 23%	7 23%	5 24%

<sup>a</sup>Percentages are expressed as proportions compared to the total number of eyes potentially available to each given follow-up interval. All 52 cases had a minimum potential follow-up of at least 5 years with decreasing number of cases with longer follow-up thereafter.



**FIGURE 2. Mean best spectacle-corrected visual acuity over 10 years following mushroom keratoplasty with 95% confidence interval. logMAR = logarithm of the minimum angle of resolution.**

piece microkeratome-assisted MK with initial high-dose and extended taper of antiviral and steroid prophylaxis. All eyes were classified as high risk. The mean age at surgery was  $48 \pm 20$  years (range: 7-84 years) and 33 (63.4%) were male. All 52 cases had a potential follow-up of at least 5 years, 48 cases at 6 years, 42 cases at 7 years, 40 cases at 8 years, 30 cases at 9 years, and 21 cases at 10 years.

Follow-up data were available for 49 (94%), 44 (85%), 38 (73%), 31 (65%), and 15 (71%) eyes at 1, 2, 3, 5, and 10 years, respectively. The number of potentially available eyes and reasons for exclusion are summarized in Table 3.

Seven patients were excluded from the visual outcome analysis due to pre-existing vision-impairing comorbidities, namely amblyopia (n = 4), end-stage glaucoma (n = 2), and retinal disease (n = 1). Phakic patients (n = 32) were included.

All the data collected in the study were entered into an electronic database (Microsoft Excel 2013 (Microsoft

Corp., Seattle, WA, USA) and analyzed using SPSS software version 26.0 (IBM Corp., New York, NY, USA). For statistical analysis, BSCVA values were converted to logarithm of minimum angle of resolution (logMAR) units. Mean and standard deviation was computed for continuous variables. Linear mixed models were used to assess for changes over 10 years. Adjustment with Bonferroni method was applied to multiple pairwise comparisons. Cumulative probability of graft rejection, recurrence and survival were computed with Kaplan-Meier analysis. The level of statistical significance was set at  $P = .05$ .

## RESULTS

THE BASELINE LOGMAR BSCVA ( $1.71 \pm 0.07$ ) SIGNIFICANTLY improved to  $0.33 \pm 0.33$  ( $P < .001$ ),  $0.17 \pm 0.18$  ( $P = .016$ ) at 1 and 2 years, respectively (Figure 2). No patient

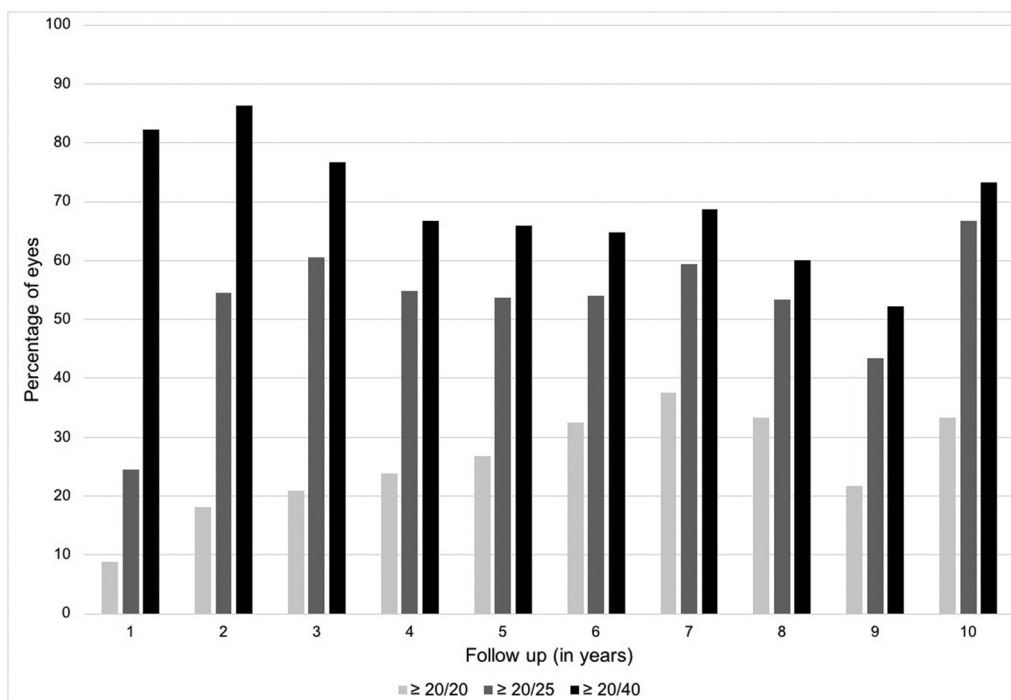


FIGURE 3. Distribution of Snellen best spectacle-corrected visual acuity over 10 years following mushroom keratoplasty.

lost any Snellen lines of vision. Two years after surgery, 86% of eyes reached  $\geq 20/40$ , 55% of eyes reached  $\geq 20/25$ , and 18% of eyes reached  $\geq 20/20$  (Figure 3). Subsequently, BSCVA remained stable throughout the 10-year annual follow-up ( $P = .662$ ).

The change in mean absolute RA from  $1.9 \pm 1.9$  diopters (D) (range: 0.00-5.50 D) preoperatively to  $3.2 \pm 0.7$  D (0.75-6.0 D) after complete suture removal was not statistically significant ( $P = .070$ ). One year after surgery, RA  $\geq 4.5$  D was observed in 7 cases (16%) and  $\geq 5$  D was observed in 4 cases (9%), all of which underwent wound revision for astigmatism reduction. At the last follow-up examination, absolute RA averaged  $2.4 \pm 1.8$  D (range: 0.50-5.50 D) and was  $\geq 4.5$  D in only 3 cases (7%) that remained undercorrected after wound revision.

Mean donor ECD was  $2485 \pm 125$  cells/mm<sup>2</sup> (range: 2100-2800 cells/mm<sup>2</sup>). Baseline mean central ECD decreased to  $1398 \pm 584$  cells/mm<sup>2</sup> after the first year with a mean ECL of  $40.9\% \pm 24.1\%$  and a subsequent average annual decline of 3.1% over 10 years (Figure 4). Four years after the surgery, mean ECD remained stable with no statistically significant annual changes up to 10 years ( $P = .075$ ). No case presented with interface haze affecting vision. In 6 eyes (11.5%), progressive lens opacification developed and standard cataract extraction via phacoemulsification with intraocular lens implantation in the capsular bag was performed between 6 and 13 months after MK.

The 10-year cumulative risk for immune rejection, herpetic recurrence, and graft failure was 9.7%, 7.8%,

and 7.6%, respectively. Kaplan-Meier estimates are presented in Figure 5, A through C. All episodes of graft rejection occurred within the first 5 years and, in all but 1 case, were reversed medically. Causes of graft failure were due to immunologic rejection ( $n = 1$ ) and herpetic recurrence (early epithelial ( $n = 1$ ) and stromal ( $n = 1$ )). Late graft failure for herpetic recurrence at 6 years occurred concurrently with loss of compliance to antiviral prophylaxis. All 3 cases of graft failure underwent regrafting.

In terms of complications related to the therapeutic regimen, no patient developed symptoms that required discontinuation of the therapy and no severe adverse effects due to systemic therapy were observed.

## DISCUSSION

IN CORNEAS WITH VASCULARIZED HERPETIC SCARS, immunologic rejection and herpetic recurrence are the 2 main causes of graft failure after corneal transplantation.<sup>2,3</sup> In fact, the presence of deep stromal vascularization, which often exceeds 2 or more quadrants, poses a significant risk for immunologic rejection,<sup>11,17-19</sup> whereas the establishment of viral latency confers an unlimited potential for HSV reactivation and clinical recurrence.<sup>20</sup>

Antiviral prophylaxis has become the standard for preventing recurrence and consequently reducing failure of corneal grafts performed for herpetic scars.<sup>1,21,22</sup> This

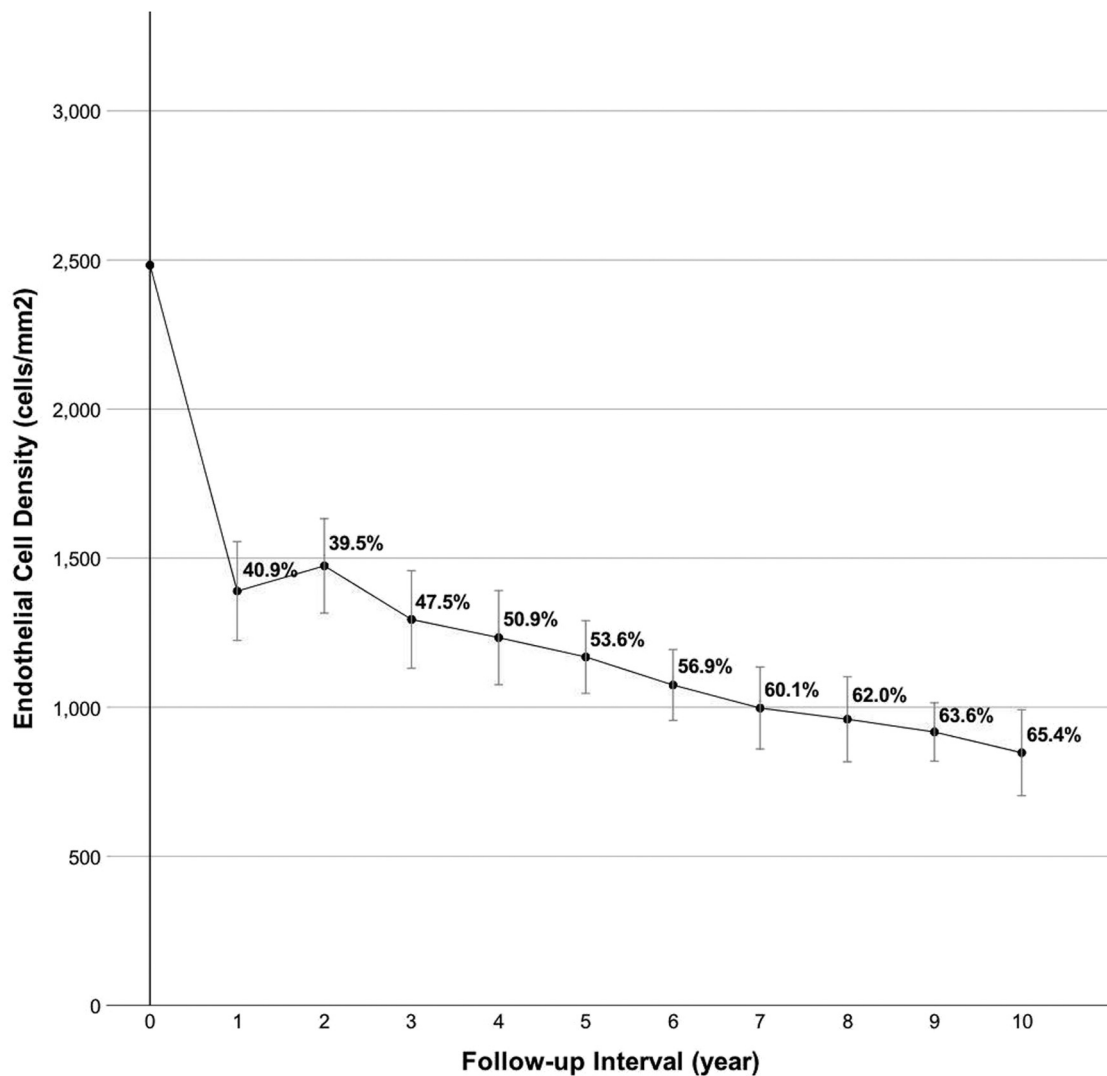


FIGURE 4. Mean endothelial cell density over 10 years following mushroom keratoplasty with 95% confidence interval. Percentage of endothelial cell loss at annual postoperative follow-up is shown in bold.

prevents reactivation of latent HSV, and avoids allograft rejection in vascularized corneas through downregulation of viral shedding and HSV-associated inflammation.<sup>23</sup> The Herpetic Eye Disease Study (HEDS) has established the efficacy of long-term oral prophylaxis with acyclovir for the prevention of herpetic recurrence, but these trials excluded patients who had previously undergone corneal transplantation.<sup>24</sup> Consequently, the same “standard” dose used in the HEDS trials cannot be applied to eyes undergoing keratoplasty for herpetic scars.

Herpetic reactivation is immunologically triggered by local trauma during ocular surgery such as keratoplasty.<sup>21,25</sup> A study by Simon and associates has found that the risk of recurrence is greater in patients on lower doses of antiviral therapy and with previous history of ocular surgery.<sup>26</sup> Thus, considering its low oral bioavailability at therapeutic doses and its satisfactory safety and tolerability profile, higher

doses of prophylactic acyclovir are required at greater frequency.<sup>27</sup> A randomized clinical trial by Goldblum and associates has validated the efficacy of high-dose oral acyclovir at doses of 800 mg used 3 or up to 5 times daily and slowly tapered over 3 years.<sup>1</sup> Additionally, in its 2014 HSV keratitis treatment guideline, the American Academy of Ophthalmology has strongly recommended the use of high-dose oral acyclovir (800 mg 3 times daily for at least 1 year) as antiviral prophylaxis after keratoplasty based on the findings from Goldblum and associates.<sup>1,21</sup> These data support the antiviral prophylactic regimen that we have adopted.

The benefits of prolonged preoperative and postoperative antiviral prophylaxis in high-risk herpetic MK cases is further substantiated by the low recurrence rate (7.8%) in this series. This finding compares favorably to recurrence rates after PK reported by Goldblum and associates

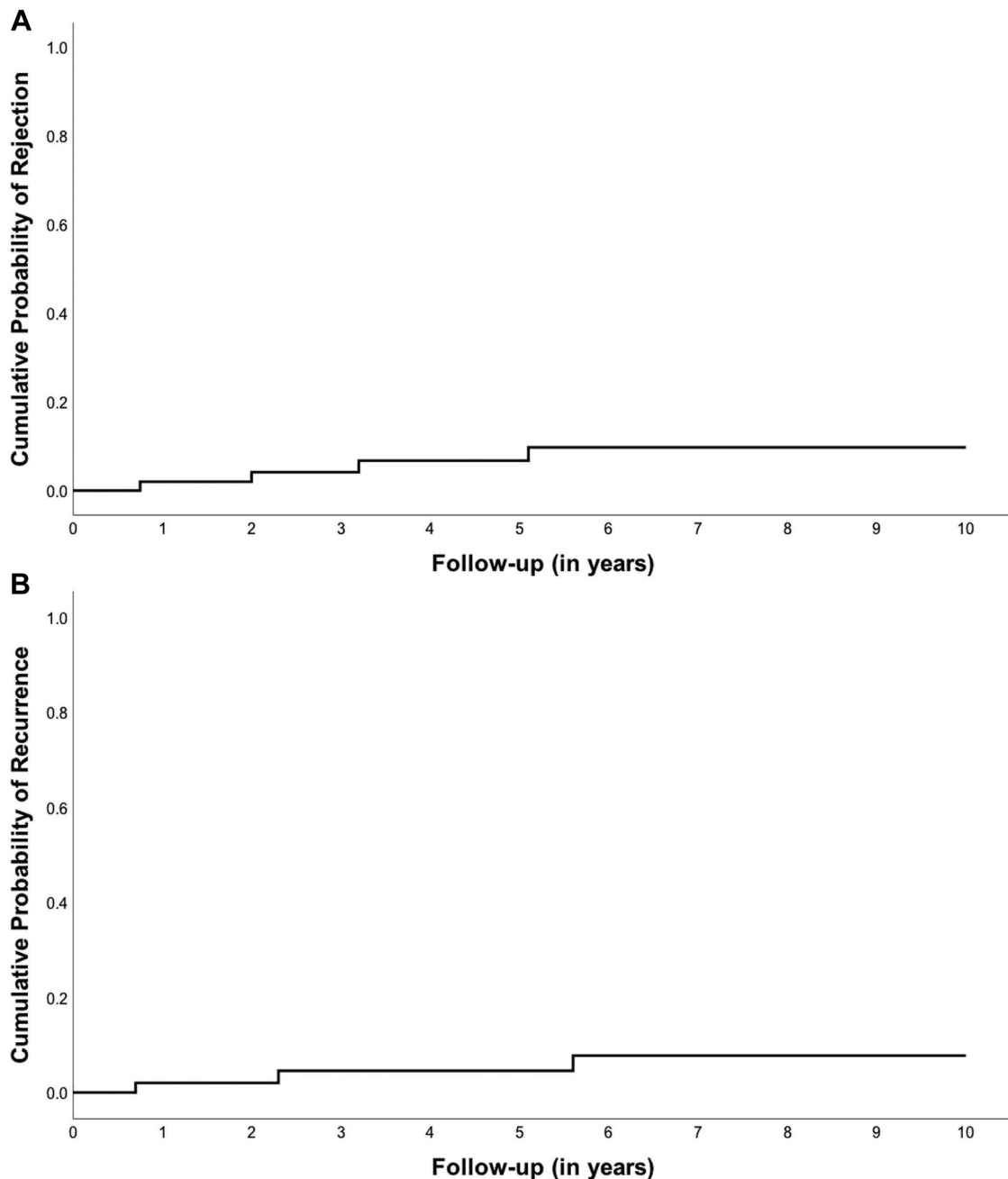


FIGURE 5. Kaplan-Meier curve analyses of immune rejection (A), herpetic recurrence (B), graft survival (C).

(15.8% at 5 years in cases treated with acyclovir 800mg 3-5 times daily tapered over 3 years)<sup>1</sup> and by Wu and associates (37.7% at 8 years in cases treated acyclovir 200 mg 5 times daily for 3 months tapered to 400 mg 2 times daily for up to 18 months).<sup>28</sup> The theoretical risk of inducing drug resistance with prolonged antiviral administration did not seem to affect the surgical outcomes in this series.<sup>29</sup> However, no patient was tested specifically for the presence of antiviral-resistant HSV strains.

Epithelial toxic effects and delayed wound healing are often cited as reasons not to routinely use topical antiviral medications. Our finding of 1 case with persistent epithelial defect resulting in graft failure confirms the possibility of such complication, as described previously in other series.<sup>22</sup> Similar to topical antiviral therapy for herpetic keratitis without keratoplasty, close monitoring for superficial punctate keratopathy and other signs of epithelial toxicity is required so tapering can be done without any further significant sequelae.

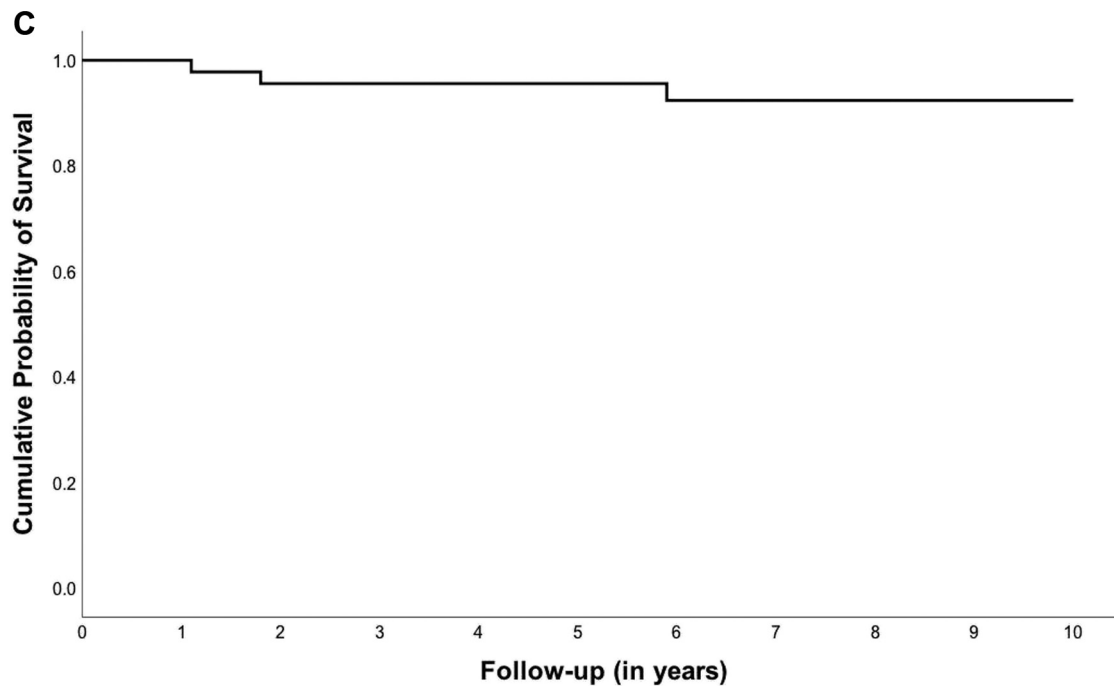


FIGURE 5. (continued).

Graft survival of conventional PK for vascularized corneas is reduced due to the violation of the corneal immune privilege by ingrowth of both blood vessels and lymphatics.<sup>9</sup> The incidence of graft rejection is positively correlated with the degree of preoperative corneal neovascularization.<sup>2,11</sup> Corneal scars from infectious causes other than HSV are likewise at high risk for rejection.<sup>10</sup> Thus, although antiviral prophylaxis may prevent herpetic recurrence and its related inflammation after keratoplasty, the presence of corneal neovascularization confers a high-risk for failure independent of the presence of HSV.<sup>11</sup> It is therefore conceivable that this high risk cannot be mitigated by antiviral prophylaxis alone.

Corticosteroids are the first-line therapy for prevention and treatment of immunologic rejection.<sup>30,31</sup> With improved understanding on the effect of inflammation and neovascularization on the immunologically quiescent environment of the cornea, the role of early intensive steroid therapy has been widely recognized for the suppression of inflammatory response mediated by antigen-presenting cells, T lymphocytes, and other effector cells.<sup>31</sup> Because immunologic graft rejection is more likely to occur with discontinuation of steroid therapy, the standard postoperative regimen for corneal transplantation often includes indefinite administration of topical steroids even in eyes at low risk for rejection.<sup>32</sup> However, the CCTS trial has demonstrated that high-risk eyes treated with intensive and prolonged postoperative topical steroids still had poor long-term prognosis with only 2 in 3 grafts surviving after 3 years and 1 in 2 after 5 years.<sup>11</sup> It is evident that

topical therapy alone does not provide sufficient prophylaxis for immune rejection in high-risk eyes.

In a study by Hill of 37 high-risk keratoplasty patients given only topical steroids, 62% failed due to rejection over a mean time of 11.2 months. Of the 23 rejected grafts, 11 rejections occurred during the first 6 months and 16 during the first year.<sup>33</sup> These findings highlight the need for intensive prophylaxis during the early postoperative period. Although this same study failed to find additional benefit of adding oral steroids (25 mg of prednisone once daily), this may have been related to inadequate steroid dosing.

To date, there is still no consensus in terms of the optimal regimen and dosing for postoperative immunosuppression. Practice pattern surveys among corneal surgeons have shown that for high-risk cases, 30%-44% of corneal surgeons prefer to routinely combine both topical and systemic therapy.<sup>5,31,34</sup> Based on our previous experience and in the design of this study, we have routinely combined topical and oral steroids and antiviral prophylaxis for all eyes. Although our prophylactic regimen may be considered aggressive, prevention of rejection is of primary importance in achieving long-term graft survival. In fact, even if an episode of immunologic rejection is reversed by aggressive steroid therapy, massive endothelial cell destruction usually occurs and often jeopardizes graft survival after the episode is controlled.<sup>11</sup>

Despite the fact that all corneas in this series were at high-risk for immunologic rejection,<sup>2,11,15</sup> the cumulative probability for rejection remained below 10% over 10



years. This rate is relatively lower than the rates for PK with postoperative oral antiviral prophylaxis reported by Garcia and associates (26% at 3 years),<sup>35</sup> Halberstadt and associates (15% at 5 years),<sup>15</sup> and Wu and associates (53.7% at 8 years).<sup>28</sup> Of note, all 3 studies included both low-risk and high-risk eyes, as opposed to our series, which included only high-risk eyes. The reduced incidence of rejection in this series may be related to a variety of factors. First, the implementation of prolonged antiviral prophylaxis has been documented to decrease the incidence of rejection after PK for herpetic scars most likely by reducing HSV-associated inflammation.<sup>1,15</sup> Secondly, the slow tapering and long-term use of corticosteroids may have prevented the development and/or allowed regression of pathologic corneal neovascularization, which has been found to be significantly correlated to allograft rejection.<sup>2,36</sup> Also, the smaller 6-mm posterior lamellar graft in MK may decrease the endothelial antigenic load and the immunologic stimuli for graft rejection. Finally, if progressive ECL or immunologic rejection were to occur, endothelial cell migration from the large healthy recipient bed could easily replace damaged donor cells.

The low cumulative probabilities for immunologic rejection and herpetic recurrence as well as the stabilization of ECL likely contribute to the high graft survival estimate in this series (96% at 5 years and 92% at 10 years). Our data compare favorably with survival rates after PK with postoperative oral antiviral prophylaxis reported by Halberstadt and associates (51% at 5 years)<sup>15</sup> and Wu and associates (56.5% at 8 years).<sup>28</sup> A study by Garcia and associates demonstrated 94% survival rate at 5 years, but included mostly low-risk PK eyes (66%) and did not use a predefined antiviral management protocol.<sup>35</sup> Overall, the observed survival rate is consistent with our previously reported outcomes, thus, indicating that vascularized herpetic corneal scars do not pose an additional threat to graft survival after MK.<sup>10,16</sup>

Two-piece MK has been proposed as a hybrid of 2 previous types of procedures. Postoperative outcomes for 2-piece MK compare favorably with the results of PK in eyes both at low- and high-risk for immunologic rejection.<sup>10</sup> The 2-piece MK graft consists of a large (9-mm-diameter) anterior lamella (mushroom “hat”), and a smaller (6-mm-diameter) posterior lamella (mushroom “stem”), which attaches to the anterior one without the need for sutures. This design combines the advantages of minimal postoperative refractive errors typical of larger full-thickness grafts and the reduced risk of immunologic rejection related to the smaller antigenic load.<sup>37</sup> In addition, the increased surface area of stromal contact between recipient and donor tissue that is obtained with the mushroom configuration theoretically speeds up wound healing compared to conventional PK.<sup>16</sup>

Our data confirm our previous observation that MK yields outstanding and stable visual outcomes in a relatively short period of time.<sup>10,16</sup> In this series, the approximate

Snellen BSCVA was 20/40 at 1 year and 20/25 at 5 years with 66% reaching 20/40. This compares favorably with reports on PK for herpetic keratitis showing a mean approximate Snellen BSCVA of 20/80 at 1 year and 20/50 at 5 years<sup>15</sup> and only 29% of patients reaching 20/40 after 5 years.<sup>2</sup> Moreover, the maintenance of BSCVA achieved at 2 years over the 10-year follow-up reflect the long-term stability of visual outcomes after MK.

In order to avoid the potential adverse effect of a stromal interface on vision, single-piece MK has been proposed for indications including corneal scars.<sup>38,39</sup> Ideally, the anterior part of the mushroom graft is centered on the limbus to minimize its radial proximity to the limbal vascular arcade, whereas the posterior part is centered on the pupil to optimize vision even in scotopic conditions.<sup>16</sup> However, as the corneoscleral limbus and the pupil are not concentric in most eyes, the donor stem should therefore be decentered from the donor hat, and this decentration would have to equally match in both donor and recipient cornea, thus posing an additional challenge for the surgeon. The 2-piece mushroom design eliminates this problem.

Interestingly, the stromal interface created through microkeratome-assisted lamellar dissection was compatible with excellent vision over 10 years. Through the optical zone, there was no detectable interface haze nor opacity soon after the surgery (Figure 1, C and E). As in laser in situ keratomileusis, the microkeratome creates a smooth, regular interface, independent of tissue clarity, consistency, or vascularization. Additionally, it overcomes the limitations of femtosecond laser-assisted MK wherein the laser may not penetrate well through opacified tissue and fails to work immediately when bleeding occurs.

Minimizing refractive astigmatism is an essential measure of success after any type of keratoplasty, but is especially so for patients with herpetic corneal scars who have a normal emmetropic fellow eye and may not be motivated to wear optical correction for a significant postsurgical refractive error.<sup>40</sup> In addition, epithelial microtrauma induced by contact lens use increases the risk of epithelial herpetic recurrence.<sup>41</sup> In PK, up to 20% of patients develop greater than 5 D of astigmatism after complete suture removal.<sup>42–44</sup> Furthermore, the treatment options for post-PK astigmatism such as arcuate keratotomy are usually associated with poor refractive predictability and complications such as corneal perforation.<sup>45</sup> In this series, utilizing a 9-mm mushroom hat has minimized postoperative RA. Moreover, the MK architecture has allowed the correction of high-degrees of astigmatism by simply opening the wound up to 2 clock hours under keratoscopic guidance at the steep meridian. To maximize the effect, the wound can be opened all the way into the anterior chamber since its step configuration is self-sealing in such limited dehiscences.<sup>10,16,46</sup>

In addition to immunologic rejection and herpetic recurrence, long-term graft survival in herpetic corneal scars is also related to ECL. Higher mean ECD was observed in

this series (1155 cells/mm<sup>2</sup>) compared with values recorded in a series using PK performed for herpetic keratitis (approximately 1000 cells/mm<sup>2</sup>) at 5 years.<sup>1</sup> In terms of ECL trend, the decline was greatest within the first year, as expected from surgically induced endothelial trauma; but within 4 years, ECD began to plateau with no significant changes between 4 and 10 years. On the other hand, the reported ECD trends of PK for various indications including diseased endothelium are nonlinear and characterized by a sharp reduction in ECD during the first 5 years and a slower but continuing decline over time.<sup>47,48</sup> Previous studies have demonstrated that ECL is more pronounced after PK for bullous keratopathy than for keratoconus with normal endothelium, suggesting that preoperative recipient endothelial health and peripheral cell density are important variables for progressive cell loss.<sup>49</sup> Thus, it is important to note that a direct comparison of the published ECD models for PK may not be reflective of true differences with the model derived in this series for herpetic keratitis alone. Nonetheless, the documented stabilization of ECL remains a noteworthy feature of MK. The average decline of ECL in our series stabilized at approximately 50% of the preoperative value, which is far greater than the minimum ECD levels documented for corneal deturgescence and transparency.<sup>47</sup> The maintenance of a stable ECL at this level most likely would be compatible with a total survival time which is longer than the 10-year period considered in this study.

In 2-piece MK, the 6-mm posterior lamella minimizes endothelial transplantation to only about 25% of the healthy recipient endothelium.<sup>16</sup> ECL stabilization can be explained by the presence of a large reservoir of healthy endothelial cells in the peripheral residual bed that migrate across the wound towards the posterior surface of the graft. This mechanism has also been demonstrated in Descemet stripping without endothelial keratoplasty wherein peripheral endothelial cells of sufficient reserve can centripetally repopulate after deliberate removal of the central corneal endothelium-Descemet membrane complex even in eyes with diseased endothelium such as Fuchs endothelial corneal dystrophy.<sup>50</sup>

The limitations of the study include incomplete follow-up and lack of controls. As commonly associated with long-term longitudinal studies, our follow-up rates over 10 years compare favorably with other reports of PK.<sup>11,51</sup> Moreover, previous publications on MK<sup>10,16</sup> have reported mid-term outcomes that were far superior to those recorded after conventional PK, thus prompting us to no longer perform stan-

dard PK. Considering the poor outcomes of conventional PK in high-risk eyes, conducting a formal experimental comparative analysis for the sole purpose of obtaining higher levels of evidence would be unfeasible. For this reason, we could only use historical controls.

PCR testing was only performed in 13% of cases, which is another limitation of the study. Consistent with current recommendations,<sup>21</sup> herpetic keratitis was diagnosed clinically, based on patient history and clinical course. We did not perform confirmatory testing routinely in patients with clinical picture compatible with herpetic keratitis and with documented response to antiviral therapy prior to surgery.

Although clinical practice has moved towards routine antiviral prophylaxis for keratoplasty, there is little published data on post-herpetic PK combined with prophylaxis beyond 5 years. Additionally, several of these studies were not based on a predetermined treatment protocol. The analysis of available literature is further complicated by a lack of stratification of groups with respect to recognized risk factors for graft failure in herpetic keratitis specifically with regards to the extent of corneal vascularization, antiviral use and graft size.<sup>36</sup> These limit the usefulness of the published data for establishing management guidelines.

Although the prophylactic regimen primarily provides the improvement in survival, the design of the current study does not allow us to attribute the improvement in outcomes solely to either the surgical or medical modifications of standard therapy. It would be desirable to determine whether the same prophylactic regimen would yield similar recurrence, rejection and survival rates in eyes undergoing conventional PK. Future clinical trials may identify the optimal dosing and surgical treatment for these high-risk cases.

While we recognize the inherent limitations of the study, our methods include strict patient selection criteria, a standard surgical technique, a predefined antiviral prophylaxis protocol, and statistical methods to account for missing data. The study strengths support the use of MK and prophylaxis for successful long-term management of a specific cohort of herpetic corneal scars, conventionally classified as high-risk for graft failure after PK.<sup>11</sup>

Though vascularized herpetic corneal scars are widely considered as high risk cases, 2-piece MK with initial high-dose and extended taper of antiviral and steroid prophylaxis has significantly improved long-term outcomes with excellent visual results, relatively early stabilization of ECL and reduced rates of herpetic recurrence, immunologic rejection and graft failure.

---

FUNDING/SUPPORT: NO FUNDING OR GRANT SUPPORT. FINANCIAL DISCLOSURES: DR BUSIN HAS RECEIVED (2006-2016) reimbursement of travel expenses and royalties from Moria (Antony, France). The following authors have no financial disclosures: Drs Yu, Friehmann, Myerscough, Socea, Furioli, Giannaccare, and Bovone. All authors attest that they meet the current ICMJE criteria for authorship. Presented in part at the Annual Meeting of the American Academy of Ophthalmology, October 12-15, 2019, San Francisco, California (USA).

---

## REFERENCES

- Goldblum D, Bachmann C, Tappeiner C, Garweg J, Frueh BE. Comparison of oral antiviral therapy with valacyclovir or acyclovir after penetrating keratoplasty for herpetic keratitis. *Br J Ophthalmol* 2008;92(9):1201–1205.
- Cobo LM, Coster DJ, Rice NS, Jones BR. Prognosis and management of corneal transplantation for herpetic keratitis. *Arch Ophthalmol* 1980;98(10):1755–1759.
- Ficker LA, Kirkness CM, Rice NS, Steele AD. The changing management and improved prognosis for corneal grafting in herpes simplex keratitis. *Ophthalmology* 1980;96(11):1587–1596.
- Armitage WJ, Goodchild C, Griffin M, et al. High-risk corneal transplantation recent developments and future possibilities. *Transplantation* 2019;103(12):2468–2478.
- Kharod-Dholakia B, Randleman JB, Bromley JG, Stulting RD. Prevention and treatment of corneal graft rejection: current practice patterns of the Cornea Society. *Cornea* 2011;34(6):609–614.
- van Rooij J, Rijnveld WJ, Remeijer L, et al. Effect of oral acyclovir after penetrating keratoplasty for herpetic keratitis: a placebo-controlled multicenter trial. *Ophthalmology* 2003;110(10):1916–1919.
- Noble BA, Agrawal A, Collins C, Saldana M, Brogden PR, Zuberbuhler B. Deep anterior lamellar keratoplasty (DALK): visual outcome and complications for a heterogeneous group of corneal pathologies. *Cornea* 2007;26(1):59–64.
- Myerscough J, Friehmann A, Bovone C, Mimouni M, Busin M. Evaluation of the risk factors associated with conversion of intended deep anterior lamellar keratoplasty to penetrating keratoplasty. *Br J Ophthalmol* 2020;104:764–767.
- Giannacare G, Weiss JS, Sapigni L, et al. Immunologic stromal rejection after deep anterior lamellar keratoplasty with grafts of a larger size (9 mm) for various stromal diseases. *Cornea* 2018;37(8):967–972.
- Scorcia V, Busin M. Survival of mushroom keratoplasty performed in corneas with postinfectious vascularized scars. *Am J Ophthalmol* 2012;153(1):44–50.
- The Collaborative Corneal Transplantation Studies Research Group. The collaborative corneal transplantation studies (CCTS). Effectiveness of histocompatibility matching in high-risk corneal transplantation. *Arch Ophthalmol* 1992;110(10):1392–1403.
- Mackie IA. Neuroparalytic keratitis. In: Fraunfelder F, Roy FH, Meyer SM, eds. *Current Ocular Therapy*. Philadelphia, PA: WB Saunders; 1995.
- Pels L, Schuchard Y. Organ culture in The Netherlands: preservation and endothelial evaluation. In: Brightbill FS, ed. *Corneal Surgery: Theory, Technique, and Tissue*. 2nd ed. St. Louis: Mosby; 1993:622–632.
- Price MO, Fairchild KM, Price FW. Comparison of manual and automated endothelial cell density analysis in normal eyes and DSEK eyes. *Cornea* 2013;32(5):567–573.
- Halberstadt M, Machens M, Gahlenbek KA, Böhnke M, Garweg JG. The outcome of corneal grafting in patients with stromal keratitis of herpetic and non-herpetic origin. *Br J Ophthalmol* 2002;86(6):646–652.
- Busin M, Madi S, Scorcia V, Santorum P, Nahum Y. A two-piece microkeratome-assisted mushroom keratoplasty improves the outcomes and survival of grafts performed in eyes with diseased stroma and healthy endothelium (An American Ophthalmological Society thesis). *Trans Am Ophthalmol Soc* 2015;113:T1.
- Price FW Jr, Whitson WE, Collins KS, Marks RG. Five-year corneal graft survival. A large, single-center patient cohort. *Arch Ophthalmol* 1993;11(6):799–805.
- Dandona L, Naduvilath TJ, Janarthanan M, Ragu K, Rao GN. Survival analysis and visual outcome in a large series of corneal transplants in India. *Br J Ophthalmol* 1997;81(9):726–731.
- Vail A, Gore SM, Bradley BA, Easty DL, Rogers CA. Corneal graft survival and visual outcome. A multicenter study. *Ophthalmology* 1994;101(1):120–127.
- Mannis MJ, Plotnik RD, Schwab IR, Newton RD. Herpes simplex dendritic keratitis after keratoplasty. *Am J Ophthalmol* 1991;111(4):480–484.
- White ML, Chodosh J. Herpes simplex virus keratitis: a treatment guideline. Available at <https://www.aao.org/clinical-statement/herpes-simplex-virus-keratitis-treatment-guideline>. Accessed March 6, 2020.
- Moyes AL, Sugar A, Musch DC, Barnes RD. Antiviral therapy after penetrating keratoplasty for herpes simplex keratitis. *Arch Ophthalmol* 1994;112(5):601–607.
- Beyer CF, Arens MQ, Hills GA, Rose BT, Beyer LR, Schanzlin DJ. Oral acyclovir reduces the incidence of recurrent herpes simplex in rabbits after penetrating keratoplasty. *Arch Ophthalmol* 1989;107(8):1200–1205.
- Acyclovir for the prevention of recurrent herpes simplex virus eye disease. Herpetic Eye Disease Study Group. *N Engl J Med* 1998;339(5):300–306.
- Nicholls SM, Shimeld C, Easty DL, et al. Recurrent herpes simplex after corneal transplantation in rats. *Invest Ophthalmol Vis Sci* 1996;37:425–435.
- Simon AL, Pavan-Langston D. Long-term oral acyclovir therapy. Effect on recurrent infectious herpes simplex keratitis in patients with and without grafts. *Ophthalmology* 1996;103(9):1399–1404.
- Brunton L, Parker K, Blumenthal D, Buxton I. Goodman and Gilman's the pharmacologic basis of therapeutics. New York, NY: McGraw-Hill; 2018:812–818.
- Wu SQ, Zhou P, Zhang B, Qiu WY, Yao YF. Long-term comparison of full-bed deep lamellar keratoplasty with penetrating keratoplasty in treating corneal leucoma caused by herpes simplex keratitis. *Am J Ophthalmol* 2012;153(2):291–299.
- Duan R, de Vries RD, Osterhaus AD, Remeijer L, Verjans GM. Acyclovir-resistant corneal HSV-1 isolates from patients with herpetic keratitis. *J Infect Dis* 2008;198(5):659–663.
- Langston RHS, Pavan-Langston D, Dohlman CH. Penetrating keratoplasty for herpetic keratitis: Prognostic and therapeutic determinants. *Trans Am Acad Ophthalmol Otolaryngol* 1975;79:577–583.
- Rinne JR, Doyle Stulting RD. Current practices in the prevention and treatment of corneal graft rejection. *Cornea* 1992;11(4):326–328.
- Shimazaki J, Iseda A, Satake Y, Shimazaki-Den S. Efficacy and safety of long-term corticosteroid eye drops after penetrating keratoplasty: a prospective, randomized, clinical trial. *Ophthalmology* 2012;119(4):668–673.

33. Hill JC. The use of cyclosporine in high-risk keratoplasty. *Am J Ophthalmol* 1989;107:506–510.
34. Koay PY, Lee WH, Figueiredo FC. Opinions on risk factors and management of corneal graft rejection in the United kingdom. *Cornea* 2005;24:292–296.
35. Garcia DD, Farjo Q, Musch DC, Sugar A. Effect of prophylactic oral acyclovir after penetrating keratoplasty for herpes simplex keratitis. *Cornea* 2007;26(8):930–934.
36. Goodfellow JFB, Nabili S, Jones MN, et al. Antiviral treatment following penetrating keratoplasty for herpetic keratitis. *Eye (Lond)* 2011;25(4):470–474.
37. Skeens HM, Holland EJ. Large-diameter penetrating keratoplasty: indications and outcomes. *Cornea* 2010;29(3):296–301.
38. Della Valle V, Bonci P. Excimer laser mushroom penetrating keratoplasty: new technique. *Eur J Ophthalmol* 2014;24(2):186–190.
39. Graef S, Maier P, Boehringer D, Auw-Haedrich C, Reinhard T. Femtosecond laser-assisted repeat keratoplasty: a case series. *Cornea* 2011;30(6):687–691.
40. Larkin DF. Corneal transplantation for herpes simplex keratitis. *Br J Ophthalmol* 1998;82(2):107–108.
41. Mucci JJ, Utz VM, Galor A, Feuer W, Jeng BH. Recurrence rates of herpes simplex virus keratitis in contact lens and non-contact lens wearers. *Eye Contact Lens* 2009;35(4):185–187.
42. Swinger CA. Postoperative astigmatism. *Surv Ophthalmol* 1987;31(4):219–248.
43. Binder PS. The effect of suture removal on postkeratoplasty astigmatism. *Am J Ophthalmol* 1988;105(6):637–645.
44. Limberg MB, Dingeldein SA, Green MT, Klyce SD, Insler MS, Kaufman HE. Corneal compression sutures for the reduction of astigmatism after penetrating keratoplasty. *Am J Ophthalmol* 1989;108(1):36–42.
45. Ho Wang Yin G, Hoffart L. Post-keratoplasty astigmatism management by relaxing incisions: a systematic review. *Eye Vis (Lond)* 2017;4:29.
46. Elkadim M, Myerscough J, Bovone C, Busin M. A novel blunt dissection technique to treat modified deep anterior lamellar keratoplasty (DALK)-associated high astigmatism. *Eye (Lond)* 2019; <https://doi.org/10.1038/s41433-019-0686-6>.
47. Cornea Donor Study Research Group. Donor age and factors related to endothelial cell loss 10 years after penetrating keratoplasty: Specular Microscopy Ancillary Study. *Ophthalmology* 2013;120(12):2428–2435.
48. Riddlesworth TD, Kollman C, Lass JH, et al. A mathematical model to predict endothelial cell loss following penetrating keratoplasty with selective dropout from graft failure. *Invest Ophthalmol Vis Sci* 2014;55(12):8409–8415.
49. Langenbucher A, Nguyen NX, Seitz B. Predictive donor factors for chronic endothelial cell loss after nonmechanical penetrating keratoplasty in a regression model. *Graefes Arch Clin Exp Ophthalmol* 2003;241(12):975–981.
50. Borkar D, Veldman P, Colby KA. Treatment of Fuchs endothelial dystrophy by Descemet stripping without endothelial keratoplasty. *Cornea* 2016;35(10):1267–1273.
51. Ing JJ, Ing HH, Nelson LR, Hodge DO, Bourne WM. Ten-year postoperative results of penetrating keratoplasty. *Ophthalmology* 1998;105(10):1855–1865.