

# Posterior Capsule Opacification With Two Hydrophobic Acrylic Intraocular Lenses: 3-Year Results of a Randomized Trial



CHRISTINA LEYDOLT, DANIEL SCHARTMÜLLER, LUCA SCHWARZENBACHER, VERONIKA RÖGGLA, SABINE SCHRIEFL, AND RUPERT MENAPACE

- **PURPOSE:** To compare the incidence and intensity of posterior capsule opacification (PCO) and neodymium–yttrium–aluminum–garnet (Nd:YAG) capsulotomy rates between 2 similar open-loop single-piece hydrophobic acrylic intraocular lenses (IOLs) that differ in the proprietary material characteristics and design features, over a period of 3 years.
- **DESIGN:** Randomized, prospective, patient- and examiner-masked clinical trial with intraindividual comparison.
- **METHODS:** SETTING: Department of Ophthalmology, Medical University of Vienna, Vienna, Austria. PATIENT POPULATION: Eighty patients (160 eyes) had bilateral cataract surgery and received a Vivinex XY1 IOL in 1 eye and an AcrySof SN60WF IOL in the other eye. OBSERVATION PROCEDURES: Follow-up examinations were performed 3 years after surgery. Digital retroillumination images were taken of each eye. The amount of PCO (score: 0–10) was assessed subjectively at the slit lamp and objectively using automated image analysis software (AQUA). MAIN OUTCOME MEASURE: PCO score (scale, 0–10).
- **RESULTS:** The mean objective PCO score of the Vivinex XY1 IOLs was  $0.9 \pm 0.8$  compared to the PCO score of  $1.4 \pm 1.1$  for the AcrySof SN60WF IOLs ( $P < .001$ ). Three years postoperatively, 11.4% of patients had an Nd:YAG capsulotomy in the Vivinex XY1 eye and 18.6% had a capsulotomy in the AcrySof SN60WF eye ( $P = .23$ ).
- **CONCLUSION:** The new hydrophobic acrylic Vivinex XY1 IOL showed significantly lower PCO rates and lower YAG rates compared to the AcrySof SN60WF IOL. The interaction of various factors such as hydrophobic material, smooth optic surface, and sharp posterior optic edge plays a key role in PCO development. (Am J Ophthalmol 2020;217:224–231. © 2020 The Authors. Published by Elsevier Inc. This is an open access article

under the CC BY-NC-ND license (<http://creativecommons.org/licenses/by-nc-nd/4.0/>.)

**P**OSTERIOR CAPSULE OPACIFICATION (PCO) REMAINS a common complication leading to unsatisfying results by decreased visual function after uneventful cataract surgery with implantation of an intraocular lens (IOL).<sup>1–3</sup> Treatment of PCO by neodymium–yttrium–aluminum–garnet (Nd:YAG) laser capsulotomy is effective, but it is not always available; can lead to further complications such as intraocular pressure rise, ocular inflammation, cystoid macular edema, and retinal detachment<sup>4,5</sup>; and is associated with additional costs. Unless timely detected and treated, PCO increases the incidence of falling, particularly in elderly patients.<sup>6</sup> Therefore, sustained efforts have been made to develop new ways to prevent the formation of PCO. Apart from improvements in surgical technique, these comprise alterations in lens design, lens material, and lens surface modification. Nowadays a multitude of different IOLs are available, with sometimes only small discrepancies in IOL design and surface properties or chemical composition of the material. Hydrophobic acrylic foldable IOLs represent 56% of the IOL market globally.<sup>7</sup>

The present prospective, randomized, controlled study intraindividually compares 2 such IOLs, the Vivinex XY1 (Hoya Surgical Optics, Tokyo, Japan) and the AcrySof SN60WF IOL (Alcon Laboratories, Fort Worth, Texas, USA), within a follow-up period of 3 years. These IOLs differ slightly in their particular material, optic surface, and sharp posterior edge design. Thus the aim of the study was to identify any resulting differences in PCO development.

## METHODS

- **PATIENT RECRUITMENT, RANDOMIZATION, INTRAOCULAR LENS ASSIGNMENT, AND SURGICAL TECHNIQUE:** Eighty patients (160 eyes) were included in this prospective, randomized clinical trial (Clinical Trial Number: NCT04196673) for intraindividual comparison. The study was performed at the Department of Ophthalmology at the Vienna General Hospital (Medical University of Vienna,

Accepted for publication Apr 14, 2020.

From the Department of Ophthalmology, Medical University of Vienna, Vienna, Austria.

Inquiries to Rupert Menapace, Department of Ophthalmology, Medical University of Vienna, Waehringer Guertel 18-20, A-1090 Vienna, Austria; e-mail: [rupert.menapace@meduniwien.ac.at](mailto:rupert.menapace@meduniwien.ac.at)

Vienna, Austria). The patients were recruited in a continuous cohort. Inclusion criteria were bilateral age-related cataract, age 40 and older, visual potential in both eyes of 20/30 or better, and normal findings in medical history and physical examination. Exclusion criteria were a history of ocular disease, preceding ocular surgery or trauma, relevant other ophthalmic diseases (such as pseudoexfoliation, retinal degenerations, etc), uncontrolled systemic or ocular disease, and any intraoperative complication. The study was approved by the local ethics committee of the Medical University of Vienna, Austria (EK 1560/2014). All the research and measurements followed the tenets of the Declaration of Helsinki and informed consent was obtained from all subjects in this study.

Surgery was performed by 2 experienced surgeons (R.M., C.L.) using a standardized, small-incision phacoemulsification technique. Most surgeries were immediate sequential cataract surgeries. Preoperative IOL power calculations for both IOL types were performed by the surgeon using the IOLMaster 700 (Carl Zeiss Meditec AG, Jena, Germany) with SRKT and Haigis formulas.

Before the start of the study a randomization list was generated with the DataInf RandList version 2.0 (DataInf GmbH, Tuebingen, Germany) software for simple randomization procedure. A sequentially numbered sealed envelope (provided by an investigator with no clinical involvement in the trial) was opened in the operating room by an assistant and presented to the surgeon after phacoemulsification. The envelope contained the subject's right eye randomization assignment to 1 of the IOLs (Vivonex XY1 or AcrySof SN60WF). The randomly assigned IOL was implanted in the subject's first eye. The second eye was implanted with the other IOL. Patients and investigators were masked to IOL type. After the end of the study, all data were entered and the subject's implanted IOLs were unmasked with the randomization list for statistical analysis thereafter.

After topical anesthesia, a 2.2-mm posterior-limbal self-sealing incision was made. The anterior chamber was filled with a dispersive ophthalmic viscoelastic device (OVD) (Eyefill HD, Bausch & Lomb, Rochester, NY) and a continuous curvilinear capsulorhexis with a diameter of 5 mm was created to attain a symmetrical 360-degree rhexis-IOL overlap. The surgeon was unmasked to the IOL type after hydrodissection, phacoemulsification, and cortical cleanup. The folded IOLs were implanted in the bag with an injector following expansion of the capsular bag with a cohesive OVD (ProVisc, Alcon, Fort Worth, TX). After IOL implantation, the OVD was thoroughly removed from the anterior chamber, the capsular bag, and behind the IOL optic by coaxial irrigation/aspiration. There were no surgical complications that would have led to patient exclusion. At the completion of surgery, all optics were circumferentially overlapped by the anterior capsule leaf.

Most cases were performed as immediate sequential cataract surgeries; that is, surgery was performed in both eyes on

the same day but as separate procedures. After the (randomly assigned) first eye was completed the second eye was disinfectected with povidone-iodine and than a sterile cover was applied, followed by standard surgery as described above.

Postoperative treatment consisted of dexamethasone and gentamicin eye drops (Dexagenta; Ursapharm Ges.m.b.H., Klosterneuburg, Austria) 3 times a day for 1 week and keterolac (Acular; Allergan, Ettlingen, Germany) eye drops 3 times a day for 3 weeks.

All surgeries were performed between September 2015 and April 2016 by 2 surgeons using the same standardized surgical technique. Each patient received a Vivonex XY1 IOL in 1 eye and an AcrySof SN60WF IOL in the contralateral eye to allow for intraindividual comparison. The Vivonex XY1 IOL is a preloaded 1-piece hydrophobic acrylic blue-light filtering IOL with a biconvex aspheric optic and a stepped, or "enhanced," posterior optic edge beneath the haptic-optic junction. It has an optic diameter of 6.0 mm, an overall length of 13.0 mm, and haptics of the same acrylic material as the optic with a C-loop configuration with no angulation. The AcrySof SN60WF is a 1-piece blue-light filtering IOL of hydrophobic acrylate/methacrylate copolymer with an asymmetric biconvex optic and a posterior sharp edge interrupted at the optic-haptic junction. It also features an optic diameter of 6.0 mm, an overall length of 13.0 mm, and supporting haptics of the same acrylic material as the optic with no haptic angulation.

• **FOLLOW-UP EXAMINATIONS AND IMAGE ACQUISITION:**

Follow-up examinations were performed 3 years after surgery. On each occasion best-corrected visual acuity (BCVA) in logMAR was assessed with ETDRS charts. Intraocular pressure measurements were taken; thereafter patients received phenylephrine 2.5% and tropicamide 0.5% at least half an hour before they were examined at the slit lamp. The amount and type of regenerative PCO (score 0-10) was evaluated subjectively. A subjective score of 0-10 was used, where 0 stands for a clear capsule and 10 stands for severe regenerative PCO. The presence of glistenings, as well as a semi-quantitative slit-lamp grading of glistening density, was assessed: with the slit-lamp beam set at 10.0 mm by 2.0 mm, the glistenings were graded as trace = fewer than 10; 1+ = 10-20; 2+ = 20-30; 3+ = 30-40; and 4+ = more than 40.<sup>8</sup> Patients were also asked about any disturbing visual symptoms such as edge glare or dysphotopsia (yes/no) and a full retinal examination was performed. Finally, the need for an Nd:YAG laser capsulotomy was noted, based on BCVA > logMAR 0.1 and subjective patient complaint of reduced visual acuity, as well as the presence of regenerative after-cataract in the central optic-capsule interspace as judged under retroillumination and slit-beam illumination.

If patients have had an Nd:YAG laser capsulotomy before the 3-year follow-up, this was also noted; these eyes were excluded for PCO analysis.

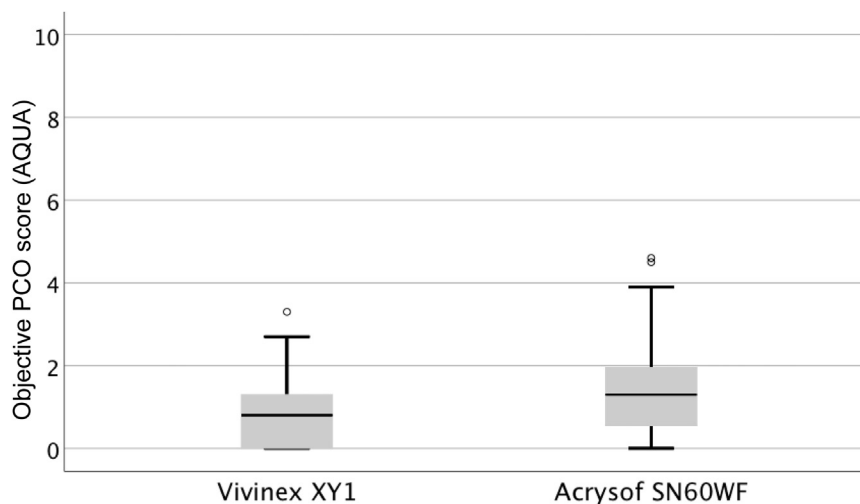


FIGURE 1. Objective posterior capsule opacification (PCO) score (AQUA) of the Vivinex XY1 and AcrySof SN60WF IOL 3 years postoperatively represented with box plots. Boxes show the interquartile range, whiskers the non-outlier minimum and maximum. There was a significant difference between the 2 IOLs ( $P < .001$ ).

Digital retroillumination images were taken from the posterior capsule. For this purpose, a digital camera (Nikon AS-15; Nikon, Tokyo, Japan) mounted on a modified Zeiss 30 slit lamp (Carl Zeiss Meditec AG, Jena, Germany) with an external light and flash-light source was used providing coaxial illumination from the flash-pack through a fiber-optic cable to the camera. It produces even illumination over the entire image with relatively small flash artifacts, and shows high reproducibility.<sup>9</sup> It is used for documentation of regenerative PCO. All digital images were transferred to a personal computer (PC) and stored on hard disc for later evaluation.

• **DATA EVALUATION AND IMAGE ANALYSIS:** The data from the evaluation forms (subjective slit-lamp examination) were entered into a Microsoft Excel sheet. All further evaluation was done on the PC using standard software (MS Excel; Microsoft, Redmont, WA and SPSS; IBM, Armonk, NY). The results were separated into 2 groups according to the IOL type (Vivinex XY1 IOL or AcrySof SN60WF IOL) and mean values were calculated for the attributes mentioned above.

As the amount of PCO was of primary interest for this study, we also used automated image analysis software for objective PCO evaluation (AQUA—Automated Quantification of After-Cataract; Institute for Computer Graphics and Vision, Technical University Graz, Austria). The system has been shown to correlate well with subjective scoring of PCO.<sup>10</sup> However, it is fully automated and there is no subjective bias to the evaluation process. Retroillumination images from each patient were imported into the program, and the area within the capsulorhexis was evaluated. The rhexis edge is detected by the program in a semi-automatic (computer-aided) way. The AQUA software calculates the entropy (grade of disorder)

of a bitmap. This value is converted into a score between 0 and 10 (where 0 stands for a “clear” capsule and 10 for exceptionally severe PCO). Mean objective PCO scores were calculated with this software for the Vivinex XY1 and AcrySof SN60WF IOL group using the 3-year retroillumination images.

• **SAMPLE SIZE CALCULATION AND STATISTICS:** One hundred and sixty eyes of 80 patients with bilateral cataract were included in this prospective randomized comparative study. The number was selected to detect a difference in PCO percentage of 5% between groups after 3 years using a standard deviation of 1.5 from our previous long-term PCO studies with the AcrySof IOL. The type I and type II errors were set to 0.05 and 0.2, respectively. At least 58 patients are necessary for a power of 0.8. To account for a drop-out rate of about 27.5% (mean drop-out rate of our previous long-term PCO studies) after 3 years in this elderly population, 80 patients were included in the study.

The results from the Vivinex XY1 and AcrySof SN60WF IOL groups were compared and the differences between the 2 groups were calculated. Statistical significance was calculated using paired t tests and McNemar tests. A P value of .05 or less was considered significant. Data are presented as means  $\pm$  standard deviation (SD).

## RESULTS

THE AGE OF THE STUDY PATIENTS WAS  $71.6 \pm 7.7$  YEARS. TEN patients were not available for the 3-year follow-up examination: 2 patients did not show up at the arranged appointment, and 8 patients could not be contacted (ie, returned

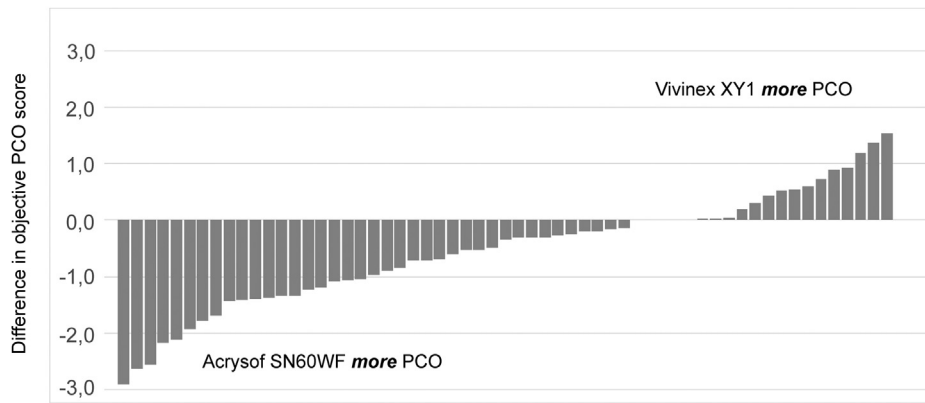


FIGURE 2. Individual differences of regenerative posterior capsule opacification (PCO) score (AQUA) 3 years postoperatively.

mail because of change of address or possibly death, or they could not be reached via telephone). Therefore it is not known whether these patients died or moved to a nursing home. Of the 80 patients included in the study, 70 patients (87.5%) could be examined after 3 years. Mean postoperative follow-up was  $36.3 \pm 0.9$  months. No serious adverse event occurred in any group.

PCO in digital retroillumination images was evaluated objectively with the AQUA software. Three years postoperatively, a mean objective PCO score (scale: 0-10) of  $0.9 \pm 0.8$  was found for the Vivonex XY1 group ( $n = 64$ ) and a score of  $1.4 \pm 1.1$  for the AcrySof SN60WF group ( $n = 62$ ) ( $P < .001$ ) (Figure 1). A total of 13.6% of patients ( $n = 8$ ) showed the same amount of regenerative PCO in both eyes, whereas 20.3% ( $n = 12$ ) showed more regenerative PCO in the Vivonex XY1 eye and 66.1% ( $n = 39$ ) showed more regenerative PCO in the AcrySof SN60WF eye (Figure 2). In 28.1% ( $n = 18$ ) of the Vivonex XY1 eyes and 12.9% ( $n = 8$ ) of the AcrySof SN60WF eyes, no regenerative PCO was seen at 3 years. Figure 3 shows 3 representative cases of our data set.

Before the 3-year follow-up, 8.6% (6 patients) had an Nd:YAG laser capsulotomy in their Vivonex XY1 eye and 11.4% (8 patients) in their AcrySof SN60WF eye ( $P = .73$ ). After the 3-year examination, 2 additional patients had a capsulotomy in the Vivonex XY1 group and 5 additional patients in the AcrySof SN60WF group, resulting in an overall capsulotomy rate of 11.4% (8 patients) in the Vivonex XY1 and 18.6% (13 patients) in the AcrySof SN60WF group ( $P = .23$ ). Figure 4 shows a Kaplan-Meier plot of time to Nd:YAG laser capsulotomy of Vivonex XY1 compared with AcrySof SN60WF.

Three years postoperatively, 1 patient (1.5%) showed IOL glistening (density: trace) in the Vivonex XY1 eye, whereas in 64 patients (92.8%) of the AcrySof SN60WF eyes glistening was detected ( $P < .001$ ). The density of glistenings in the AcrySof SN60WF IOLs was as follows: trace: 17.4% ( $n = 12$ ); 1+: 13.0% ( $n = 9$ ); 2+: 21.7% ( $n = 15$ ); 3+: 26.1% ( $n = 18$ ); and 4+: 14.5% ( $n = 10$ ).

Similar to the objective image analysis findings, subjective PCO score from slit-lamp examination (scale: 0-10) was  $1.4 \pm 1.4$  ( $n = 64$ ) for the Vivonex XY1 group and  $2.3 \pm 2.0$  ( $n = 62$ ) for the AcrySof SN60WF group ( $P = .001$ ). Concerning BCVA, both IOLs showed no difference 3 years after surgery (Vivonex XY1: logMAR  $-0.05 \pm 0.18$ ; AcrySof SN60WF: logMAR  $-0.05 \pm 0.10$ ;  $n = 67$ ;  $P = .90$ ). We also found no significant difference in subjective optical symptoms such as edge glare or dysphotopsia described by the patients (Vivonex XY1: 2.9%,  $n = 2$ ; AcrySof SN60WF: 2.9%,  $n = 2$ ;  $P = 1.0$ ).

## DISCUSSION

THREE YEARS POSTOPERATIVELY THE VIVINEX XY1 IOLS showed significantly lower objective PCO rates compared to the AcrySof SN60WF IOLs in this prospective randomized controlled fellow-eye clinical trial (Vivonex XY1: PCO:  $0.9 \pm 0.8$ ; AcrySof SN60WF: PCO:  $1.4 \pm 1.1$ ;  $P < .001$ , PCO scale: 0-10). This difference was confirmed by the subjective PCO score from slit-lamp examination for the Vivonex XY1 group ( $1.4 \pm 1.4$ ) and for the AcrySof SN60WF group ( $2.3 \pm 2.0$ ) ( $P = .001$ ). Though not statistically significant, YAG rates were also lower in the Vivonex XY1 group (11.4%) compared to the AcrySof SN60WF group (18.6%) ( $P = .23$ ).

The importance of a square posterior optic edge as a major factor for the prevention of PCO formation by inhibiting migration of lens epithelial cells (LECs) beneath the IOL optic was pointed out in many studies.<sup>11-20</sup> The barrier effect of a sharp optic edge<sup>21</sup> has been attributed to contact inhibition of migrating LECs at the capsular bend,<sup>22,23</sup> and/or the mechanical pressure exerted along a square-edged optic profile.<sup>24</sup> The successful PCO-preventing effect of sharp-edged IOLs has become widely accepted and led to the production of various IOL models




FIGURE 3. Retroillumination images of 3 representative patients.

of similar materials and designs with often only minor differences.

It has been postulated that the sharper the optic edge, the more effectively the migration of LECs is prevented.<sup>20</sup> Nevertheless, the sharpness of the posterior edge varies not only among different materials in the sense that hydrophilic acrylic IOLs generally feature rounder edges because of postprocessing hydration and swelling, but also among IOLs made of similar hydrophobic materials.<sup>25,26</sup> Nanavaty and associates stated that IOLs with a radius of curvature of less than 10.0  $\mu\text{m}$  provide an effective barrier effect. Both IOLs exhibit a sharp edge profile, with the Vivinex XY1 showing an even sharper posterior edge with 7.6  $\mu\text{m}$  radius of curvature and an even thinner edge profiles of 150.5  $\mu\text{m}$  compared to the AcrySof SN60WF (radius of curvature: 8.5  $\mu\text{m}$ ; edge thickness: 197.7  $\mu\text{m}$ ).<sup>25</sup>

A common feature of the Vivinex XY1 and the AcrySof SN60WF IOL is that the optic edge does not exhibit a stepped (“enhanced”) square edge design. In this area the impeded fusion of the capsule leaves results in a lack of bending of the posterior capsule around the posterior optic

edge. The optic-haptic junction may serve as a gateway for LECs to access the retro-optical space, resulting in more PCO. However, the haptic junction above a stepped edge still does not allow effective and permanent bending. Owing to the small step height and the inability of the capsular leaves to attach to each other, the barrier effect is often only transient.<sup>27</sup> The square posterior optic edge has mostly been considered as the major factor for prevention of PCO formation, but the IOL material continues to play an important but still not fully clarified role in this complication.

Hydrophobic acrylic is one of the most popular materials for intraocular lenses. It is made of chains of copolymers of acrylate and methacrylate derived from rigid polymethylmethacrylate with the purpose of making IOLs durable and foldable. The AcrySof IOL was the first hydrophobic acrylic foldable lens, introduced in 1993. Since then variations in design and also material were launched. The key features of hydrophobic acrylic lenses are a good biocompatibility and low PCO rates, as well as good mechanical properties allowing controlled implantation and unfolding.

The AcrySof SN60WF IOL has been shown to have a low incidence of PCO development.<sup>28–30</sup> It is made of a

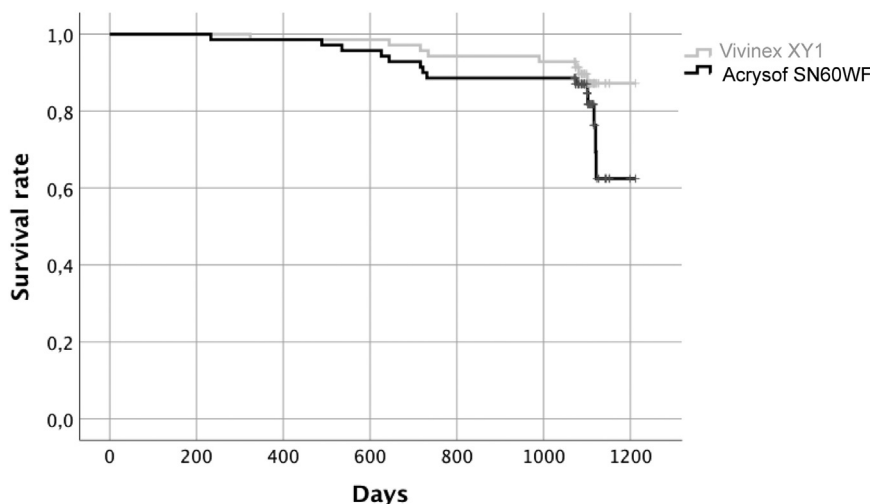


FIGURE 4. Kaplan-Meier survival plot of time to neodymium–yttrium–aluminum–garnet laser capsulotomy of Vivinex XY1 compared with AcrySof SN60WF intraocular lenses.

hydrophobic acrylate/methacrylate copolymer and has been subjected to plasma etching. Plasma treatment of the optic is a method of hydrophilization, which increases adhesive forces between the IOL and the capsular bag. The sandwich theory proposed by Linnola<sup>31</sup> claims that the formation of a sandwich compound of IOL, LEC layer, and posterior capsule promotes adhesion that inhibits the formation of PCO. Rather than the direct contact between the IOL and the posterior capsule, the LEC monolayer acts as adhesive glue between the IOL and posterior capsule. In addition to LECs, proteins from the extracellular matrix, including fibronectin, vitronectin, laminin, and collagen IV, play a role in this adhesion. This single-layer cell proliferation probably does not influence transparency and only slightly influences contrast sensitivity. Alternatively, or in addition to this postulated PCO-inhibiting effect over the whole posterior IOL surface, firm collagenous sealing of the 2 capsular leaves along the optic rim that resists secondary mechanical opening of the fused capsules with consecutive reversal of posterior capsule bend has been proposed as an important factor for a lasting barrier effect against retro-optical PCO development.<sup>32</sup> This again may be determined by the specific material and surface characteristics of a particular IOL.

The improvement of the chemico-physical characteristics of IOLs, such as material hydrophobicity and surface roughness, influences cell adhesion and migration. Tanaka and associates<sup>33</sup> found reduced cell adhesion on hydrophobic acrylic IOLs with a lower surface roughness and higher water contact angle. The Vivinex XY1 exhibits in vitro significantly higher mean contact angle values than other IOL models, indicating a high hydrophobicity of the IOL material.<sup>34</sup> A recent study evaluating the surface roughness of IOLs corroborated that the Vivinex XY1 IOL presents by far the lowest surface roughness among other new IOL models.<sup>34</sup>

Unlike the AcrySof SN60WF, the Vivinex XY1 IOL has a modified posterior surface. The posterior surface of this IOL is treated with ultraviolet-ozone (UV/O<sub>3</sub>) irradiation, which creates active binding sites and introduces oxygen-containing functional groups on the surface material, enhancing protein adsorption and cell adhesion.<sup>35</sup> This IOL surface modification improves adhesion between the IOL and the posterior capsule through a single layer of LECs and adhesion proteins, such as fibronectin, thus preventing LEC migration and PCO formation. Comparing surface-treatment methods, argon plasma—as used with the AcrySof IOL—was associated with an etching effect that can promote surface deterioration, whereas UV/O<sub>3</sub> treatment produced little damage to the lens surface. Also, ultraviolet-ozone treatment was shown to be more effective than argon plasma treatment in preventing PCO in a rabbit study.<sup>35</sup>

Another in vitro study with a graded culture human capsular bag model that reflects the pattern of postsurgical changes found that the Vivinex IOL showed an overall better level of performance than the AcrySof IOL, such that progression of PCO appears to be slower. In addition, cells are less likely to populate the IOL surface of the Vivinex IOL than the AcrySof IOL, which further reduces light scatter following surgery.<sup>36</sup>

Two other disadvantages of hydrophobic acrylic IOLs are more frequent dysphotopsias related to a low anterior curvature and a high refractive index and the development of glistenings: microvacuoles within the IOL material may occur when the IOL is in an aqueous environment and water fills microscopic openings within the material. Typical for acrylic IOLs, glistenings appear as white sparkling areas all over the IOL optic, which may impair the optical quality.<sup>37</sup> A higher density of the acrylic polymer network prevents the formation of microvacuoles and provide better visual

outcomes.<sup>38</sup> Glistening formation with AcrySof IOLs is a well-known phenomenon<sup>39</sup> and is consistent with our study results, where 92.8% of eyes with an AcrySof IOL developed glistenings. Newer hydrophobic acrylic materials, like that of the Vivinex XY1 IOL, should overcome that problem. In vitro studies have shown that the Vivinex XY1 IOL exhibited significantly less glistening formation than the AcrySof SN60WF IOL, which is consistent with our in vivo study results (G Auffahrt, Evaluation of in vitro glistening formation in different hydrophobic acrylic intraocular lenses, XXXIV ESCRS 2016, Copenhagen).

PCO grades at 3 years were generally low with both IOLs. The associated contrast sensitivity loss often still goes undetected by the patient and high-contrast visual acuity often remains unaffected. Still, biomicroscopy may still suggest YAG laser capsulotomy. This explains the discrepancy of PCO and YAG capsulotomy rates between

the IOLs, although not mirrored by differences in visual complaints or visual acuity.

In conclusion, this is the first long-term prospective randomized controlled study with the new hydrophobic acrylic Vivinex XY1 IOL. We could show significantly lower PCO and also lower YAG rates compared to the AcrySof SN60WF IOL that exhibited one of the lowest reported PCO and YAG rates until now. While in vitro findings often deviate from “real-life” clinical performance, we could confirm that the Vivinex XY1 IOL demonstrates an excellent PCO-inhibiting performance when implanted in humans.

The interaction of various factors such as a hydrophobic material, a smooth and chemically modified optic surface, and sharp posterior optic edge are the major keys for PCO prevention.

---

FUNDING/SUPPORT: THIS RESEARCH DID NOT RECEIVE ANY SPECIFIC GRANT FROM FUNDING AGENCIES IN THE PUBLIC, COMMERCIAL, OR NOT-FOR-PROFIT SECTORS. Financial Disclosures: None of the authors have financial disclosures. All authors attest that they meet the current ICMJE criteria for authorship.

---

## REFERENCES

- Schaumberg DA, Dana MR, Christen WG, Glynn RJ. A systematic overview of the incidence of posterior capsule opacification. *Ophthalmology* 1998;105(7):1213–1221.
- Kappelhof JP, Vrensen GF. The pathology of after-cataract. A minireview. *Acta Ophthalmol Suppl* 1992;(205):13–24.
- Findl O, Buehl W, Bauer P, Sycha T. Interventions for preventing posterior capsule opacification. *Cochrane Database Syst Rev* 2010;(2):CD003738.
- Javitt JC, Tielsch JM, Canner JK, Kolb MM, Sommer A, Steinberg EP. National outcomes of cataract extraction. Increased risk of retinal complications associated with Nd:YAG laser capsulotomy. The Cataract Patient Outcomes Research Team. *Ophthalmology* 1992;99(10):1487–1497. discussion 1497-1488.
- Bhargava R, Kumar P, Phogat H, Chaudhary KP. Neodymium-yttrium aluminium garnet laser capsulotomy energy levels for posterior capsule opacification. *J Ophthalmic Vis Res* 2015; 10(1):37–42.
- Lord SR, Clark RD, Webster IW. Visual acuity and contrast sensitivity in relation to falls in an elderly population. *Age Ageing* 1991;20(3):175–181.
- Market Scope. 2018 IOL Report: A Global Market Analysis for 2017 to 2023 2018. St. Louis, MO: Market Scope, <https://www.market-scope.com>. Accessed January 28, 2020.
- Christiansen G, Durcan FJ, Olson RJ, Christiansen K. Glistenings in the AcrySof intraocular lens: pilot study. *J Cataract Refract Surg* 2001;27(5):728–733.
- Buehl W, Findl O, Menapace R, et al. Reproducibility of standardized retroillumination photography for quantification of posterior capsule opacification. *J Cataract Refract Surg* 2002; 28(2):265–270.
- Findl O, Buehl W, Menapace R, et al. Comparison of 4 methods for quantifying posterior capsule opacification. *J Cataract Refract Surg* 2003;29(1):106–111.
- Ursell PG, Spalton DJ, Pande MV, et al. Relationship between intraocular lens biomaterials and posterior capsule opacification. *J Cataract Refract Surg* 1998;24(3):352–360.
- Hollick EJ, Spalton DJ, Ursell PG, et al. The effect of polymethylmethacrylate, silicone, and polyacrylic intraocular lenses on posterior capsular opacification 3 years after cataract surgery. *Ophthalmology* 1999;106(1):49–54. discussion 54-55.
- Hayashi H, Hayashi K, Nakao F, Hayashi F. Quantitative comparison of posterior capsule opacification after polymethylmethacrylate, silicone, and soft acrylic intraocular lens implantation. *Arch Ophthalmol* 1998;116(12):1579–1582.
- Sundelin K, Friberg-Riad Y, Ostberg A, Sjostrand J. Posterior capsule opacification with AcrySof and poly(methyl methacrylate) intraocular lenses. Comparative study with a 3-year follow-up. *J Cataract Refract Surg* 2001;27(10):1586–1590.
- Buehl W, Findl O, Menapace R, et al. Effect of an acrylic intraocular lens with a sharp posterior optic edge on posterior capsule opacification. *J Cataract Refract Surg* 2002;28(7):1105–1111.
- Buehl W, Findl O, Menapace R, et al. Long-term effect of optic edge design in an acrylic intraocular lens on posterior capsule opacification. *J Cataract Refract Surg* 2005;31(5): 954–961.
- Buehl W, Menapace R, Findl O, Neumayer T, Bolz M, Prinz A. Long-term effect of optic edge design in a silicone intraocular lens on posterior capsule opacification. *Am J Ophthalmol* 2007;143(6):913–919.
- Buehl W, Menapace R, Sacu S, et al. Effect of a silicone intraocular lens with a sharp posterior optic edge on posterior capsule opacification. *J Cataract Refract Surg* 2004;30(8): 1661–1667.

19. Buehl W, Findl O. Effect of intraocular lens design on posterior capsule opacification. *J Cataract Refract Surg* 2008;34(11):1976–1985.
20. Tetz M, Wildeck A. Evaluating and defining the sharpness of intraocular lenses: part 1: Influence of optic design on the growth of the lens epithelial cells in vitro. *J Cataract Refract Surg* 2005;31(11):2172–2179.
21. Peng Q, Visessook N, Apple DJ, et al. Surgical prevention of posterior capsule opacification. Part 3: intraocular lens optic barrier effect as a second line of defense. *J Cataract Refract Surg* 2000;26(2):198–213.
22. Nishi O, Nishi K. Preventing posterior capsule opacification by creating a discontinuous sharp bend in the capsule. *J Cataract Refract Surg* 1999;25(4):521–526.
23. Nishi O, Yamamoto N, Nishi K, Nishi Y. Contact inhibition of migrating lens epithelial cells at the capsular bend created by a sharp-edged intraocular lens after cataract surgery. *J Cataract Refract Surg* 2007;33(6):1065–1070.
24. Boyce JF, Bhermi GS, Spalton DJ, El-Osta AR. Mathematical modeling of the forces between an intraocular lens and the capsule. *J Cataract Refract Surg* 2002;28(10):1853–1859.
25. Nanavaty MA, Zukaite I, Salvage J. Edge profile of commercially available square-edged intraocular lenses: Part 2. *J Cataract Refract Surg* 2019;45(6):847–853.
26. Nanavaty MA, Spalton DJ, Boyce J, Brain A, Marshall J. Edge profile of commercially available square-edged intraocular lenses. *J Cataract Refract Surg* 2008;34(4):677–686.
27. Menapace R, Schriefl S, Lwowski C, Leydolt C. Impact of primary posterior capsulorhexis on regeneratory after-cataract and YAG laser rates with an acrylic micro-incision intraocular lens with plate haptics: 1-year and 3-year results. *Acta Ophthalmol* 2019;97(8):e1130–e1135.
28. Leydolt C, Davidovic S, Sacu S, et al. Long-term effect of 1-piece and 3-piece hydrophobic acrylic intraocular lens on posterior capsule opacification: a randomized trial. *Ophthalmology* 2007;114(9):1663–1669.
29. McDonald MB, Davidorf J, Maloney RK, Manche EE, Hersh P. Conductive keratoplasty for the correction of low to moderate hyperopia: 1-year results on the first 54 eyes. *Ophthalmology* 2002;109(4):637–649. discussion 649–650.
30. McDonald MB, Hersh PS, Manche EE, et al. Conductive keratoplasty for the correction of low to moderate hyperopia: U.S. clinical trial 1-year results on 355 eyes. *Ophthalmology* 2002;109(11):1978–1989. discussion 1989–1990.
31. Linnola RJ. Sandwich theory: bioactivity-based explanation for posterior capsule opacification. *J Cataract Refract Surg* 1997;23(10):1539–1542.
32. Menapace R, Saika S, Werner L. Effect of anterior capsule polishing on capsule opacification and YAG laser capsulotomy. In: Lovicu FJ, ed. *Lens Epithelium and Posterior Capsule Opacification*. Tokyo: Springer; 2014:253–278.
33. Tanaka T, Shigeta M, Yamakawa N, Usui M. Cell adhesion to acrylic intraocular lens associated with lens surface properties. *J Cataract Refract Surg* 2005;31(8):1648–1651.
34. De Giacinto C, Porrelli D, Turco G, Pastore MR, D'Aloisio R, Tognetto D. Surface properties of commercially available hydrophobic acrylic intraocular lenses: comparative study. *J Cataract Refract Surg* 2019;45(9):1330–1334.
35. Matsushima H, Iwamoto H, Mukai K, Obara Y. Active oxygen processing for acrylic intraocular lenses to prevent posterior capsule opacification. *J Cataract Refract Surg* 2006;32(6):1035–1040.
36. Eldred JA, Zheng J, Chen S, Wormstone IM. An in vitro human lens capsular bag model adopting a graded culture regime to assess putative impact of IOLs on PCO formation. *Invest Ophthalmol Vis Sci* 2019;60(1):113–122.
37. Labuz G, Reus NJ, van den Berg T. Light scattering levels from intraocular lenses extracted from donor eyes. *J Cataract Refract Surg* 2017;43(9):1207–1212.
38. Tognetto D, Toto L, Sanguinetti G, Ravalico G. Glistenings in foldable intraocular lenses. *J Cataract Refract Surg* 2002;28(7):1211–1216.
39. Waite A, Faulkner N, Olson RJ. Glistenings in the single-piece, hydrophobic, acrylic intraocular lenses. *Am J Ophthalmol* 2007;144(1):143–144.